



Research Journal of Pharmaceutical, Biological and Chemical Sciences

Evaluation of hepatoprotective activity of extracts of *Coscinium fenestratum* roots and *Embeliaribes* Burms. flower in animal models of hepatotoxicity: A biochemical and histological assessment

Basavaraj H^{*1}, Purnima Ashok², Prasanna GS²

¹Government College of Pharmacy, Bangalore.

²KLE University's College of Pharmacy, Bangalore.

ABSTRACT

Aqueous and ethanolic extract of roots of *Coscinium fenestratum* and flowers of *Embeliaribes* Burms. were investigated for its possible hepatoprotective property in paracetamol and carbon tetrachloride induced hepatotoxicity in laboratory animals, in view of paucity of such studies, despite proven secondary metabolites with promising antioxidant property. Hepatotoxicity was induced in albino Wistar rats by p.o and i.p administration of paracetamol (1gm /kg) once for seven days and 20% carbon tetrachloride (1ml /kg), two doses, at 72 hours, when groups of animals were treated with extracts in the dose of 200 and 400 mg/kg b.w. Liver function was assessed in groups of animals treated with extracts (different doses), untreated group and Silymarin treated animals. Significant elevation of AST, ALT, ALP, total protein, bilirubin and LD in untreated group of animals (pathogenic control) and dose dependant significant reduction in these levels of enzymes is clearly suggestive of hepatoprotective property of extracts. When histopathological changes between pathogenic control and extracts treated groups were compared, liver samples in extract treated showed regeneration of hepatocytes, normalized fatty changes and necrosis reversed. Presence of multiple bioactive antioxidant molecules may be responsible for observed changes in biochemistry of liver and histopathology in extracts treated animals. Study confirms potential hepatoprotective activity of aqueous and ethanolic extract of roots of *Coscinium fenestratum* and flowers of *Embeliaribes* Burms.

Keywords: *Coscinium fenestratum* root and *Embeliaribes* flower extracts, Hepatoprotective effect, Paracetamol, Carbon tetrachloride

***Corresponding author:**

Email: basavarajhulkoti@gmail.com



INTRODUCTION

Herbal medicines derived from plant extracts are being increasingly utilized to treat a wide variety of clinical diseases, through relatively little knowledge about their mode of action is available. There is a growing interest in the pharmacological evaluation of various plants used in Indian traditional system of medicine [1]. *Coscinium fenestratum* is a critically endangered medicinal liana found in Western Ghats, India [2]. The plant is known as false Columba or tree turmeric in English [3]. Previous studies have reported that the stem extracts of this plant possess hepatoprotective[4], antioxidant[5], antibacterial[6], antidiabetic[7], and anti-malarial activities [8]. The root and stem from Indonesia are reported to contain berberine and jatrorrhizine as the major alkaloids, besides berberrubine, N, N-dimethylinilindcarpine, palmatine and thalifendine, sitosterol and stigmasterol[2]. *Embeliaribes* Burms. are shrubs, mostly climbing, rarely small trees, distributed in tropical and sub-tropical regions of the world[2]. It has been employed in India, since ancient times by the local tribes as anthelmintic and is administered as powder, usually with milk followed by purgative. Aqueous extracts of the fruits showed antibacterial [9], antitubercular[10], antioxidant[11], cardioprotective[12], antifungal[13], antidiabetic[14] and antitumor[15] properties in experimental animals. Previously isolated classes of constituents include Embelin, quercitol, christembine, a volatile oil and valangin [16]. Although several parts of these herbs have been evaluated and reported to possess significant pharmacological activities, parts chosen, namely roots of *Coscinium fenestratum* and flowers of *Embeliaribes* have not been assessed and reported. In view of this, the current study envisaged evaluating hepatoprotective property by assessing bio-marker enzyme levels and examining histopathological changes

MATERIALS AND METHODS

Plant Material

The *Coscinium fenestratum* roots and *Embeliaribes* Burm flowers were collected from Udupi, Karnataka and were identified and authenticated by Dr. Siddamallayya from Regional Research Institute (Ay.) Bangalore. It is stored in herbarium with reference no. RI/BNG/SMP/Drug Authentication/2007-08/699/700 for reference. The shade dried roots and flowers of about 500 g were subjected for size reduction to coarse powder. The powder was defatted with petroleum ether (60–80°C) and then extracted with 5 liters of 90% ethanol using Soxhlet apparatus. Mark was dried to remove last traces of solvent and was soaked in water for 72h, with occasional shaking. Both the ethanolic and aqueous extracts were concentrated under vacuum to get the residues. Aqueous extract of roots of *coscinium fenestratum* (CFRAE), ethanolic extract of roots of *Coscinium fenestratum* (CFREE), aqueous extract of flowers of *Embeliaribes* (ERFAE), and ethanolic extract of *Embeliaribes* flower (ERFEE) were stored in airtight container and stored in cool and dry place, till further examination.

Animals

Healthy, adult albino Wistar rats in the weight range of 200-250g were selected for study and acclimatized for a week prior to study. Animals were procured from licensed animal breeder and maintained in central animal facility of this institution. CPCSEA guidelines with respect to maintenance, transport and test procedure were followed. Test animals were maintained on commercial pelleted diet (M/S Amruth feeds, Mumbai) and water, *adlibitum*. IAEC of this institution approved the test protocol.

Experimental

Acute toxicity study

Acute oral toxicity of test extracts were assessed as suggested in OECD guidelines - (AOT 425) [17] using healthy, nulliporous, non-pregnant, female albino Wistar rats (250-300g).

Model 1: Paracetamol induced hepatotoxicity

Test animals were randomly assigned to eleven groups of six animals each (n=6). Group 1 received the vehicle (10 ml/kg, p.o.) and served as normal control. Group 2 received paracetamol 1g /kg, p.o) and group 3 received silymarin (50 mg/kg, p.o.). Groups 4 - 7 received CFRAE and CFREE at a dose of 200 and 400 mg/kg, p.o. respectively; group 8 and 11 received ERFAE and ERFEE at a dose of 200 and 400 mg/kg p.o., respectively for 7 days [18]. Biochemical parameters were determined in fasted animals after 18 hours of the last dose.

Model 2: Carbon tetra chloride induced liver fibrosis

Test animals were randomly assigned to eight groups of six animals each (n=6). Group 1 served as normal control and received distilled water (1 ml/kg, p.o.). Group 2 received carbon tetra chloride (1 ml/kg body weight i.p.). Group 3 was treated with the reference drug Silymarin (50 mg/kg, p.o.), respectively. Groups 4 and 5 were treated with CFRAE and CFREE at doses of 400 mg/ (kg, p.o.), respectively, groups 6 to 8 received 400 mg/kg, p.o of ERFAE, ERFEE 200 and 400 mg/kg, p.o respectively, for 7 days and carbon tetrachloride was administered after every 72 h [19]. Biochemical parameters were determined in fasted animals after 18 h of the last dose.

Assessment of liver function

Blood samples of the test animals were withdrawn from retro bulbar venous plexus under light anaesthesia and were kept at room temperature for 2 h, so that the process of coagulation gets completed. The blood samples were centrifuged and serum thus separated was used for the estimation of serum enzymes namely Alanine aminotransferase (ALT), Aspartate aminotransferase (AST), alkaline phosphatase (ALP), lactate dehydrogenase (LD) protein and serum bilirubin following instructions in the manual supplied with the commercial kit.

Histopathological examination of the liver

The liver of the experimental animals were fixed in 10 % formol-saline prior to routine processing in paraffin-embedded blocks. Sections (5 μ m thick) cut and stained using hematoxylin-eosin (HE) stain and observed for pathological changes and changes thereof due to treatment with increasing doses of extracts.

Statistical analysis

Results were expressed as Mean \pm SEM. The data were analyzed by Two-Way ANOVA followed by Bonferroni Multiple Comparison Test and $p < 0.05$ considered as statistical significant.

RESULTS

Phytochemical investigations

The extracts revealed the presence of various phytoconstituents, like alkaloids, flavonoids, tannins, phenolic compounds, non-reducing sugars, steroids, glycosides, sterols and triterpenes.

Acute toxicity

Neither mortality nor morbidity was observed in test animals within 24 hours, as well at the end of fourteen days of observations in the dose of 2000mg/kg, implying that the dose upto 2000mg/kg is safe and non-toxic.

Assessment of Liver Function

Effects of increasing doses of extracts on biochemical parameters assessed in two above chosen models are as shown in table 1 and 2. Paracetamol and carbon tetrachloride – the established hepatotoxicants significantly elevated enzyme levels compared to normal control animals treated with vehicle and extract treated animals revealed a dose dependent significant in enzyme level compared to untreated pathogenic control animals. Biochemical parameters did not significantly differed from Silymarin treated animals.

Histopathological studies

The histopathological studies of the liver showed fatty changes, swelling and necrosis with loss of hepatocytes in all hepatotoxicant treated rats in comparison with normal control. The extract treated groups showed regeneration of hepatocytes, normalization of fatty changes and necrosis of the liver.

Table: 1. Effect of *C. fenestratum* root and *E. ribes* flowers on serum enzyme levels in Paracetamol induced hepatic damage.

Treatment	ALT(U/L)	AST(U/L)	ALP(U/L)	TP (mg/dl)	TB (mg/dl)
Control	189.2± 20.90	75.4± 14.87	303.5± 31.87	0.6± 0.06	0.54± 0.03
Paracetamol 1g/Kg (Pathogenic Control)	297.85± 38.72	174.67± 11.55	415.86± 19.55	1.99± 0.08	1.43± 0.06
Silymarin (50mg/kg)	164.83±21.53 ^{***}	62.99±6.69 ^{***}	312.67±15.06 ^{***}	0.41±0.09 ^{***}	0.43±0.03 ^{***}
CFRAE(200mg/kg)	175.64±14.84 ^{**}	83.75±18.92 ^{**}	336.01±9.12 ^{**}	0.51±0.05 ^{***}	0.58±0.04 ^{**}
CFRAE(400mg/kg)	172.96±18.5 ^{**}	80.31±21.34 ^{**}	329.53±5.76 ^{**}	0.5±0.01 ^{**}	0.56±0.03 ^{**}
CFREE(200mg/kg)	173.79±17.49 ^{**}	75.05±12.65 ^{**}	321.34±9.56 ^{**}	0.47±0.03 ^{**}	0.54±0.07 ^{**}
CFREE (400mg/kg)	168.11±12.57 ^{***}	71.45±10.44 ^{***}	315.8±13.76 ^{***}	0.44±0.06 ^{***}	0.47±0.03 ^{***}
ERFAE (200mg/kg)	181.58±16.86 [*]	85.88±11.04 ^{**}	335.91±6.87 ^{**}	0.54±0.02 ^{**}	0.59±0.02 ^{**}
ERFAE (400mg/kg)	176.75±12.55 ^{**}	80.25±9.77 ^{***}	331.44±12.02 ^{***}	0.53±0.07 ^{***}	0.55±0.04 ^{***}
ERFEE (200mg/kg)	174.69±9.53 ^{***}	79.47±14.85 ^{***}	328.65±14.93 ^{***}	0.51±0.03 ^{***}	0.54±0.02 ^{***}
ERFEE (400mg/kg)	170.33±14.79 ^{***}	73.33±9.98 ^{***}	320.57±10.32 ^{***}	0.48±0.02 ^{***}	0.51±0.06 ^{***}

All values are mean ± S.E.M n=6, ^{***} $p < 0.001$, ^{**} $p < 0.01$, and $p < 0.05$ Vs Pathogenic control group.

Table: 2. Effect of *C. fenestratum* root and *E. ribes* flowers on serum enzyme levels in CCl₄ induced liver fibrosis

Treatment	ALT(U/L)	AST(U/L)	ALP(U/L)	LDH(U/L)	TP (mg/dl)	TB (mg/dl)
Control	162.54±11.27	78.29± 9.77	159.92± 6.73	167.54±4.79	8.49± 0.07	0.59± 0.02
Pathogenic Control	264.32±8.06	255.71±7.59	280.53±6.66	276.63±7.97	2.18± 0.09	1.75± 0.03
Silymarin(50mg/kg)	205.29±8.22 ^{***}	90.82±10.58 ^{***}	165.56±7.61 ^{***}	180.74±8.24 ^{***}	6.56±0.06 ^{***}	0.22±0.05 ^{***}
CFRAE(400mg/kg)	210.43±10.65 ^{**}	127.10±9.57 [*]	190.56±4.65	179.74±5.69	4.85±0.06	0.10±0.04
CFREE (400mg/kg)	190.88±11.52 ^{***}	89.16±6.78 ^{***}	190.47±4.64 ^{***}	195.24±6.39 ^{***}	6.12±0.06 ^{***}	0.26±0.04 ^{***}
ERFAE (200mg/kg)	220±9.36 [*]	115.47±7.35 [*]	198.52±9.37 [*]	198.63±6.73 [*]	7.81±0.06 [*]	0.15±0.04 [*]
ERFEE (200mg/kg)	198.88±11.05 ^{**}	92.00±5.86 ^{**}	180.55±14.11 ^{**}	193.50±8.15 ^{**}	6.04±0.07 ^{**}	0.25±0.03 ^{**}
ERFEE (400mg/kg)	180.48±8.33 ^{***}	107.10±6.66 ^{***}	167.56±10.01 ^{***}	174.72±7.45 ^{***}	4.75±0.04 ^{***}	0.22±0.11 ^{***}

Values are mean ± S.E.M n=6, ^{***} $p < 0.001$, ^{**} $p < 0.01$, and $p < 0.05$ Vs Pathogenic control group

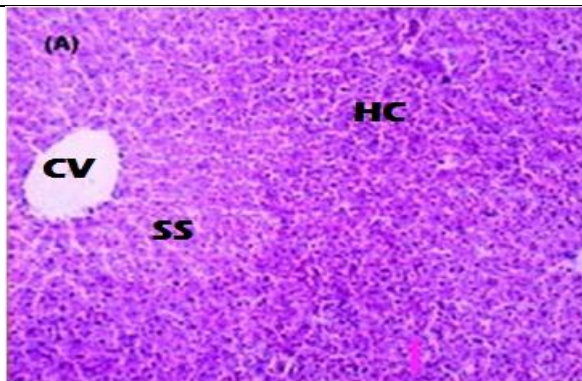
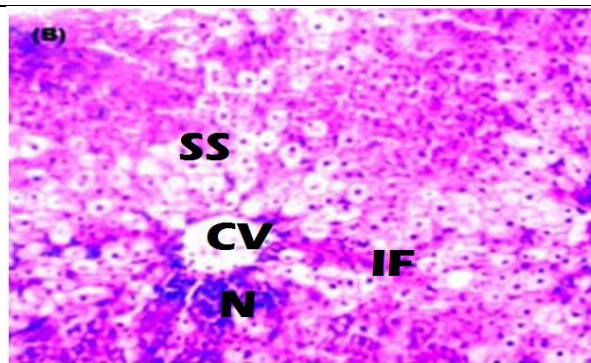


Fig (1A): CV: Central vein, HC: hepatocytes, SS: sinusoidal spaces.

Section of liver of control group of animal showing the normal histological structure of the hepatocytes in the hepatic cords with central veins.



Fig(1B): N:Necrosis, SS: Sinusoidal spaces, CV: Central vein, HC: hepatocytes, IF: Infiltration

Section of liver of test animal administrated with paracetamol showing degeneration in the hepatocytes with mononuclear leucocytic inflammatory cells surrounding the central vein as well as in focal manner between the hepatocytes.

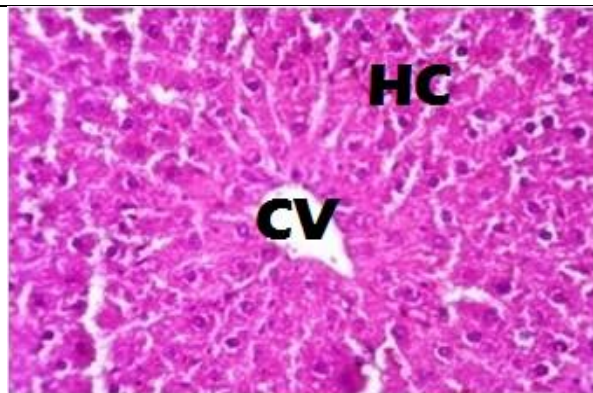


Fig (1C): CV: Central vein, HC: hepatocytes

Sections of liver protected by CFREE at a dose of 400mg/kg b.w showing moderate degeneration in the hepatocytes

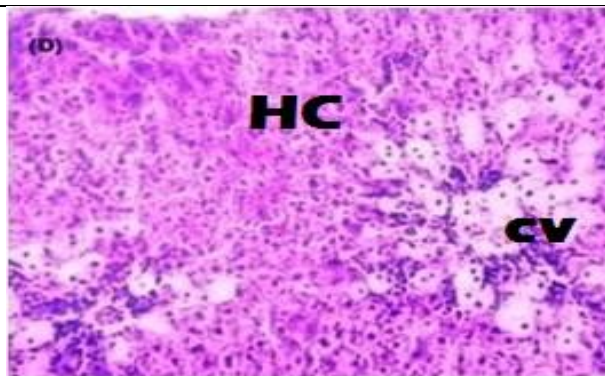
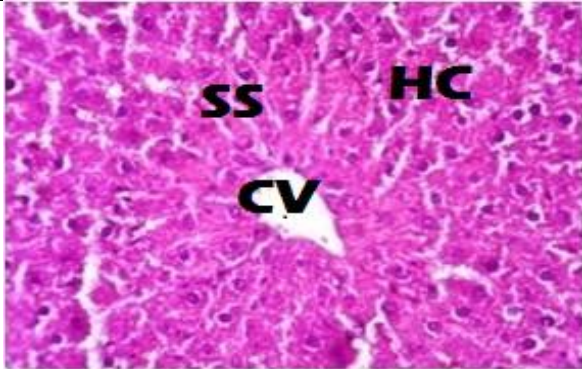
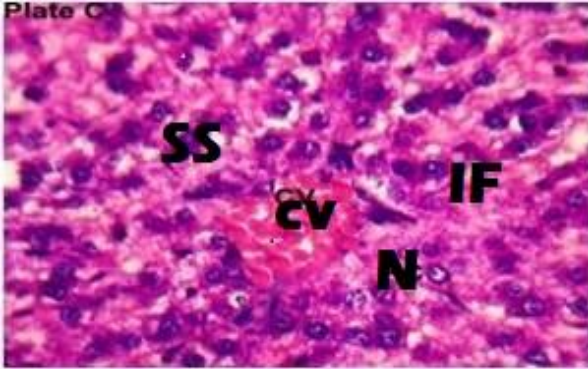
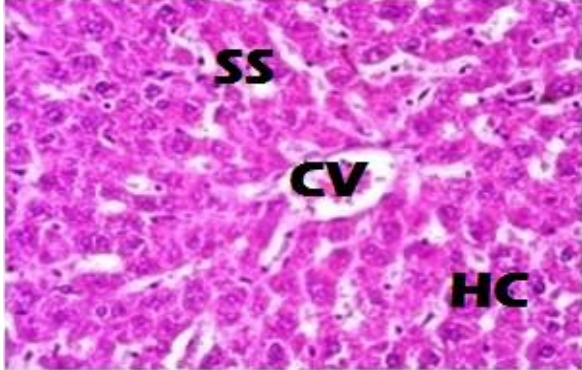
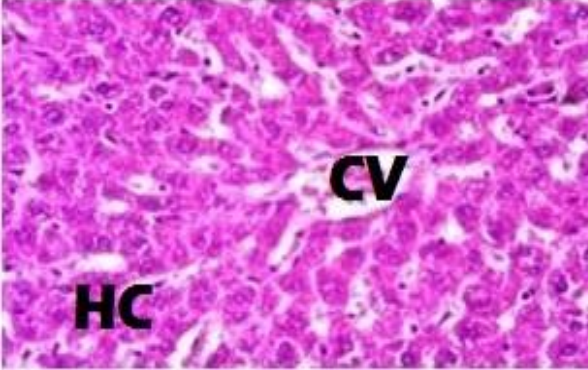


Fig (D): CV: Central vein, HC: hepatocytes

Sections of liver protected by ERFEE at a dose of 400mg/kg b.w also showing moderate degeneration in the hepatocytes

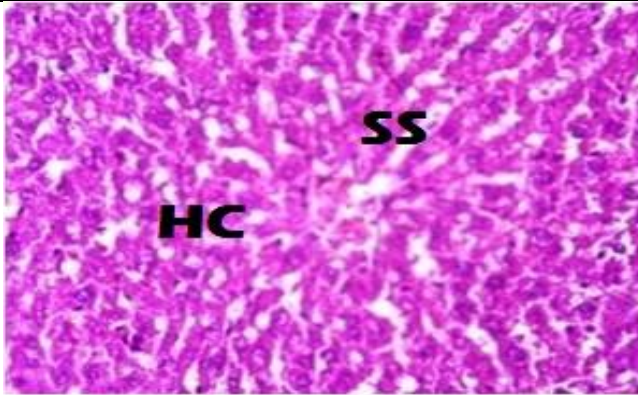
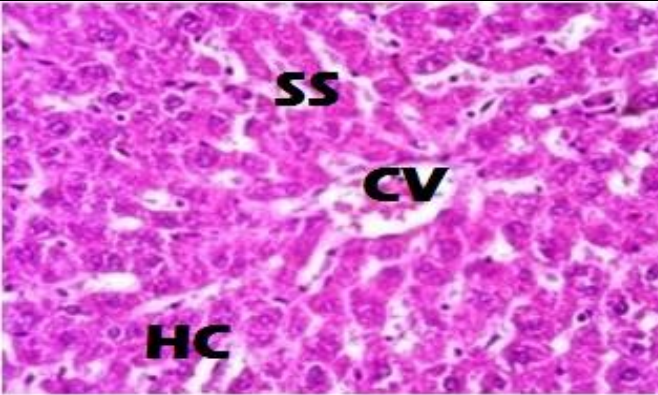
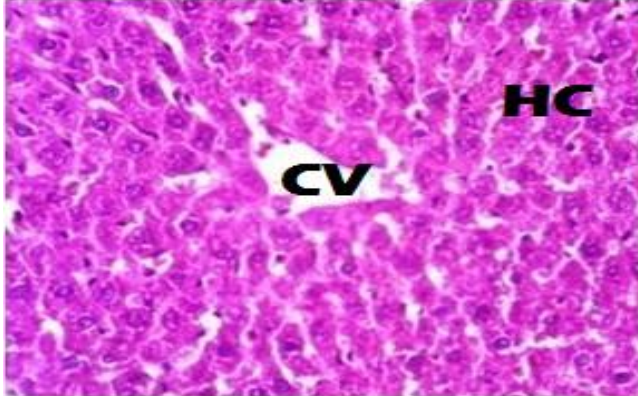
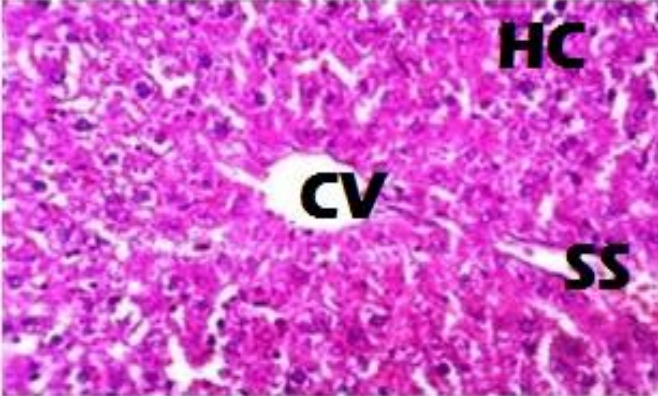
Sections of liver from paracetamol induced hepatotoxicity model.

Fig (1A): Section of Liver (H&E, 100 X) with normal histological features. Fig (1B): Section of liver of pathogenic control animal showing degeneration of hepatocytes. Fig (1 C) and (1D): Section of liver treated with CFREE (400 mg/kg) and ERFEE (400 mg/kg) showing moderate degeneration of hepatocytes.

	
<p>Fig (2A): CV: Central vein, HC: hepatocytes, SS: Sinusoidal spaces</p> <p>Section of liver of control group of animal showing the normal histological structure of the hepatocytes in the hepatic cords with central veins.</p>	<p>Fig (2B): N:Necrosis, SS: Sinusoidal spaces, CV: Central vein, HC: hepatocytes, IF: Infiltration</p> <p>Section of liver of test animal administrated paracetamol showing degeneration in the hepatocytes with mononuclear leucocytic inflammatory cells surrounding the central vein as well as in focal manner between the hepatocytes.</p>
	
<p>Fig (2C): CV: Central vein, HC: hepatocytes, IF: Infiltration</p> <p>Sections of Liver protected by CFREE dose of 400mg/ kg b.w showing moderate degeneration in the hepatocytes</p>	<p>Fig (2D): CV: Central vein, HC: hepatocytes, IF: Infiltration</p> <p>Sections of Liver protected by CFRAE at a dose of 400mg/ kg b.w showed reduction in fatty changes, necrosis, and hydropic changes.</p>

Sections of Liver from carbon tetrachloride induced hepatotoxicity model.

Fig (2A): Section of normal Liver (100X) with normal histological features. Fig (2 B): Section of liver of pathogenic control animal showing degeneration of hepatocytes. Fig (2 C): and (2D): Section of liver treated with CFREE (400 mg/kg) and ERFEE (400 mg/kg) showing moderate degeneration of hepatocytes and reduced fatty changes.

	
<p>Fig (2E): HC: hepatocytes, SS: Sinusoidal spaces</p> <p>Sections of Liver protected by ERFAE at a dose of 200mg/ kg b.w showing moderate degeneration in the hepatocytes</p>	<p>Fig (2F): : Sinusoidal spaces, CV: Central vein, HC: hepatocytes.</p> <p>Sections of Liver protected by ERFAE at a dose of 200mg/ kg b.w showed reduction in fatty changes, necrosis, and hydropic changes.</p>
	
<p>Fig (2G): CV: Central vein, HC: hepatocytes.</p> <p>Sections of liver protected by ERFEE at a dose of 200mg/ kg b.w also showed moderate degeneration in the hepatocytes</p>	<p>Fig (2H): CV: Central vein, HC: hepatocytes.</p> <p>Sections of liver protected by ERFEE dose of 400mg/ kg b.w showed few foci of necrosis of hepatocytes and fatty changes and signs of more regenerative activity</p>

Sections of Liver from CCl₄ Induced hepatotoxicity model.

Fig (2 E & F): Section of liver showing protection by ERFAE (200 and 400 mg/kg) with only moderate degeneration of hepatocytes. Fig 2 (G & H); Section of liver showing protection by ERFEE (200 and 400 mg /kg) with more regenerative changes.



DISCUSSION

In ongoing investigations in our laboratory on aqueous and ethanolic extract of roots and flowers of *Coscinium fenestratum* and *Embeliaribes* Burms. which identified *in-vitro* antioxidant activity (unpublished data) promoted this investigation. The protective role of secondary metabolites in pathological conditions is well known, established and suggested as an ideal alternative to currently available synthetic drugs. Paracetamol induced hepatotoxicity and carbon tetrachloride induced fibrosis were chosen for the study and study involved assessing the biochemical changes, as well the histopathological changes due to increasing concentration (200 and 400 mg/kg - dose that is 1/10 and 1/5 of 2000mg/kg) of extracts.

Experimental protocol involved daily administration of extracts and administration of these hepatotoxicants at specified interval of time. A pathogenic control group of test animals helped to get a complete biochemical and histopathological profile and comparison was made between profiles of extracts treated group of animals, vehicle treated and untreated pathogenic control group of animals.

Biochemical profiles selected for assessment of possible protective role of the extracts were appropriate - the determination of enzyme levels such as AST and ALT is largely used. Necrosis or membrane damage releases the enzyme into circulation; therefore, it can be measured in serum. High levels of AST indicate liver damage, such as that due to viral hepatitis as well as cardiac infarction and muscle injury. ALT catalyses the conversion of alanine to pyruvate and glutamate, and is released in a similar manner. Therefore, ALT is more specific to the liver, and is thus a better parameter for detecting liver injury [20]. Paracetamol and carbon tetra chloride-induced hepatotoxicity in the rats demonstrated that CFRAE, CFREE, ERFAE and ERFREE at different doses caused significant inhibition of ALT and AST levels. Serum ALP and bilirubin levels on the other hand, are related to the function of hepatic cell. Increase in serum level of ALP is due to increased synthesis, in presence of increasing biliary pressure [21] and all test compounds at different doses caused significant inhibition of bilirubin levels. Effective control of bilirubin level and alkaline phosphatase activity points towards an early improvement in the secretory mechanism of the hepatic cell [1].

Histopathological assessment of section of liver of various groups of animals revealed an interesting change. Section of liver of untreated animals, in both paracetamol and carbon tetrachloride models revealed degeneration of hepatocytes, fatty changes, on the contrary, extract treated in two doses revealed moderate degeneration and reduced fatty changes, section also revealed (in extract treated) more regenerative changes from degenerative changes.

When biochemical alteration in enzymes level and histopathological changes are viewed in the perspective of damages that paracetamol and carbon tetrachloride could produce, extracts are indeed protective in nature, in the sense that, extracts reversed the potential histopathological changes.

Such significant changes points to protective role of extracts to the liver damage caused by paracetamol and carbon tetrachloride under evaluation.

CONCLUSION

Ethanollic and aqueous extract of *Coscinium fenestratum* roots and *Embeliaribes* Burm. flower possesses significant hepatoprotective activity.

REFERENCES

- [1] Gupta M, Mazumder UK, Thangavel SK, Periyasamy G, Ramanathan SK. IJPT 2004; 3: 12-20.
- [2] The wealth of India. Vol-2, CSIR, Government of India, New Delhi 2001.
- [3] Venukumar MR, Latha MS. Indian J ExpBiol2004; 42(8): 792-797.
- [4] Venukumar MR, Latha MS. Indian J PhysiolPharmacol 2002; 46 (2): 223-228.
- [5] Nair GM, Narasimhan S, Shinburaj, Abraham TK. Fitoterpia 2005; 76: 585-587.
- [6] Annie S, Rajendran K, Punitha ISR. J Ethnopharmacol 2005; 97: 369- 374.
- [7] Quan Le Tran , Yasuhiro Tezuka, Jun-ya Udea, Nhan Trung Nguyen, Yukiko Maruhida yama, Khursida Begum, Hye- sook Kim et.al . J Ethnopharmacol 2003; 86: 249-252.
- [8] Chopra RN, Nayar SL, Chopra IC. In: Glossary of Indian medicinal plants (5th edition), National Institute of science Communication, CSIR, New Delhi 1999: p. 106.
- [9] Ravikumar KR, Ved CK. 100 red listed medicinal plants of conservation concern in South India. Bangalore FRLHT 2000.
- [10] Chopra RN, Chopra IC, Varma BS. Supplement to glossary of Indian medicinal plants. New Delhi: Publication and Information Directorate, CSIR, 1969. p. 27.
- [11] Chitra M, Sukumar E, Suja V, Shyamala Devi CS. Chemotherapy 1994;40:109.
- [12] Bhandari U, Ansari, MN, Islam F. Indian J ExptBiol2008; 46: 35-40.
- [13] Sharma PC, Yelne, MB and Dennis TJ. Database on medicinal plants used in Ayurveda. CCRAS 2002: 478-89.
- [14] Bhandari U, Kanojia R and Pillai KK. Int J Expt Diabet 2002; 3: 159-162.
- [15] Kirthikar KR and Basu BD. Indian Medicinal Plants, International Book Distributors, Dehradun, 1987; 2: p.1511.
- [16] Bheemasankara Rao CH, Venkateswarlu V. J Org Chem 1961; 26: 4529.
- [17] The Organization of Economic Co-operation Development (OECD), 2001b.
- [18] Manoj B, Aqueed K. Ind J Expt Biol2003; 41: 85-87.
- [19] Gupta M, Mazumder UK, Sambathkumar R. Nat Prod Sci 2003; 9: 186-191.
- [20] King J. The hydrolases-acid and alkaline Phospatase, Practical Clinical Enzymology, Van, D (ed.), London: Nostrand company Ltd; 1965. p. 191-208.
- [21] Malloy HJ, Evelyn KA. J Biol Chem1937; 119:481.