

Research Journal of Pharmaceutical, Biological and Chemical Sciences

Hepatoprotective Activity of *Cnidoscolus Chayamansa* against Rifampicin and Isoniazide Induced Toxicity in Wistar Rats

K Kulathuran Pillai^{*1}, N Chidambaranathan², M Mohamed Halith², S Jayaprakash²,
N Narayanan³

¹ Department of Biotechnology, Periyar Maniammai University, Vallam, Thanjavur, Tamil Nadu, India

² KM College of Pharmacy, Uthangudi, Madurai, Tamil Nadu, India.

³ Jaya college of pharmacy, Thiruninravur, Chennai-602024.

ABSTRACT

The purpose of this study was to assess the effect of ethanolic extract of *Cnidoscolus chayamansa* leaves in experimentally drug induced hepatitis in rats. Rats were divided into five different groups each having six. Group 1 served as a control, Group 2 received Rifampicin (RIF) (100 mg/kg, i.p.) and coadministered with Isoniazid (INH) (100 mg/kg, i.p.), in sterile water, group 4 and 5 served as extract treatment groups and received 200 & 400 mg/kg, orally, ethanolic extract of *Cnidoscolus chayamansa* and group 3 served as standard group and received Silymarin 2.5 mg/kg orally. All the treatment protocols followed 21 days and after which rats were sacrificed, blood and liver were taken for biochemical and histological studies, respectively. The Rifampicin (RIF) and Isoniazid INH treated group rats (G2) showed variable increase in serum AST, ALT, ALP, total protein and total bilirubin levels. Administration of ethanolic extracts of *Cnidoscolus chayamansa* significantly prevented Rifampicin-Isoniazid-induced elevation in the levels of serum diagnostic liver marker enzymes aspartate amino transferase (AST), alanine amino transferase (ALT) and alkaline phosphatase (ALP) level in experimental groups of rats. Moreover, total protein and total albumin levels were significantly increased in treatment groups. The effect of extract was compared with a standard drug, Silymarin. The changes in biochemical parameters were supported by histological profile. It is concluded that the ethanolic extract of *Cnidoscolus chayamansa* protects against rifampicin and Isoniazid-induced oxidative liver injury in rats.

Keywords: *Cnidoscolus chayamansa*; Rifampicin; Isoniazid; Hepatotoxicity; Oxidative stress.

***Corresponding author:**

Email: kkpillai_pillai@yahoo.co.in

INTRODUCTION

Isoniazid, although a highly effective drug in the treatment of tuberculosis, is well known for its hepatotoxicity [1]. The risk of severe hepatotoxicity caused by Isoniazid is approximately 1–2% of patients and 20% of patients are associated with liver enzyme elevations in plasma [2]. Despite the undefined mechanism of Isoniazid hepatotoxicity, hydrazine and acetyl hydrazine are regarded as the main toxic metabolites of Isoniazid [3, 4, 5, 6]. It is highly suggested that these two bioactive metabolites are produced by a series of enzymes including cytochrome P450 [2, 7, 8] and could induce oxidative stress to cause hepatotoxicity [6]. In particular, CYP 2E1 is reportedly involved in Isoniazid-induced hepatotoxicity in humans [9]. Animals [2, 10] microsomes [3,4] and HepG2 cells[11].

Since oxidative stress induced by CYP 2E1 was regarded as the major mechanism of Isoniazid hepatotoxicity, intracellular glutathione (GSH) enhancers and reactive oxygen species (ROS) scavengers were used as a potent anti-hepatotoxic drugs against Isoniazid toxicity. For example, ‘thiol’ compounds, such as *N*-acetylcysteine (NAC), effectively inhibited the Isoniazid hepatotoxicity in rat by supplying the intracellular GSH content [12]. Rifampicin (RIF), a powerful inducer of mixed-function oxidase, increases the hepatotoxicity of Isoniazid (INH) by enhancing the production of toxic metabolites from acetyl hydrazine [13, 14]. Rats show a similar genetically determined acetyl transferase activity as in humans and are more sensitive to Isoniazid (INH)-induced hepatotoxicity due to a high amidase activity, which results in release of large amount of acetyl hydrazine, which induces hepatotoxicity. Anti-tubercular drugs mediated oxidative damage is generally attributed to the formation of free radicals, which act as stimulator of lipid peroxidation and source for destruction and damage to the cell membrane [15]. Alterations of various cellular defense mechanisms consisting of enzymatic and non-enzymatic components have been reported in Rifampicin (RIF) and Isoniazid (INH) induced hepatotoxicity [16].

Since all the drugs used in the treatment of tuberculosis are shown to have hepatotoxic effects, studies have been performed to prevent or reduce the toxicity by the use of natural herbal drugs and/or synthetic compounds, without interfering with the therapeutic action of the drugs.

Garlic, Silymarin, *N*-acetylcysteine and several other herbal drugs are proved to have such effects. It is of importance to note that the inhibition of CYP450 2E1 and antioxidant actions seem to be the common mechanism of action of herbal drugs [17].

The tree spinach (*Cnidoscolus chayamansa* Mc Vaughn, Euphorbiaceae), called “Chaya” in south Texas, is popular in Mexico and central America and has been introduced into the United States (Mainly south Texas and Florida) and now presently available in and around southern part of India, for potential uses as a leafy vegetable and/ or as a medicinal plant.

The edible parts of Chaya plant which tastes like spinach when cooked, provide important nutritional sources for proteins, vitamins (A and C), minerals (Calcium, iron, phosphorus), niacin, riboflavin and thiamine among populations that cannot afford expensive

food rich in these nutrients [18]. Chaya traditionally has been recommended for a number of ailments including diabetes, obesity, kidney stones, hemorrhoids, acne and eye problems [19].

Chaya shoots and leaves have been used as a laxative, diuretic, circulation stimulant, to improve digestion, to stimulate lactation, and to harden the finger nails [20]. The leaves contain mineral constituents like K, Ca, Mg, Na, Fe, Mn, Zn, Cu; Flavonoids like Ametoflavone, Astragatin, Kaempferol-3O-Ruttinoside and Dihydromyricetin. Leaves also contain hydrocyanic glycosides, a toxic compound easily destroyed by cooking, even though some people tend to eat raw Chaya leaves, it is unwise to do so, while the nutritional value of Chaya has been demonstrated [21]. The present study was made to investigate the protective actions of ethanolic extract of leaves of *Cnidocolus chayamansa* Mc Vaughn (EECC) against hepatotoxicity caused by rifampicin-Isoniazid.

MATERIALS AND METHODS

Collection and authentication of plant

Fresh leaf of the plant *Cnidocolus chayamansa* Mc Vaughn were collected from southern districts of Tamil Nadu, India during the month of November. The plant material was taxonomically identified and authenticated by Dr. Chella Durai, Consultant, CCRAS Govt. of India (Rtd), Tirunelveli and the voucher specimens (KMCP/KKP/CC-0288) were retained in the Institute for future reference. The leaf of the plant *Cnidocolus chayamansa* Mc Vaughn were dried in the shade milled into coarse powder by a mechanical grinder and stored in closed vessel for further use.

Chemicals

Total albumin, Total protein, Aspartate transaminase (AST), Alanine Transaminase (ALT) AND Alkaline phosphatase (ALP) were assayed by using kits from Ranbaxy Diagnostic, New Delhi. All the drugs, chemicals and reagents used for biochemical estimation were purchased from Sigma-Aldrich, USA.

Animals

Male Wistar albino rats, weighing about 150 - 200 g were obtained from Institute Animal Center and used in the experiments. The protocol was approved by the Institute's Animal Ethical Committee.(Approval no. KKP/Ph.D/PMU/2011) Animals were kept in the animal house at an ambient temperature of 25°C and 45-55% relative humidity, with 12 h each of dark and light cycles. Animals were fed pellet diet and water *ad-libitum*.

Induction of experimental hepatotoxicity

Rifampicin and Isoniazid solution were prepared separately in sterile distilled water. Rats were treated with Isoniazid (100 mg/kg, orally) and co-administered with rifampicin (100 mg/kg, orally) for 21 days [10, 22]. In order to study the effect of ethanolic extract of

Cnidocolus chayamansa (EECC) in rats, 200 and 400 mg/kg, orally were used. Silymarin (2.5 mg/kg orally.) was used as a standard drug in this study [23].

Treatment Protocol

Rats were divided into five groups each having six animals.

- | | |
|---------------|---|
| Group1 | Served as normal control group received 10ml/kg normal saline. |
| Group2 | Served as toxic control group received Rifampicin and Isoniazid 100mg/kg administered orally. |
| Group3 | Served as standard group received Silymarin 2.5 mg/kg administered orally. |
| Group4 | Served as extract (EECC) treatment groups received 200 mg/kg administered orally. |
| Group5 | Served as extract (EECC) treatment groups received 400 mg/kg administered orally. |

Weights of these rats were monitored sequentially in control and experimental animals for a period of 21 days.

Biochemical estimation

Rats were sacrificed 1 h after administration of drug on day 21. The blood was collected by retro-orbital artery puncture. Blood samples were centrifuged for 10 min at 3000 rpm to separate the serum. AST, ALT, ALP, Total Protein and albumin levels were estimated from the serum by using standard kits [24].

Histopathological studies

The liver was excised quickly and fixed in 10% formalin and stained with Hematoxylin and eosin and then observed under microscope for degeneration, fatty changes or necrotic changes as evidence of hepatotoxicity.

Statistical analysis

The results are expressed as mean \pm SEM. The evaluation of the data was done using one way ANOVA followed by Newman – Keul's multiple range tests. Difference below $p < 0.05$ implied significance.

RESULTS

Table 1 EFFECT OF EECC ON SERUM ENZYMES

GROUPS	TOTAL PROTEIN (g/dl)	TOTAL ALBUMIN (g/dl)	AST (u/l)	ALT (u/l)	ALP (u/l)
G1	8.14±0.47	4.91±0.35	145.07±6.40	75.38±4.50	120.39±7.02
G2	4.24±0.20*a	2.12±0.22*a	254.23±8.69*a	176.14±5.88*a	307.59±6.49*a
G3	7.84±0.75*b	4.54±0.34*b	175.08±6.53*b	83.03±6.82*b	203.96±9.42*b
G4	6.79±0.35*b	3.95±0.33*b	210.09±7.39*b	123.03±6.01*b	264.77±7.03*b
G5	7.40±0.45*b	4.28±0.37*b	196.16±9.41*b	103.61±5.70*b	258.89±10.75*b

All values are expressed as Mean ± SEM (n=6).

- Values are expressed as Mean ± SEM.
- Values were found out by using ONE WAY ANOVA followed by Newman Keul's multiple range tests.
- * (a) values were significantly different from normal control at p<0.01.
- * (b) Values were significantly different from toxic control at p<0.01.

Effect of *Cnidocolus chayamansa* on the serum AST levels

Results showed a significantly increased (p<0.01) level of serum AST in rats of G2 as compared to G1 (control) due to Rifampicin (RIF) and Isoniazid (INH), but these levels were significantly reduced (p<0.01) in rats of G3, G4 and G5 treated with Silymarin and *Cnidocolus chayamansa* at a dose of 200 and 400mg/kg..

Effect of *Cnidocolus chayamansa* on the serum ALT levels

It is found a significantly increased (p<0.01) level of serum ALT in rats of G2 as compared to G1 (control) due to Rifampicin (RIF) and Isoniazid (INH), but these levels were significantly reduced (p<0.01) in rats of G3, G4 and G5 treated with Silymarin and *Cnidocolus chayamansa* at a dose of 200 and 400mg/kg..

Effect of *Cnidocolus chayamansa* on the serum ALP levels

It is observed that Rifampicin (RIF) and Isoniazid (INH) caused significantly increased (p<0.01) level of serum ALP in rats of G2 as compared to G1 (control) due to Rifampicin (RIF) and Isoniazid (INH), but these levels were significantly reduced (p<0.01) in rats of G3, G4 and G5 treated with Silymarin and *Cnidocolus chayamansa* at a dose of 200 and 400mg/kg..

Effect of *Cnidocolus chayamansa* on the serum total protein and total albumin levels

The results showed that Rifampicin (RIF) and Isoniazid (INH) caused significantly decreased (p<0.05) level of serum total protein and total albumin in rats of G2 as compared to G1 (control) due to Rifampicin (RIF) and Isoniazid (INH), but these levels were significantly increased (p<0.01) in rats of G3, G4 and G5 treated with Silymarin and *Cnidocolus chayamansa* at a dose of 200 and 400mg/kg.

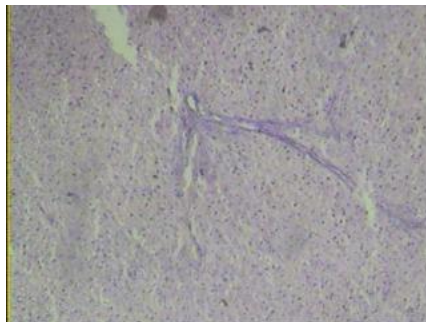


Figure 1: Normal Control (G1): Showed normal gross appearance having smooth surfaces, microscopically normal lobular appearance having normal central vein, radiating cords of hepatocyte and normal portal tract.

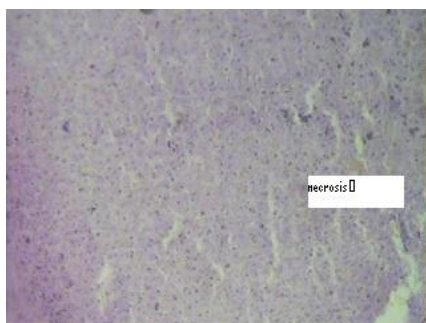


Figure 2: Toxic Control (G2): Showed moderate to severe liver damage characterized by clear cytoplasm, vascular congestion, fatty changes, apoptosis and focal areas of necrosis and vacuolation of cytoplasm as a feature of ballooning degeneration.

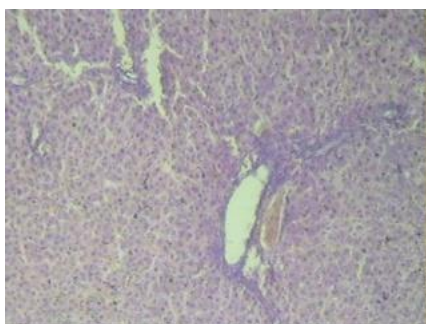


Figure 3: Standard Control (G3): Showed normal liver architecture and occasional inflammatory cells with no necrosis.

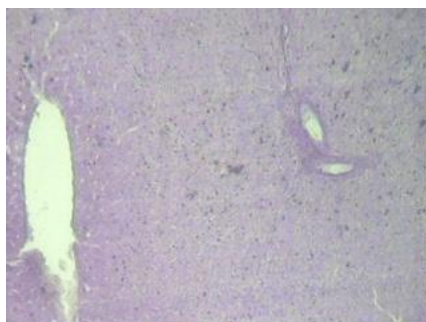


Figure 4: Treatment group (G4): Showed slight recovery and evidence of regeneration in some hepatocytes

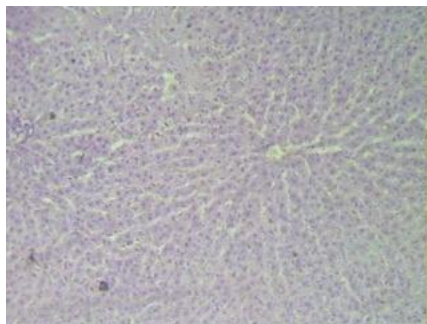


Figure 5: Treatment group (G5): Showed minimal necrosis, mild inflammation and less steatosis.

Histopathological examination

In histopathological studies of liver, the control G1 showed normal gross appearance i.e. dark maroon color of liver having smooth surfaces, microscopically normal lobular appearance having normal central vein, radiating cords of hepatocytes, normal portal tract in most of them (Figure 1). G2 rats that were given Rifampicin (RIF) and Isoniazid (INH), showed moderate to severe liver damage characterized by clear cytoplasm, vascular congestion, fatty changes, apoptosis and focal areas of necrosis and vacuolation of cytoplasm as a feature of ballooning degeneration (Figure 2). G3 Rats were given Rifampicin (RIF) and Isoniazid (INH) and Silymarin at a dose 25mg/kg showed normal liver architecture and occasional inflammatory cells with no traditis or necrosis (Figure 3). G4 Rats were given Rifampicin (RIF) and Isoniazid (INH) and low dose of *Cnidocolus chayamansa* extract (200 mg/kg) showed slight recovery and evidence of regeneration in some hepatocytes (Figure 4). G5 (Experimental 2) rats were given Rifampicin (RIF) and Isoniazid (INH) and high dose of *Cnidocolus chayamansa* extract (400 mg/kg) showed minimal necrosis, mild inflammation & less steatosis (Figure 5).

DISCUSSION

Rifampicin (RIF) and Isoniazid (INH) are the most important first line drugs, used for the treatment of tuberculosis. Isoniazid (INH) can cause hepatotoxicity in 20% of patients and is usually associated with an inflammatory response [25]. Rifampicin (RIF) and Isoniazid (INH) are reported to induce hepatotoxicity judged by elevated serum AST, ALT, ALP and total bilirubin levels, presence of focal hepatocytic necrosis and portal triaditis[26]. Plant-derived antioxidants such as Vitamin E, Vitamin C, polyphenol including phenolic acids, phenolic diterpenes, flavonoids, catechins, procyanidins, and anthocyanins are being increasingly suggested as important dietary factors. Supplementation with berry juice [27] flavones from skullcap, catechins from green tea, anthocyanins from chokeberry, and condensed tannins from faba beans[28] are indeed protective of oxidative stress indices in rats[29].

The protective action of antioxidants is usually due to the inhibition of free radical chain reaction and the resultant prevention of peroxidative deterioration of structural lipids in membranous organelles. Circulating antioxidants mainly vitamin C and vitamin E and tissue

enzymatic and non-enzymatic such as superoxide dismutase (SOD), catalase (CAT) and reduced glutathione (GSH) play important role in alleviating tissue damage due to the formation of free radicals [30]. In this study, we observed the hepatoprotective effect of *Cnidoscopus chayamansa* in Rifampicin (RIF) and Isoniazid (INH) induced hepatotoxicity in rats. A significant elevation was observed in the levels of serum AST, ALT, ALP and significant decrease level total protein and total albumin in G2 which received Rifampicin (RIF) and Isoniazid (INH) as compared to G1 rats who received normal saline.

Elevated levels of these parameters in serum are presumptive markers of hepatotoxic lesions in the liver. Co-administration of Silymarin and low & high dose of (200 & 400mg/kg) *Cnidoscopus chayamansa* ethanolic extract with INH and RIF Rifampicin (RIF) and Isoniazid (INH) in G3, G4 and G5, maintained the levels of AST, ALT, ALP, and serum total Protein and Total albumin towards normalcy as compared to G2 rats. This was most likely due to the anti oxidant effect of *Cnidoscopus chayamansa* constituents. The results are in accordance with some previous studies [31, 32]. On morphological examination in G4, low dose *Cnidoscopus chayamansa* showed partial recovery in some liver.

While in G5 high dose *Cnidoscopus chayamansa* showed a significant recovery towards normal, this result shows hepatoprotection after a both dose of *Cnidoscopus chayamansa* extract in experimentally drug induced hepatitis (DIH) in rats. The main constituents in *Cnidoscopus chayamansa* are K, Ca, Mg, Na, Fe, Mn, Zn, Cu, flavonoids like Ametoflavone, Astragatin, Kaempferol-3O-Ruttinoside and Dihydromyricetin. Leaves also contain hydrocyanic glycosides. Therefore, in this study Flavonoids in *Cnidoscopus chayamansa* might have a role in the recovery in Rifampicin (RIF) and Isoniazid (INH) induced hepatotoxicity in rats.

CONCLUSION

This study showed that EECC has a significant protective action against the hepatotoxicity induced by the drugs used in the treatment of tuberculosis. The hepatoprotective role of EECC might be due to its antioxidant potential mechanism suggesting that the extract of plant may be useful to prevent the oxidative stress induced damage. More research is required in this View-point to develop a good hepatoprotective drug from leaves of *Cnidoscopus chayamansa* Purification of extracts and identification of the active principle may yield active Hepatoprotective ingredients.

REFERENCES

- [1] Santhosh S, Sini TK, Anandan R, Mathew PT. Toxicology 2006; 219: 53–9.
- [2] Sarich TC, Adams SP, Petricca G, Wright JM. J Pharmacol Exp Ther 1999; 289: 695–702.
- [3] Nelson SD, Mitchell JR, Timbrell JA, Snodgrass WR, Corcoran III G.B. Science 1976; 193: 901–3.
- [4] Timbrell JA, Wright JM. Drug Metab Dispos 1979; 7: 237–240.
- [5] Delaney J, Timbrell JA. Xenobiotica 1995; 25: 1399–1410.

- [6] Walubo A, Smith P, Folb P.I. *Meth. Find. Exp Clin Pharmacol* 1998; 20: 649–655.
- [7] Girling DJ. *Tubercle* 1978; 59: 13–32.
- [8] Ono Y, Wu X, Noda A, Noda H, Yoshitani T. *Biol Pharm Bull* 1998; 21: 421–425.
- [9] Huang YS, Chern HD, Su WJ, Wu JC, Chang SC, Chiang CH, Chang FY, Lee SD. *Hepatology* 2003; 37: 924–930.
- [10] Yue J, Peng RX, Yang J, Kong R, Liu J. *Acta Pharmacol Sin* 2004; 25:699–704.
- [11] Nicod L, Viollon C, Regnier A, Jacqueson A, Richert L. *Hum Exp Toxicol* 1997;16:28-34.
- [12] Attri S, Rana SV, Vaiphei K, Sodhi CP, Katyal R, Goel RC, Nain C.K, Singh K. *Hum Exp Toxicol* 2000; 19: 517–52.
- [13] Ellard GA, Gammon PT. *J Pharmacokinat Biopharm* 1976; 4: 83-113.
- [14] Kalra BS, Aggarwal S, Khurana N, Gupta A. *Ind J Gastroenterol* 2007; 26: 18-21.
- [15] Georgieva N, Gadjeva V, Tolekova A. *Trakia J Sci* 2004; 2: 37–43.
- [16] Tasduq SA, Peerzada K, Koul S, Bhat R, Johri RK. *Hepatol Res* 2005; 31: 132–35.
- [17] Sude E, Fikriye U, Fikret. *Nutr Metab (Lond)* 2008; 5:18.
- [18] Yang YH. *Tropical food chemistry and nutrition*, Academic press, New York; 1979. Pp 417-436.
- [19] Diaz- Bolio J. *Tierra* 1975; 30: 407-408, 427-428.
- [20] Rowe L. *Plant guards: Secret of good health*. Valley Morning Star 1994; 4: A12.
- [21] Martin FW Ruberte R Chaya, *Cnidoscopus Chayamansa* includes composition and nutritional value, culture in Puerto Rico. In: *vegetables of hot humid tropics*. USDA, ARS. New Orleans, LA. 1978.
- [22] Saleem TSM, Christina AJM, Chidambaranathan N, Ravi V and Gauthaman KH. *Int J Appl Res Nat Pro* 2008; 1 (3): 1-7.
- [23] Parthasarathy R, Nivethetha M and Brindha P. *Ind Drugs* 2007; 44(5): 401-404.
- [24] Rajesh KG, Achyut NK, Geeta W, Murthy PS, Ramesh C and Vibha T. *Ann Nutr Metab* 2005; 49: 407-413.
- [25] Tafazoli S, Mashregi M, O'Brien PJ. *Toxicol Appl Pharmacol* 2008; 229(1): 94-101.
- [26] Pal R, Vaiphei K, Sikander A, Singh K, Rana S.V. *World J. Gastroenterol* 2006; 12: 636-639.
- [27] Netzel M, Strass G, Kaul C, Bitsch I., Dietrich H, Bitsch R. *Food Res Int* 2002; 35: 213-216.
- [28] Zdunczyk Z, Frejnajel S, Wroblewska M, Juskiwicz J, Oszmianski J, Estrella I. *Food Res Int* 2002; 35: 183-186.
- [29] Ramma AL, Bahorun T, Soobrattee MA, Aruoma OI. *J Agric Food Chem* 2002; 50(18): 5042-5047.
- [30] Rajagopal SK, Manickam P, Periyasamy V, Namasiviyam N. *J Nutr Biochem* 2003; 14: 452-458.
- [31] Pradeep K, Mohan CV, Gobianand K, Karthikeyan S. *Chem Biol Interact* 2007; 167: 8-12.
- [32] Pradeep K, Mohan CV, Gobianand K, Karthikeyan S. *Indian J Exp Biol* 2005; 43(6): 526-530.