

# Research Journal of Pharmaceutical, Biological and Chemical Sciences

## Lateral Pedicle Graft –Exquisite Finesse in Root Coverage – A Case Report.

RS Senthil Rajan, Krishna Kripal\*, MS Nalini, and Ipsita Jayanti.

Department of Periodontology, Rajarajeswari Dental College and Hospital, Ramohalli Cross, Mysore Road, Kumbalgodu Post, Bangalore 560060, Karnataka, India.

### ABSTRACT

Over the last few years, Periodontology has evolved in such a way that clinicians are required to treat disease and improve function, but also to cope with ever demanding esthetics of our patients. The different procedures or techniques involved in root coverage procedures are pedicle grafts, free gingival autografts and connective tissue grafts. Lateral pedicle grafts surgical technique provide complete root coverage with complete gain in attachment level and excellent post-operative colour and harmony with adjacent tissues. This case report presents the predictability of root coverage by using lateral pedicle grafts in narrow and shallow gingival recessions.

**Keywords:** Lateral pedicle graft, Gingival recession, root coverage, esthetics

*\*Corresponding author*

## INTRODUCTION

Periodontal plastic surgery is defined as any surgical procedure aimed at correcting deformities of the gingival or alveolar mucosa. Periodontal plastic surgery is the procedure for correcting gingival recession. Gingival recession is the apical shift of marginal gingiva exposing the root surface of the tooth. The two main causes that lead to gingival recession are plaque induced periodontal inflammation and trauma caused by faulty tooth brushing. [1] Other factors that will lead to gingival recession are tooth malposition, frenal and muscle attachment that encroach on the marginal gingival tissue and Orthodontic tooth movement. [2].

The main objective of treating denuded root surface is for esthetics and for treating hypersensitivity

Of several classifications on gingival recession, the one that is given by Dr. P.D. Miller (1983), has been used for the consideration of the anticipated root coverage. Defects classified as Miller's class I and class II can result in full coverage of the denuded root surface and class III and class IV provides partial coverage of the root. [3,4].

Factors effecting outcome of Periodontal Plastic Surgery: There are several factors that can affect the outcome of periodontal plastic surgery procedures.

Condition of the root surface – Presence of calculus, caries, contaminated cementum or restorations on root surface

- Prominent Frenal attachments
- Depth of vestibule
- Tissue type
- Dimension of recession defect and graft material
- Thickness of split thickness flap. [5,8]

Lateral pedicle graft is indicated in shallow and narrow (class I and class II) gingival recession with adequate amount and thickness of keratinized gingival recession area present on single tooth root.

### **Pedicle graft**

A pedicle graft is a mucogingival flap designed to serve as a soft tissue graft that maintains an intact blood supply from the donor site.

### **Lateral pedicle graft**

A rotated pedicle graft can be moved laterally while pivoting around a point. First technique was introduced in 1956 as the lateral sliding flap by Grupe and Warren: it was later renamed as laterally positioned flap. This technique uses the adjacent donor gingiva that has adequate keratinized tissue to cover the exposed root. [6] It consisted of the removal of the collar of gingiva lining the area of recession, then raising a full thickness flap on the adjacent tooth, which was then positioned laterally, and sutured over the denuded

root area. As the graft is tissue that is originally present at the buccal aspect of the tooth with the recession defect; an aesthetically pleasing result is obtained. [7]

#### Advantages of Lateral Pedicle Graft

- A single surgical site, no separate donor area
- Preservation of the blood supply of the pedicle flap covering the root surface.
- Color of the graft tissue is in harmony with that of the surrounding tissue

#### Case Report

A young male patient reported to the Department of Periodontology, who complained of “an elongated tooth” in the lower jaw. Patient had a non-contributory medical history. Examination revealed a localized grade II recession of the gingiva in relation to lower left canine (33) measuring 9mm by 3.5mm. IOPAR revealed no interdental bone loss.

#### Lateral Pedicle Flap Design

A V-shaped incision was made in the peripheral gingiva in the gingival recession area of tooth 33, with a #15 blade (Lister), while preserving sufficient interdental papilla on the distal aspect. It extended apically beyond the mucogingival junction. Wide external bevel incision on mesial aspect and an internal bevel incision on the distal aspect of the tooth with recession were given. Epithelium was removed around the exposed root surface.

#### Determining width of donor flap

Measuring the width of the recipient site next incision was made from the line angle of the tooth adjacent to donor tooth, and parallel to the first incision. The width of the donor flap was one and a half times that of the width of the recipient site. Determination of bone level at facial of donor site is done by sounding under L.A-ideally 1-2mm between bone and CEJ. Next incision extended perpendicular to and connected the first and third incisions. Flap reflection was full thickness to cover the area of recession, but split thickness over the papilla and over the facial of the donor tooth.

#### Transferring the graft

The tissue was rotated for a trial fit on the recipient tooth such that the base of the flap was as close as possible to the recipient tooth to enable minimum shortening of the flap. If the flap was strained a releasing or cutback incision was given at the base.

#### Graft Placement

The flap now lied passively in the desired position.

## Suturing the graft

The first suture was placed close to the mucogingival line on the leading edge of the flap with a fine needle and interrupted suture. Next the trailing edge was sutured on the papilla between the donor and recipient teeth. Additional sutures were placed to secure the leading edge to the prepared bed. Moistened gauze was held over the area for 5 minutes to enable a blood clot to form, and this assisted in stabilizing the area.

## Care of the surgical site

Tin foil was used to cover the donor area. Surgical area was covered with periodontal pack.

## Post-Surgical Follow up

The patient was instructed regarding post-operative care of the surgical site. He was advised not to brush on the surgical area and instructed to use chlorhexidine gluconate mouthwash of 0.12% twice daily. Patient was also kept on a course of antibiotics. Sutures were removed after ten days of surgery and on examination surgical site showed complete coverage of the root surface. Oral hygiene instructions were reinforced. Patient recalled after one month and two months of surgery (Fig. 8) and also after three months and six months of surgery (Fig. 9). And the surgical site showed complete coverage and the donor site healed completely. The pedicle graft taken up on the recipient site with excellent colour matching with the adjacent area. The pedicle graft after one month, two months, three months and six months showed no signs of inflammation and it was firm and attached to the root surface.

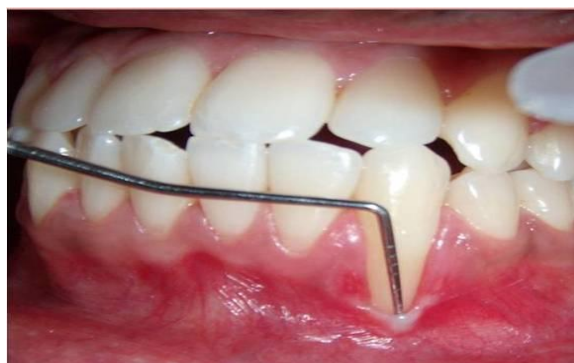

Figure 1: Mandibular Left Canine Showing Gingival Recession, Class II.

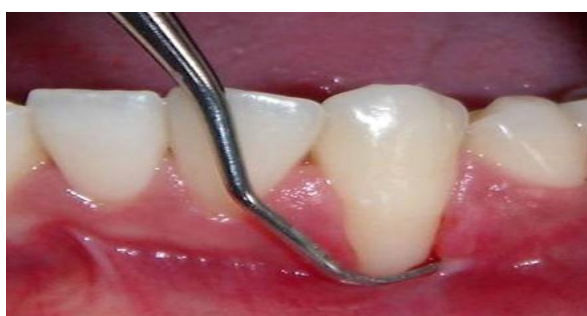

Figure 2: Gingival Recession after Oral Prophylaxis.

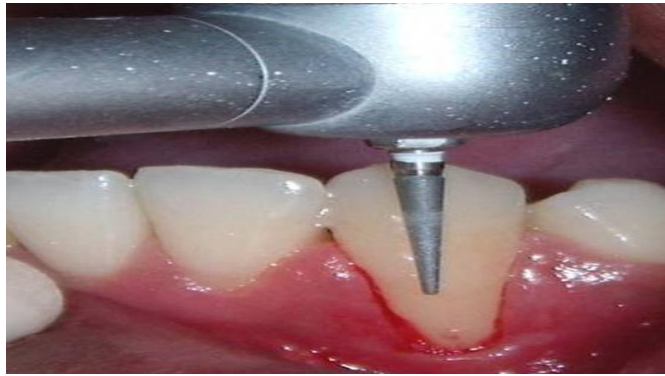


Figure 3: Gingival Recession after Odontoplasty.

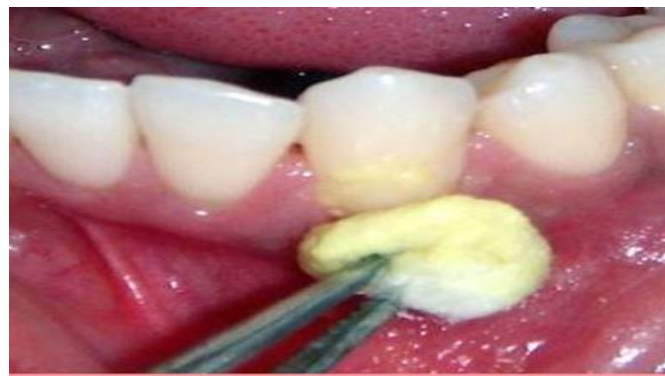

Figure 4: Root Conditioning With Tetracycline.

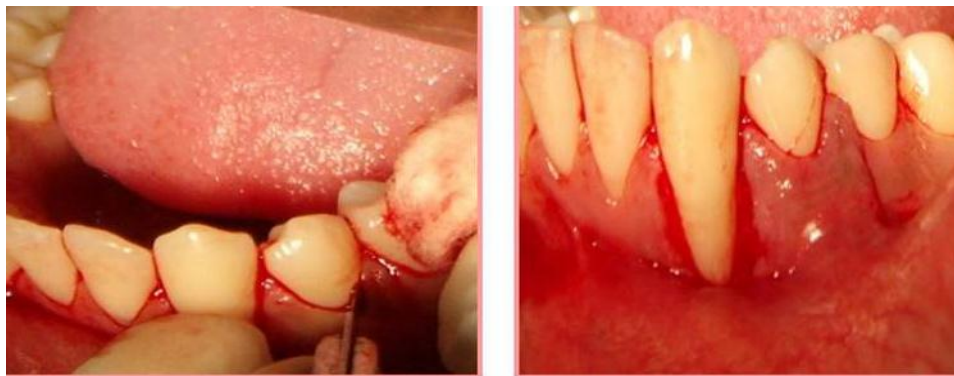

Figure 5: Lateral Pedicle Graft Taken From Adjacent Donor Site.

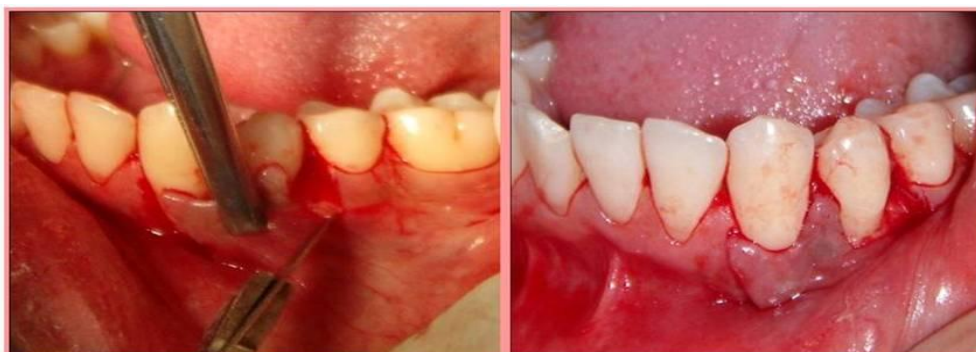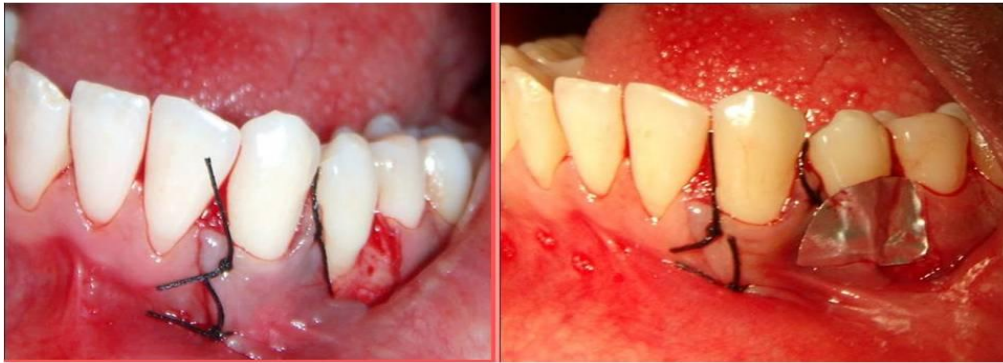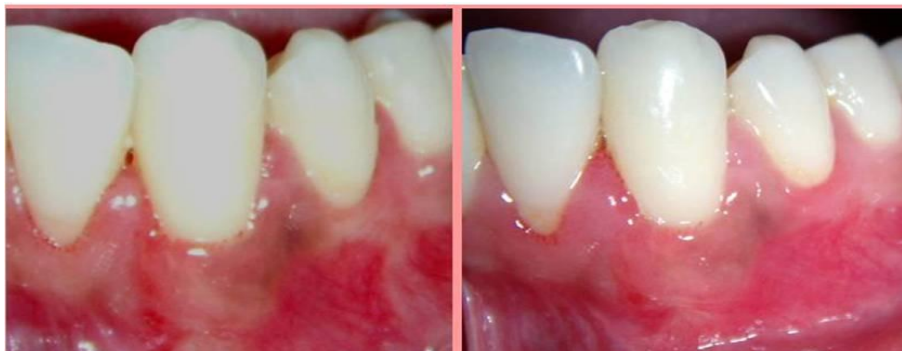


Figure 6: Lateral Pedicle Graft Rotated To Recipient Site.

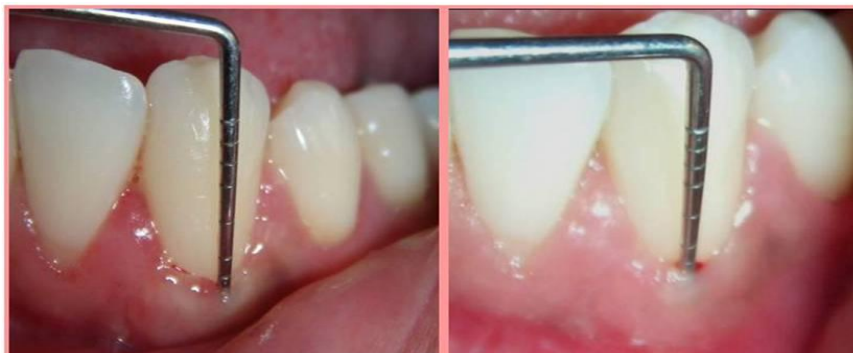



**Figure 7: Pedicle Graft Is Stabilized With Sutures.**



**Figure 8: Post-Operative Photographs - One Month and Two Months of Surgery.**



**Figure 9: Post-Operative Photographs Of Three Months and Six Months of Surgery.**

### DISCUSSION

In the past few decades various periodontal plastic surgical procedures have been described and employed in the treatment of gingival recession e.g. laterally positioned flaps, coronally advanced flaps, free gingival grafts, sub epithelial connective tissue grafts, acellular dermal matrix allograft and guided tissue regeneration. The main goal of any of these procedures was to achieve a complete coverage of the exposed root surface in order to gain an esthetically pleasing result. The optimal method of root coverage was based on recession etiology, activity and patient's age and esthetic demands. There were many important factors that play a major role in the selection of employment of any of the above mentioned techniques for the treatment of exposed root surface. Among these factors the presence of appropriate gingival papillae play a major role as it provides with an adequate

vascular supply and creates the possibility of proper placement of the graft at the desired site. [2] The advantages of Lateral Pedicle Graft were a single surgical site, no separate donor area, preservation of the blood supply of the pedicle flap covering the root surface and color of the graft tissue was in harmony with that of the surrounding tissue.

This case report presented lateral pedicle graft surgical technique for the treatment of isolated or single tooth marginal tissue recession (denuded root surface). Grupe and Warren in 1956 had suggested that the laterally repositioned flap has shown to be the most successful procedure for the treatment of gingival recession. This procedure was employed in this particular case because the adjacent areas had good periodontal condition with keratinized gingival bands and normal bone height. The various advantages in using this technique can be: reduced hypersensitivity, adequate blood supply to the flap and good color matching along with clinical attachment gain. [8,9] In this case, the predictability of root coverage using lateral pedicle graft is complete and the second surgical intervention is avoided.

### CONCLUSION

Lateral pedicle grafts can be useful in correcting Millers Class I and Class II recession defects. The graft has the advantage of retaining its own blood supply which can aid healing, however, this graft should be restricted to cases where the gingival bio-type is thick and there is sufficient amount of keratinized tissue adjacent to the recession defect.

### REFERENCES

- [1] Ronan Allen. J Ir Dent Assoc 2011;20-30
- [2] Neeraj Aggarwal, Rosaiah K, SSV Prasad. PJSR 2010;27-30
- [3] Jun-Beom Park. JOS 2009;371-21
- [4] Michael Sonick. PP&A 2012;4:39-48
- [5] Nirwal Anubha, Chaubey KK, Arora Vipin, Thakur Rajesh K, Zafri Zeba, Narula Inderpreet. IJDS 2010;47-51
- [6] Om N Baghele, Dilip G Pol. IJDR 2012;195-202
- [7] M Patel, PJ Nixon, MF-Y Chan. Br Dent J. 2011;315-19
- [8] Hemachandra Babu. AEDJ 2011;47-9
- [9] Vijayaraghavan Anita, Rajaram Vijayalakshmi, J. Bhavna, Thyagarajan Ramakrishnan, Aravindkumar, Vikram Bali. JISP 2008;51-4
- [10] Thiago Marchi Martins, Alvaro Francisco Bosco, Guilherme Giovani Gazoni, Sabrina Feltrin Garcia. RSBO 2011;464-8
- [11] Rajaram Vijayalakhmi, Sudhakar Uma, Ravindra Survanakumar, Thyagarajan Ramakrishnan, Pamela Emmadi, Vijayaraghavan Anita. Perio 2008;29-33
- [12] Heinz Erpenstein, Raphael Borchard. Perio 2006;139-52