

# Research Journal of Pharmaceutical, Biological and Chemical Sciences

## An Anatomical Study of Sacral Hiatus in Human Dry Sacra.

Nagashree MV<sup>1\*</sup>, Veena Pai<sup>1</sup> and Gireesh<sup>2</sup>.

<sup>1</sup>Department of Anatomy, Sri Siddhartha Medical College, Tumkur, Karnataka, India.

<sup>2</sup>Department of General Medicine, Sri Siddhartha Medical College, Tumkur, Karnataka, India.

### ABSTRACT

Sacrum is a large triangular bone formed by the fusion of five sacral vertebrae. The sacral canal is formed by sacral vertebral foramina; its caudal opening is called as sacral hiatus. The sacral hiatus transmits the lower sacral and coccygeal nerve roots. The sacral hiatus is very important for administration of caudal anesthesia in various surgical procedures. Hence anatomical variations of sacral hiatus are very important for successful anesthesia. A total number of 51 dry human sacral bones were collected from the department of anatomy, Sri Siddhartha Medical College, Tumkur. Each sacrum was studied for parameters like shape of the hiatus, level of the apex of the hiatus, level of base of hiatus, and length of the hiatus. The results were tabulated and compared with other studies. The various shapes of sacral hiatus were observed which include inverted 'U' shaped 23.5%, inverted 'V' shaped 39.2%, elongated 25.4%, irregular shape 9.8% and complete agenesis in 1.9%. The level of apex of sacral hiatus was commonly found against 4<sup>th</sup> sacral vertebra level in 56%. The level of base of sacral hiatus was commonly found against 5<sup>th</sup> sacral vertebra. The mean length of sacral hiatus was 21.5mm. The knowledge of anatomical variations of sacral hiatus is significant in the administration of caudal epidural anesthesia.

**Keywords:** Sacral hiatus, Sacral canal, caudal epidural anesthesia.

*\*Corresponding author*

## INTRODUCTION

The sacral hiatus is the caudal opening of the sacral canal present at the level of 4<sup>th</sup> fused sacral spines or the lower end of median sacral crest. The sacral hiatus contains lower sacral and coccygeal nerve roots, filum terminale externa and fibro fatty tissue. The dorsal wall of the sacral canal may be variably deficient due to imperfect development of laminae and spines [1]. Anatomy of sacral hiatus is very important during administration of caudal epidural block.

Sacral hiatus has been utilized for administration of epidural anesthesia in orthopedic and obstetric practice [2]. It has been used for many years as it is the easiest and safest approach to the epidural space when performed correctly. The reliability and success of caudal epidural anesthesia is dependent on anatomical features of sacral hiatus. The method is also used to provide perioperative and postoperative analgesia in adults and children [3].

## MATERIALS AND METHODS

In the present study a total no of 51 dry human sacra were collected in the department of anatomy, Sri Siddhartha Medical College, Tumkur. The different parameters like shape of the hiatus, level of apex and base of the hiatus, length measured from apex to midpoint of base, were recorded. All the measurements were taken with the help of caliper. The results were tabulated and discussed.

## OBSERVATIONS AND RESULTS

**Table No 1: Shape of the Sacral Hiatus (n=51)**

SL NO	Shape	No of Sacra	Percentage (%)
1	Inverted U	12	23.5%
2	Inverted V	20	39.2%
3	Elongated	13	25.4%
4	Irregular	05	9.8%
5	Complete agenesi	01	1.9%

Out of 51 sacra one sacrum had complete agenesi of dorsal wall of sacral canal. Hence it is excluded from the measurements of bony hiatus.

**Table No 2: Location of apex (n=50)**

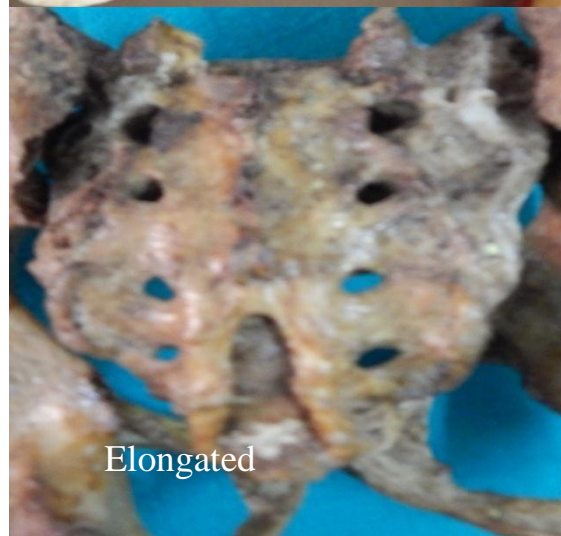
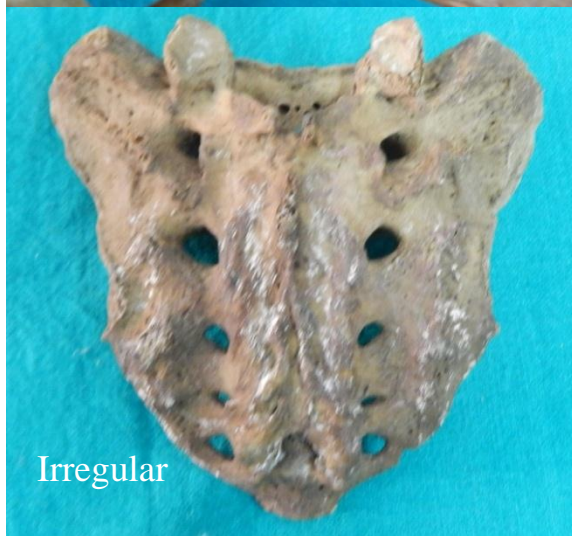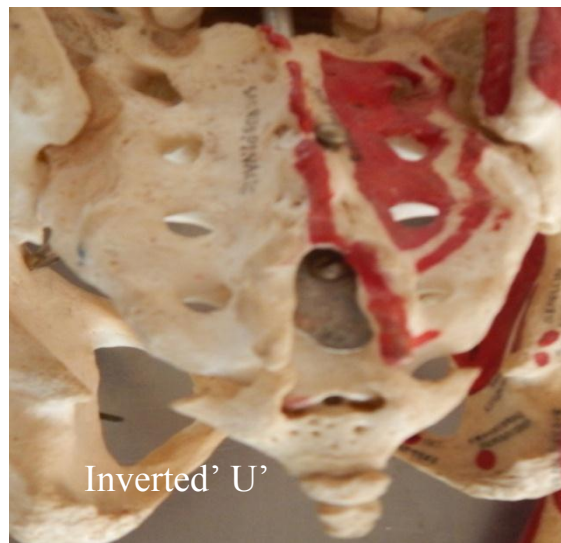
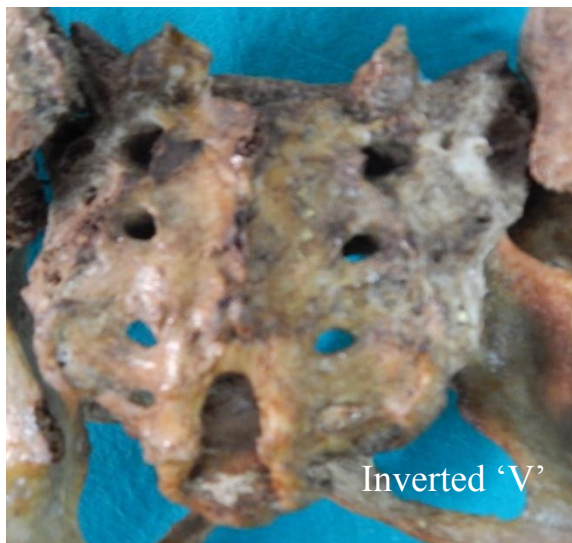SL NO	Location of Apex	No of Sacra	Percentage (%)
1	5 <sup>th</sup> Sacral vertebra	07	14%
2	4 <sup>th</sup> Sacral vertebra	28	56%
3	3 <sup>rd</sup> Sacral vertebra	13	26%
4	2 <sup>nd</sup> Sacral vertebra	02	4%

**Table No 3: Location of Base (n=50)**

SL NO	Location of Base	No of Sacra	Percentage (%)
1	5 <sup>th</sup> Sacral vertebra	33	66%
2	Between 4 <sup>th</sup> and 3 <sup>rd</sup> Sacral vertebra	06	12%
3	4 <sup>th</sup> Sacral vertebra	05	10%
4	Coccyx	06	12%

**Table No 4: Length of the sacral hiatus (n=50)**

SL NO	Length	No of Sacra	Percentage (%)
1	0-10mm	06	12%
2	11-20mm	23	46%
3	21-30mm	14	28%
4	31-40mm	05	10%
5	>40 mm	02	4%





## DISCUSSION

The morphometrical study of sacral hiatus is of great importance, since this route is frequently utilized for caudal anesthesia in perineal surgery and caudal analgesia during labour and delivery. Edwards and Hingson in 1941, for the first time used the sacral hiatus for administering continuous caudal analgesia during labour [4].

The specimens in the present study had normal 5 segment composition in 74.5%. The sacralization of 5<sup>th</sup> lumbar vertebra was observed in 9.8%, partial lumbarization of sacral vertebra in 5.8% and coccygeal ankylosis was observed in 9.8%. However Trotter and Lanier observed sacralization of 5<sup>th</sup> lumbar vertebra and coccygeal ankylosis in 12.6% and 39.3% respectively. Willis in his study reported partial and complete sacralization in 4.4% and 1.1% respectively. The present study also confirms the incidence [4].

In the present study the inverted U shaped sacral hiatus was observed in 23.5%, inverted V shaped hiatus in 39.2%, elongated hiatus in 25.4% irregular shape in 9.8%. The most common being inverted V shape and the inverted U shape. In the study of Vinod kumar et al the inverted U and inverted V shaped hiatus were observed. The inverted V shape was observed in 46.53% and inverted U was observed in 29.7% [4].

Complete agenesis of dorsal bony wall of sacral canal was observed in 1.9% in the present study. This corresponds to the results of other workers namely Trotter 1.8% and Vinod kumar et al 1.49% [2].

The apex of sacral hiatus was seen most commonly at the level of 4<sup>th</sup> sacral vertebra in 56% which is similar to the studies of other authors. Vinod kumar et al reported in 76.23% of the sacra the apex was present against 4<sup>th</sup> sacral segment. Sekiguchi M et al reported in 64% of

cases the hiatus present against 4<sup>th</sup> sacral vertebra. Trotter et al and Lanier et al in their series reported the mean level of apex of hiatus to be at lower third of 4<sup>th</sup> sacral vertebra [2,4,5].

The base of the sacral hiatus was present against 5<sup>th</sup> sacral vertebra in 66% in the present study which corresponds to the study of Vinod Kumar et al 83.17% [4].

In the present study the length of sacral hiatus varied from 12-57mm with a mean length of 21.5mm. In 46% of cases it was 11-20mm. Vinod Kumar et al observed mean length of hiatus as 20mm in males and 18.9mm in females. Similar results were noted in the studies of Trotter et al in which the length varied from 0-60mm with a mean of 22.5mm and Lanier et al observed mean length was 25.3+<sub>9</sub>mm [2,4].

### CONCLUSION

The knowledge of anatomical variations of the sacral hiatus is very important for the successful caudal epidural anesthesia. Understanding of these variations may improve the reliability of caudal epidural anesthesia.

### REFERENCES

- [1] Neil BR. The Back. In: Susan S, Patricia C, Alan CR, Michael GA, Jeremiah HC, David J, et al. editors. Gray's Anatomy the anatomical basis of clinical practice. 40<sup>th</sup>ed. London: Churchill Livingstone Elsevier; 2008. p.725-8.
- [2] Nagar SK. J Anat Soc India 2004; 53(2):18-21.
- [3] Vadodaria B, David C. Practical Procedures. 1998;8:1-3.
- [4] Vinod kumar, Pandey SN, Bajpai RN, Jain PN and Longia GS. J Anat Soc India 1992;41(1):7-13.
- [5] Sekiguchi M, Yabuki S, Saton K, Kikuchi S. Clin J Pain 2004;20(1):51-4.