



# Research Journal of Pharmaceutical, Biological and Chemical Sciences

## A Rare Case of Cavernous Hemangioma in the Tonsil.

Shoba Kishore\*

Department of General Pathology, Sree Balaji Dental College and Hospital, Bharath University, Chennai, Tamil Nadu, India.

### ABSTRACT

A 28 year old male was presented with foreign body sensation in the left tonsillar region with chronic tonsillitis. Clinically diagnosed as Hemangioma . The tumor was removed by snare method and the histopathological report was cavernous Hemangioma. Although clinically diagnosed, histopathological confirmation reveals confirmatory diagnosis. Hemangiomas are the most common tumors of the head and neck region but in this case reported a rare case of hemangioma in the tonsillar region.

**Keywords:** Cavernous Hemangioma, Benign tumor, Chronic Tonsillitis.

*\*Corresponding author*

## INTRODUCTION

Hemangioma is a benign tumor of the blood vessels. The term hemangioma has traditionally been used as a generic term to describe a large variety of vascular lesions with different aetiologies [10]. Currently the term hemangioma is restricted to a distinct proliferative lesion of early childhood being more a tumor than a vascular malformation. Hemangiomas are the most common vascular tumor, with an incidence of 1-2.6% [9]. Cavernous Hemangioma also called as Angioma Cavernosum or Cavernoma. Head and neck is the most common region, hemangiomas can also occur in the trunk or extremities. Tongue and floor of the mouth are the usual site involved [1]. They typically present at birth enlarge during first year of life and then usually spontaneously involute by the age of 5 years. In this case, the patient was diagnosed as chronic tonsillitis with cavernous hemangioma, but their occurrence in the tonsillar region is rare. A review of the literature showed that the hemangioma is rarely found in the tonsillar region [2,3].

## Case Report

A 28-year old male presented with history of recurrent throat pain and fever for past six months. History of constant foreign body sensation on left tonsillar region. Physical examination showed soft purplish mass filling the left tonsillar region and swelling of the regional lymph nodes. The diagnosis was made as chronic tonsillitis with left tonsillar hemangioma. Hematological investigation were within normal limits. In this case chronic tonsillitis and localized tumor of the tonsillar tissue are the indications for tonsillectomy. Surgical excision of the mass along with the tonsil was performed by snare method. Intraoperative and post operative period was unremarkable. Grossly, a red to bluish, soft mass measuring < 0.5cm in diameter. Microscopically, showed reactive lymphoid tissue with numerous large dilated vascular spaces lined by endothelial cells filled with blood. The histopathological diagnosis was cavernous hemangioma (fig.1).

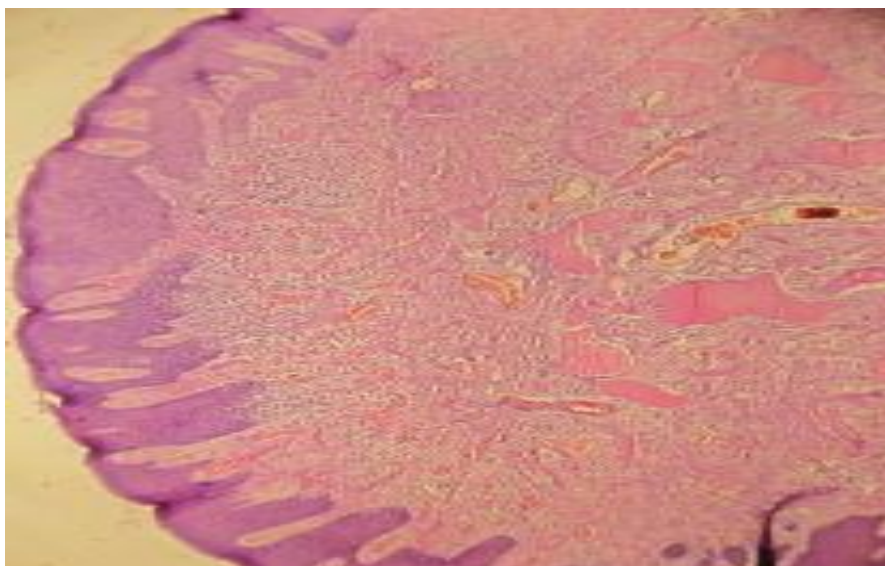


Figure1: Microscopy: Numerous dilated vascular spaces lined by endothelial cells. (H&E, x100)

## DISCUSSION

Hemangiomas are quite common lesions, especially in infancy and childhood. The common site is the skin of the face. Cavernous hemangiomas are most common in the skin and other sites are mucosa of the oral cavity, stomach and small intestine. Tongue and floor of the mouth are the commonest site of the lesions in oral cavity. Most hemangiomas are developmental in origin and have both hemangiomatous and lymphangiomatous components [1]. Approximately 30% of infantile hemangioma will regress by the age of three years, about 50% by the age of five years, and 70% by the age of seven years [11,12]. If hemangioma fails to regress by the age of 5-6 years, then it is unlikely to regress completely.

Histologically hemangioma consists of numerous blood filled spaces lined by endothelial cells and surrounded by connective tissue. Hemangiomas have been classified according to their clinical appearance and the caliber of vessel involved. Mulliken and Glovacki in 1982 are divided the vascular deformities, into two groups: hemangioma and the vascular malformations. The hemangioma can also be classified depending on the vessel type involved (arterial or arteriovenous) or flow (capillary or venous) type involved (15). Mulliken and colleagues defined the endothelial characteristics and cell biology of vascular tumors and vascular malformations [4,5].

Microscopically, when the lesion shows lobular configuration composed of capillary-sized, thin walled, blood filled vessels lined by single layer of plump endothelial cells is referred to as capillary hemangioma. When the lesions are composed of thin walled large vessels with cystically dilated spaces filled with blood are lined by flattened endothelial cells and separated by scanty connective tissue is referred as Cavernous hemangioma. A third histological variant is the cellular (juvenile) hemangioma [6].

Cavernous Hemangioma and venous vascular malformations are difficult to distinguish. The latter do not involute and may actually grow with the time, hormonal influences, infection, thromboses, trauma [8]. The hemangioma is rarely reported as localized within the tonsillar tissue. In this case Hemangioma, a rare presentation in the region of left tonsil. Hemangioma lesions are soft, irregular and purplish in color (1). In this case the lesion was bluish to purplish, soft, irregular surface restricted to the tonsillar tissue. Hemangiomas occupy a gray zone between hamartomatous malformation and true neoplasm. Hemangiomas typically present at birth and also occur in children [14].

Occasionally hemangiomas may ulcerate or bleed or develop secondary infections [13]. Such complications are not there in this case.

The most commonly reported tumors are papilloma, angioma, fibroma, lymphangioma, myxoma, lipoma, adenoma, teratoma, inclusion cyst and teratogenous cyst. Histologic examination will confirm the diagnosis. In this case, Hemangioma in the Tonsillar region was reported. Seventy percent of cavernous hemangiomas resolve on their own by the time of adolescence and 50% have an association with the skin hemangioma [8].

In this case, the lesion was restricted to the tonsillar tissue and the lesion was noticed at the age of 28 years and there is no association with skin lesions.

In this case histopathologic examination showed a benign neoplasm composed of numerous large dilated vascular spaces lined by flattened endothelial cells with reactive changes. The histopathological diagnosis was Cavernous Hemangioma. Although clinically diagnosed Histological diagnosis was confirmatory diagnosis.

In this case there were no complications associated with the tumor. Chronic tonsillitis and localized tumor in the tonsil are the indications for tonsillectomy [7]. Therapy is indicated when there are complications like hemorrhage, pain, infection, ulceration airway obstruction, cosmetic deformity or thrombocytopenia. In this case repeated throat pain and foreign body sensation are the indications for tonsillectomy with the removal of the tumor.

### CONCLUSION

The occurrence of Hemangioma in the Tonsil is a rare presentation. Most of the oropharyngeal hemangiomas are developmental in nature and localized to soft tissues. Most commonly occur in the tongue and the floor of the mouth. Tonsillar hemangioma is reported rarely in the literature. In this case the tumor localized to the tonsillar tissue with chronic tonsillitis. Though clinically diagnosed Histopathological examination of the specimen is must to confirm the diagnosis.

### REFERENCES

- [1] Hibbert J. Oral cavity. In: Hibbert J, editor. Scott- Brown's otolaryngology. Laryngology and head and neck surgery. Chap. 3. Vol. 5. 6<sup>th</sup> ed. Oxford: Butterworth-Heinemann. P. 1-32,1997.
- [2] Badia SE, Toro AJJ, Romero ML, Rocher PF, Domenech FG. An Otorrinolaringol Ibero Am 1994;21:409-16.
- [3] Jensen JH. Ugeskr Laeger 143:3392-3, 1981
- [4] Mulliken JB , Zetter BR, Folkman J. Surgery 1982;92:348.
- [5] Mulliken JB, Glowacki J. Plast Reconstr Surg 1982;69:412-420.
- [6] Waal I, Snow GB. Benign tumors and tumor-like lesions. In: Schuller DE, editor. Otolaryngology head and neck surgery. Part 6. Chap. 76. Vol 2. 3th ed, p. 1407-1417, 1998.
- [7] Naumann HH: Head and Neck Surgery. Face and Facial Skull, Vol. 2, Chap. 8 to 15 , p. 359,1980.
- [8] Fatican OZTURK, et al. Tip Fakultesi Dergisi 2004;2:34-36.
- [9] Van Aalst JA, Bhullar A, Sadove AM. J Craniofac Surg 2003; 14: 566-583.
- [10] Mulliken JB, Glowacki JG. Plast Reconstr Surg 1982; 69: 412-420.
- [11] Bowers RE, Graham EA, Arch Dermatol 1960; 82: 667-680.
- [12] Nakayama H. J Dermatol 1960; 82: 667-680.
- [13] Requina L, Sanguenza OP. J Am Acad Dermatol 1997; 37: 887-919.
- [14] Coffin CM, Dehner LP. Pathol Annu 1993, 28(Pt 1): 97-120.
- [15] MS Greenberg, M Glick, and JA Ship, Burkett's Oral Medicine, BC Decker, 11<sup>th</sup> edition,2008.