

# Research Journal of Pharmaceutical, Biological and Chemical Sciences

## Lymphatic Filariasis Presenting as Paratesticular Tumour- A Case Report.

Thulasi Raman R<sup>1\*</sup>, Hemanathan G<sup>2</sup>, Manimaran D<sup>3</sup>, Dost Mohamed Khan<sup>4</sup> and  
Anuradha S<sup>5</sup>.

<sup>1</sup> Assistant professor, Department of Pathology, Shri Sathya Sai Medical College And Research Institute.

<sup>2</sup> Resident, Department of Pathology, Shri Sathya Sai Medical College And Research Institute.

<sup>3</sup> Associate professor, Department of Pathology, Shri Sathya Sai Medical College And Research Institute.

<sup>4</sup> Associate professor, Department of Pathology, Shri Sathya Sai Medical College And Research Institute.

<sup>5</sup> Professor & HOD, Department of Pathology, Shri Sathya Sai Medical College And Research Institute.

### ABSTRACT

Filariasis commonly presents with symptoms due to lymphatic obstruction and only rarely presents as a mass lesion. We encountered a case which presented as a paratesticular mass without a hydrocele. This kind of mass presentation can mislead the clinician for a neoplastic lesion and may cause unnecessary panic to the patient. We outline this case of filariasis mimicking as paratesticular neoplasm with relevant review of literature.

**Keywords:** lymphatic filariasis, wuchereria bancrofti, paratesticular pseudotumour

*\*Corresponding author*



## INTRODUCTION

Lymphatic filariasis is a vector borne parasitic disease commonly caused by *Wuchereria bancrofti*. It is one of the major health problem in India. It commonly presents as Elephantiasis, hydrocele with epididymo-orchitis, lymph varix or chyluria. Paratesticular involvement without hydrocele is very rare form of clinical presentation. We thus present this unique case of filariasis, presenting as paratesticular tumour without hydrocele with relevant literature review.

## CASE REPORT

A 62 year old male presented with testicular swelling for a period of 6 months which was gradually increasing in size. It was not associated with fever or pain. No history of trauma in the past. On examination, enlargement of left testicle with vague nodularity was noted. The right testis and cord were normal. USG showed illdefined, heteroechoic nodule measuring 5 x 4.5 cm over the left paratesticular region suggesting a paratesticular neoplasm. Right testicular echoes was normal. Other relevant investigations were within normal limits. Intraoperatively an irregular enlargement of left testis and paratestis was noted. Patient underwent high left inguinal orchidectomy with suspicion of malignancy.

Grossly the resected specimen measured 9x 7 x 3 cm with attached cord measuring 3 cm in length. External surface was brownish with vague nodularity. Cut surface showed testis measuring 2x2 cm at one pole with a surrounding tan firm mass measuring 6x 5 cm. Microscopically sections from the testis showed atrophic seminiferous tubules with chronic inflammatory cells in the interstitium, rete testis and epididymis. Section from the paratesticular mass showed extensive area of fibrosis with dilated lymphatic channels and lymphoplasmacytic infiltrate. At foci cut sections of adult gravid filarial worms with surrounding suppurative infiltrate was noted. Neither granuloma nor eosinophils was noted in the stroma surrounding the worm. The patient was exposed to DEC provocation test but no microfilaria was detected in the multiple blood smears studied. The follow up of patient was uneventful.

## DISCUSSION

Filariasis is hoary disease known from 6<sup>th</sup> century BC, since it was reported by Susruta. Microfilaria was then discovered by Lewis in 1872 which brought a major revolution in its diagnosis. Elephantiasis, hydrocele, lymph varix and chyluria are the usual clinical presentation and it is mainly due to lymphatic obstruction caused by fibrosis of lymphatic channels. In genital filariasis 90% of the people presented with hydrocele.

Sario G Barreto et al [1] reported a similar case of filariasis which presented as testicular tumor. They found granulomas surrounding the worm which was absent in our case. However eosinophilic infiltrate which alarms the pathologist to hunt for parasite was absent in their case too.

Deepti Matrej et al [2] reported two case of paratesticular tumor with a diffuse proliferation of the tunica and named it as fibrous pseudotumor of the testis. Extensive

fibrosis of tunica as noted in our case may later go for ossification and calcification giving a appearance of egg shell calcification on imaging.

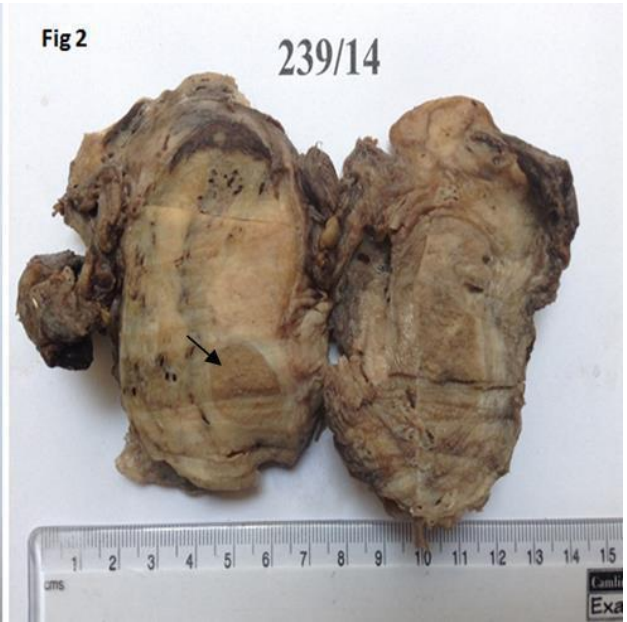
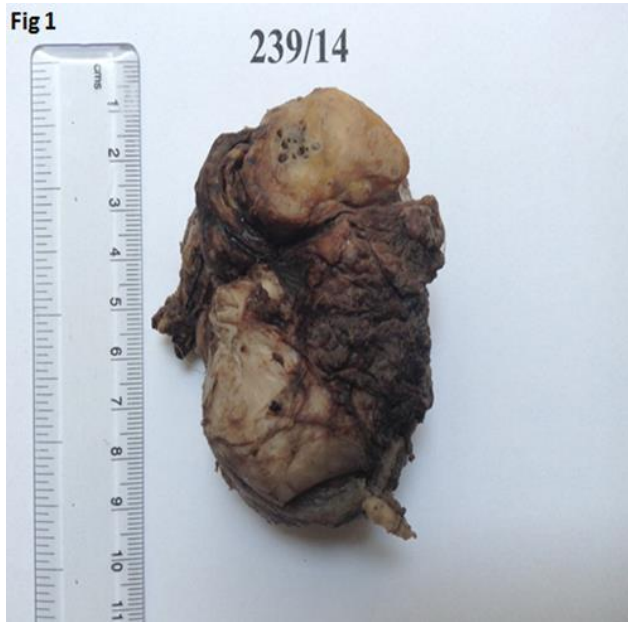
Figure 1: External surface show mass in the paratesticular region.

Figure 2: Cut section show testis [thin arrow] with a gray tan paratesticular mass.

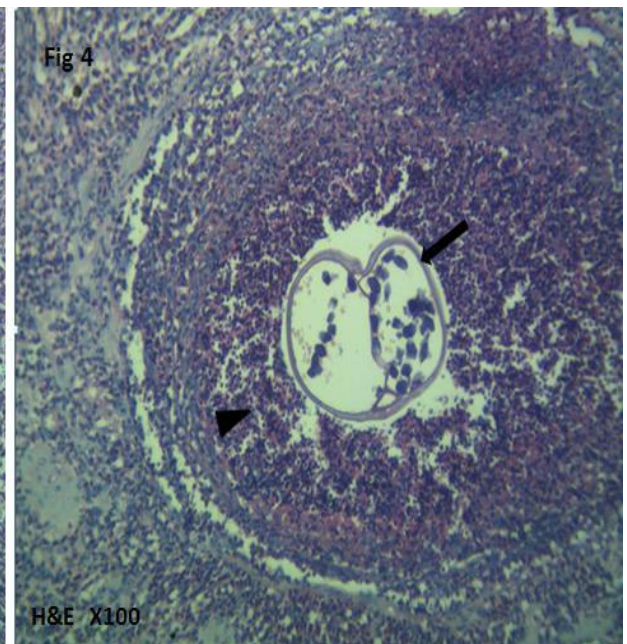
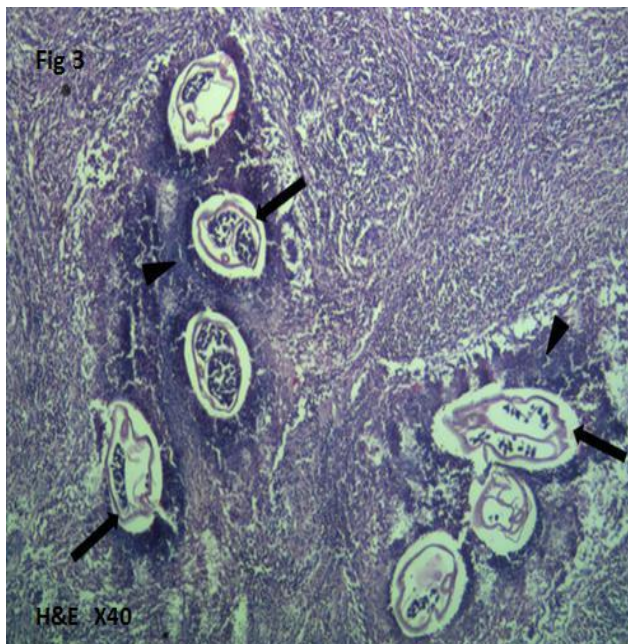
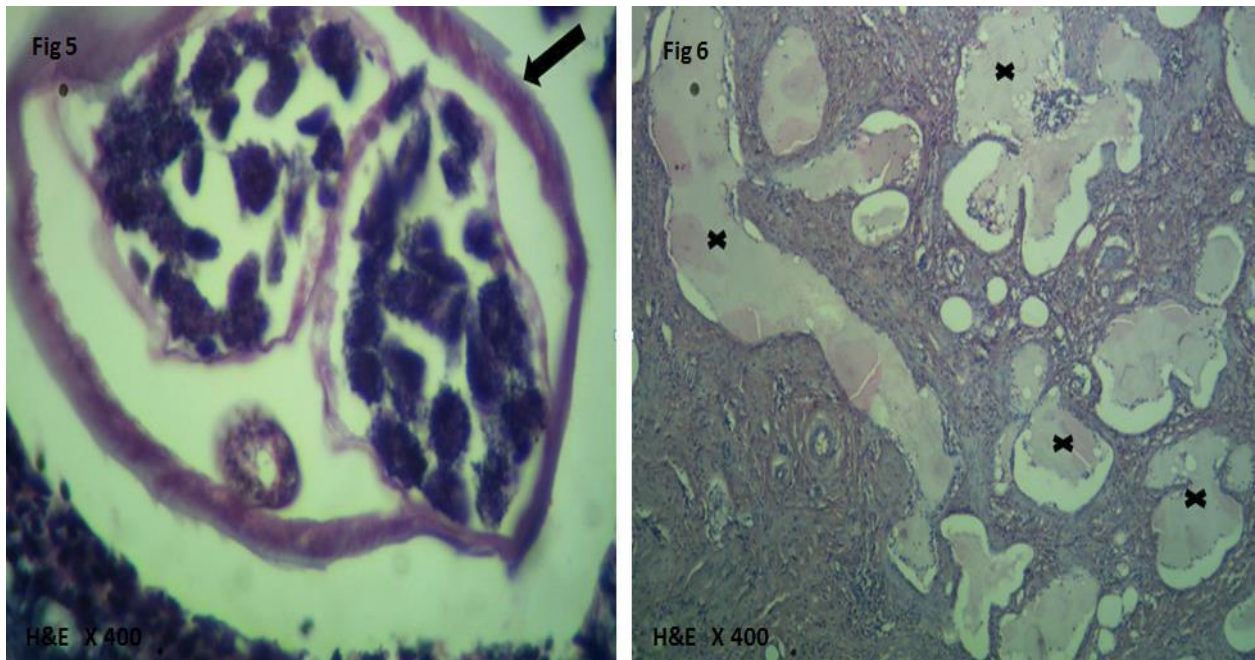


Figure 3,4: Photomicrograph show cross sections of adult gravid filarial worm [thick arrow] with surrounding suppuration [arrow head]



**Figure 5: Photomicrograph show cut section of a gravid worm in higher magnification. Fig – 6 Paratesticular area show multiple dilated lymphatic channels [cross].**

Pankaj Kumar Gurg et al [3] reported a case of testicular filariasis, where there was obstruction of lymphatics with acute inflammatory reaction which clinically mimicked as torsion testis. But in our case the patient was asymptomatic with a silent testicular mass, which masqueraded the clinicians and radiologist as a paratesticular tumour. Even gross appearance suggested a paratesticular tumor. Only on histopathological examination one adult gravid worm was noted focally in the fibrosed tunica. Thus extensive sections from the specimen should be studied in all cases of testicular fibrous pseudotumors.

Many nematodes apart from *Wuchereria bancrofti* can present as paratesticular tumour. Jinskallampalli et al [4] reported a case of paratesticular swelling caused by *diclofilaria immitis* in a 13 year old boy. Similarly Freifeld Y et al [5] reported a case of paratesticular tumour caused by *diclofilaria repens*. In India tuberculosis is a common cause for paratesticular pseudotumour. Presence of caseating granulomas and demonstration of AFB is helpful in diagnosis.

Muller et al [6] reported a case of lymphangiosarcoma arising in the background of lymphedema caused by chronic filarial infection. Majidahmed Talikoti et al [7] reported a case of scrotal leiomyosarcoma with coincidental filarial worm in a 67 yr old patient. Thus filarial infection can be a cause or incidental discovery in malignancies.

Vinaya B Shahet al [8] diagnosed filariasis in three cases with epididymal nodules by FNAC where *microfilaria* was noted in two and entire adult worm with hyaline sheath in another. Similarly Mitra SK et al [9] also reported *microfilaria* in FNA smears from testicular swelling. Presence of eosinophils is another clue in the diagnosis. FNAC can be used in confirming the diagnosis in cases with positive filarial dance sign in imaging. We did not attempt FNAC in our case, since filariasis was not suspected clinically or by imaging. However the role of FNAC in paratesticular swellings is controversial because of its sampling



error and it may rarely cause dissemination of tumour cells through needle tract in case of malignancy.

We attempted DEC provocation test to induce microfilaremia but the parasite was not found in the peripheral blood. The probable reason is due to surgical removal of the whole lesion and absence of similar lesion elsewhere. A single dose co-administration of ivermectin and DEC remains the gold standard in the treatment of filariasis. Conservative surgery should be done only in cases with lymphedema with extensive fibrosis.

### CONCLUSION

Pseudotumours caused by infections can mimic as neoplasm of testis or paratestis and histopathological diagnosis with demonstration of organisms is the gold standard. Any fibrous pseudotumour should be carefully studied to rule out infectious etiology, especially filaria and tuberculosis in countries like India.

### REFERENCES

- [1] Savio G Barreto, Jude Rodrigues, and Roque GW Pinto. J Med Case Rep 2008; 2: 321.
- [2] DeeptiMutreja, MurukesanMurali, AshutoshArya. Arch Int Surg 2013;3:70-2.
- [3] Pankaj Kumar Garg, Shuchi Bhatt, BineetaKashyap, Ashish George &Bhupendra Kumar Jain. J Vector Borne Dis 2011;48:119–121.
- [4] Jinskallampalli, Sarah J Wood, Timothy O Dempsey, Ross J Cragie. BMJ Case Reports 2013; doi:10.1136/bcr-2013-200775.
- [5] Freifeldy MD, Stein A MD, Nashashibi M MD, Banethg PhD, Dekel Y MD. BJUI; 2012.
- [6] Muller R, Hajdu SI, Brennan MF. Cancer 1987 Jan 1;59(1):179-83.
- [7] Majid Ahmed Talikoti, SV S Deo, Nootan K Shukla, Ashwin A Kallianpur and Mamraj Gupta. World J Surgical Oncol 2011, 9:20.
- [8] Vinaya B Shah, Tanuja M Shet, and Shilpa K Lad. J Cytol 2011; 28(3): 103–107.
- [9] Mitra SK, Mishra RK, Verma P. J Cytol 2009;26(1):11-4.