

Research Journal of Pharmaceutical, Biological and Chemical Sciences

Incidence of Oral Condyloma Acuminatum in Rohilkhand region of Uttar Pradesh, India.

Sumeru Samanta*, Biswajit Das , and Ayaz Khurram Malik.

Department of of Biochemistry, Rohilkhand Medical College and Hospital, Bareilly, Utter Pradesh, India.

ABSTRACT

The purpose of this study was to investigate the occurrence rate and clinicopathological features of condylomatous lesions around Rohilkhand region of Uttar Pradesh along with also determine the mode of transmission of this disease and to find the genotype of Human Papilloma Virus involved in the oral condyloma cases around Rohilkhand region. For this study 24 instances of Oral Condyloma Acuminatum were reviewed. Their HPV genotypes were evaluated by PCR amplification using PGMV Primer. In our study out of 24 cases, 14 were male and 8 were female with the age groups range from 20-40 years and 2 children in age groups of 13months and 09 months. Social Evaluation confirmed unprotected sex in 67% of the investigated subjects and others are not confirmed. Mostly the subjects belong to low socio-economic strata of the society. The result of PCR amplification demonstrated HPV 16 DNA being positive in 12 cases, HPV 6 in 9 cases and HPV 11 in 3 cases. Oral Condyloma acuminatum is mainly caused by HPV 16, 6 and 11. The mode of transmission is by unprotected multipartner sex or sexual abuse. The major age group affected is between 20-40 yrs.

Keywords: Condyloma acuminatum, oral mucosa, Human Papilloma Virus, rohilkhand region.

**Corresponding author*



INTRODUCTION

Condyloma Acuminatum (CA) is a Human Papilloma induced sexually transmitted disease that is being presented as benign papillary lesion commonly found on ano-genital tract, skin and mucosa [1,2,3]. The major subtypes are 6 and 11 [3,4]. Oral condyloma acuminatum has been reported to be resulted from oro-genital sexual transmission or may be through hand to mouth auto inoculation in case of adults [5,6]. There are some discrete data about occurrence of condylomata in children's due to sexual abuse [7-9]. However the main cause of anogenital condylomata transmission is through parental infection, digital inoculation or autoinoculation, fomites and causal social contacts [10,11]. Which is again confirmed by our study in a short model. Oral condyloma has also been reported in association with HIV status of the children [12].

The number of reported cases of oral CA has increased rapidly in recent years although they are still sparse particularly in children's [10,13] and which are positively correlated to increase condylomata in adults [14]. However there is little data available concerning oral mucosa condylomata in children. In this paper, the clinicopathological features of 24 cases of oral condylomas have been studied and their HPV genotypes have been evaluated by PCR amplification using PGMY primer.

MATERIALS AND METHODS

Total 24 cases selected for study in Rohilkhand Medical College and Hospital, Bareilly, U.P. Out of 24 cases 14 were male and 8 were female and 2 children. The age range in male and female subjects were 20-40 years whereas in children the age of 13 months and 09 months. The duration of study was 18 months from June 2012 to December 2013. Before performing the various tests, subjects consent had been taken. All the procedures reported here in the study have followed the guidelines approved by the locally appointed ethical committee. Differentiation from the more common squamous papilloma was made employing criteria specified for anogenital condylomata [15]. All the selected subjects clinical and histopathological examination had done. All the volunteers or subjects had provided samples for histological examination of the lesion from the oral cavity or anogenital region. The patients were recommended for a total excision of the lesion and subsequently leukoplasic lesion was excised. The excised specimens were undergone for HPV DNA testing. The cryopreserved samples were taken for the DNA isolation. The obtained DNA was amplified by PCR using the most common set of primer PGMY.

Controls: Four genital condylomata were used as positive controls and normal oral tissues served as negative controls.

RESULTS

Figures 1a and 1b show the papilomatous growth in lip and buccal mucosa. Photomicrograph showing the lesion under low power (a) and high power (b) showing

hyperplasia of squamous epithelium with Human papilloma virus (HPV) related acanthosis and koilocytic atypia in figures 2 a and 2b. Histopathological study has been observed that parakeratinized cells are present with lot of invagination with marked acathosis. HPV related Koilocytes are common in the upper spinous and corneal layers as seen in figure 3. Clinical data of oral condyloma in the patients according to number of cases, age group, and sex, site of lesions and probable source of transmission is tabled in table no. 1. The lesion appeared in children's between 9 months and 1 yr 1 month in two positive subjects we got. 8 of 24 patients were females to be found positive and all in the age group 20-40 yrs and major source of transmission are multiple sexual contacts, 2 of the follow up cases recurred 10 months after treatment. 14 cases are positive for males in the same age group as above and mode of transmission are same as above. The most common location were lower lip (14 cases) followed by tongue (7 cases), palate (2 cases) and commissure (1 case). The two children we have assessed, their mother had suffered from vulva and oral condylomata during pregnancy. Social evaluation confirmed multiple and unprotected sexual encounters and contacts in most of the adult subjects. The results of HPV DNA Genotyping and patient wise data are presented in table no.2. The PCR genotyping shows positive for HPV infection in all the assessed subjects. The majority of the positive cells exhibited koilocytic alterations (Figure-4). All positive controls were taken of HPV 16 strain and negative controls do not show any specific amplification with PGMY primer.

Figure 1a and 1b: Papilomatous growth in Lip and Buccal mucosa

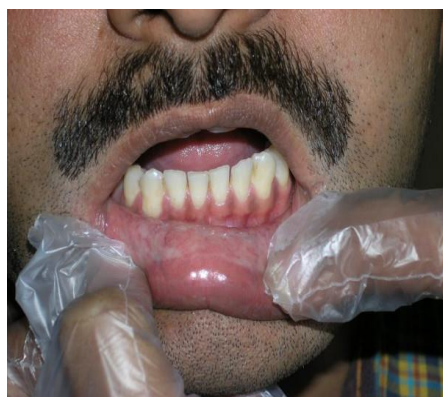

Fig: 1a

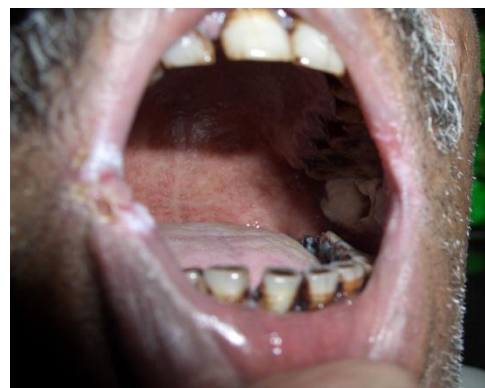

Fig. 1b

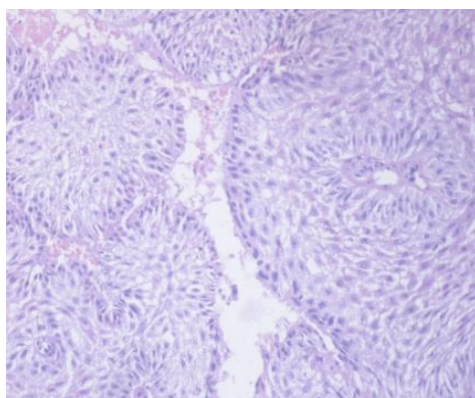


Fig. 2a 200 X

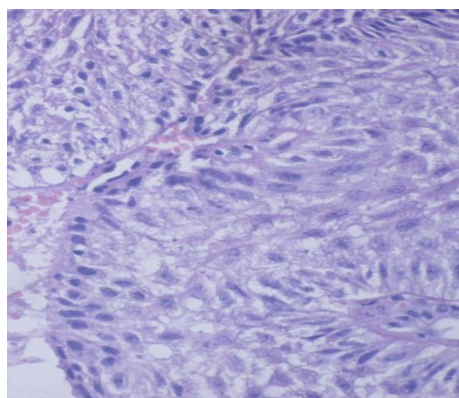


Fig. 2b 400 X

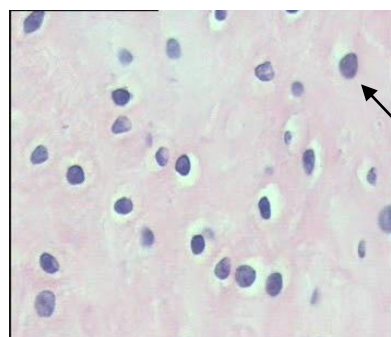


Fig. 3

Koilocytic Atypia

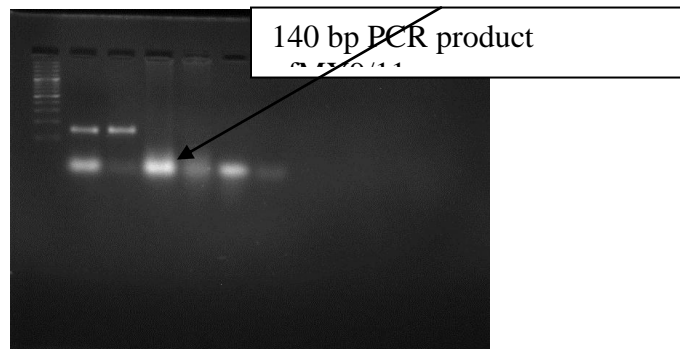


Fig. 4

Table 1

S.No.	No. of Cases	Age Group	Sex	Site of Lesion	Multiple Sexual Contacts	Other mode of transmission
1	2	0-2	Male	Palate	No	Yes (Maternal)
2	12 (2 recurred)	20-40	Male	Lower Lip, Tongue, and Commissure.	Yes	No
3	8 (2 recurred)	20-40	Female	Lower Lip & Tongue.	Yes	No
4	2 (1 recurred)	41-60	Male	Lower Lip	Yes	No

Table 2

Case No.	Age	Sex	HPV Genotype
1	1 yr 1 month	Male	HPV16
2	9 month	Male	HPV16
3	20 yrs	Female	HPV 6
4	21 yrs	Female	HPV16
5	21 yrs	Female	HPV16
6	23 yrs	Male	HPV16
7	24 yrs	Female	HPV 6
8	24 yrs	Male	HPV11
9	24 yrs	Female	HPV16
10	26 yrs	Female	HPV16
11	26 yrs	Female	HPV16
12	27 yrs	Male	HPV11
13	27 yrs	Female	HPV 6
14	29 yrs	Male	HPV11
15	30 yrs	Male	HPV16
16	34 yrs	Male	HPV16
17	36 yrs	Male	HPV 6
18	38 yrs	Male	HPV 6
19	38 yrs	Male	HPV 6
20	39 yrs	Male	HPV 6
21	39 yrs	Male	HPV16
22	40 yrs	Male	HPV 6
23	58 yrs	Male	HPV16
24	60 yrs	Male	HPV 6

DISCUSSION

Human Papilloma Virus is one of the most common DNA virus group in the world today affecting the skin and mucosal area of the body. There are at least eighty different types of HPV still identified. The area of infection varies with difference in strain involved. Mostly the CA associated with genital warts involved HPV 6 and HPV11 [16]. Condyloma Acuminatum has been discretely reported to occur in the oral cavity of adults [17-19]. In this study 24 instances of CA have been found in the oral cavity of different population mass (Adults and Children). The most common location for adults is lower lip and tongue, for the children it is palate. So there is a distinctive difference in location of infection among children's and their adult counterparts. Data indicates that the primary means of transmission of CA in adults is through sexual contacts with a person pre infected with HPV [20-22]. Sexual mode of transmission is also been observed in cases of children's which may be the result of sexual abuse [23, 24]. But in this study with only two positive children we have reviewed, the mode of transmission is entirely maternal. As most experts agreed that HPV lesions seen in any part of the body of the children can be resulted from vertical transmission from an infected mother [25]. Histopathologically CA is an exophytic papillary squamous proliferation exhibiting Koilocytes and a parakeratinized surface epithelium that often exhibits cryptic invagination in to an acanthoic spinous cell layer. Koilocytes are the hallmark of CA and HPV infection is found in upper spinous and corneal layer with a modified keratinocytes. In oral cavity CA superficial nuclei remain large and vesicular rather than small crinkled and pyknotic nuclei [1]. Oral condylomas noted in genital warts of the patients sexual partners showed increase rate from 25% to 65% after exposure. The average incubation period of HPV in host body is 2-3 months which may be prolonged to 1-8 months. Subclinical infection of HPV persists without forming macroscopic lesion [26]. It has been documented that patients with wide spread anogenital sex have a 50% incidence of histopathologically confirmed oral condylomas [27]. More than 75% of the oral condylomas are positive for HPV DNA especially HPV6 and 11 [28]. But our results shows a clear predominance of HPV 16 as per the study conducted by Liu Lai Kui et al. [28]

CONCLUSION

The majority of incidences of oral condyloma acuminatum we have reviewed are majorly caused by HPV 16 (50%). Sexual contact is the most common mode of transmission. Maternal transmission of HPV to children is also observed. HPV infection and its role in CA is extensively studied and observed in Purvanchal region of Uttar Pradesh province which is prone to Sexually Transmitted Diseases because of its low socio economic conditions prevailing over this areas. The author's data revealed Oral Condyloma Acuminatum is an increasingly common but frequently undiagnosed sexually transmitted disorder which is now being found more frequently in the oral cavity especially in lower lip, tongue, palate and commissure. A diagnosis of CA is based primarily on the clinical appearance of the lesion and histological finding in biopsied tissue specimen. The small pink warts are often confused with Mollesculum Contagiosum, thus proper and accurate diagnosis is required as sometime oral CA histologically overlap with squamous papilloma ^[1]. With increasing incidence of CA and correlation with STD should dealt seriously and awareness programme among the common mass should be taken as

it has been done in case of HIV in India. Treatment of these lesions is most commonly surgical excision, cryosurgery, electrocautery or LASER excision. These current therapeutic modalities are not effective completely in preventing complete recurrence. Thus careful monitoring of this lesion is important especially in a view of oncogenic association of this disease with HPV. Follow up examination must be recommended after treatment.

REFERENCES

- [1] Henley JD, Summerlin DJ, and Tomich CE. American J Histopathol 2004; 44,216-221.
- [2] Sehgal VN, Koranna RV, Srivastava SB. Int J Dermatol 1989; 28:75-78.
- [3] Padel AF, Venning VA, Evans MF, Quantrill AM, Fleming KA. Br Med J 1990;300:1491-1494.
- [4] Liu Lai Kui He Zhi Xiu and Li Yi Ning. J Pediatr Dent 2003;25:2.
- [5] Chonkas NC, Toto PD. Oral Surg Oral Med Pathol 1985;54:480-485.
- [6] Butler S, Molinari JA, Plezia RA, Chandrasekhar P, Venkat H. Rev infect Dis 1988;10:544-550.
- [7] Hanson RM, Glasson M, Mc Crossin I, Rogers M, Rose B, Thomson C. Child Abuse Negl 1989;13:225-233.
- [8] Davis AJ, Emans SJ. J Pediatr 1989;115:1-9.
- [9] Gunmann LT, Claire K, Hermann Giddens PA, Johnston WW, Phelps WC. Am J Dis Child 1992;146:694-699.
- [10] Obalek S, Jablonska S, Fabre M et.al. J Am Acad Dermatol 1990;23:205-213.
- [11] Obalek S, Misiewicz J, Jalonska S, Fabre M. Pediatr. Dermatol 1993;10:101-106.
- [12] Magalhaes MG, Buneo DF, Serra E, Goncalves R. J Clin Pediatr Dent 2001;25:103-106.
- [13] Lacey CHJN. Papilloma Virus Report 1991;2:31-32.
- [14] Koutsky LA, Galloway DN, Holmes KK. Epidemiol Rev 1988;10:122-162.
- [15] Lever WF, Schaumberg Lever G. Histopathology of the skin. Philadelphia, Pa:JB Lippincott;1975:352-360.
- [16] Dr.Gillison et.al. NEJM 2007.
- [17] Shaffer EL, Reimann BE, Gysland WB. J Oral Pathol 1980;9:163.
- [18] Jansen AB, Lancaster WD, Hartmann DP, Shaffer Jr EL. Am J Pathol 1982;107:212.
- [19] Jin, Toto YT. Oral Surg Oral Med Oral Pathol 1984;58:702.
- [20] Schneider A, Kirchmayr R, Devillier EM, Gissmann L. J Urol 1988;140:1431-1434.
- [21] Lecy C, Bauer HM, Reingold A et.al. J Natl Cancer Inst 1991;83:997-1003.
- [22] Schiffman MH. J Natl Cancer Inst 1992;84:394-398.
- [23] Franger AL. Adolescent Pediatr Gynecol 1990;3:38-41.
- [24] Ashin JO, Ogunbunjo BO, Rotowa HA, Adyemi Doro FBA, Osoba AO. Br J Venereal Dis 1983;59:325-326.
- [25] Gutman LT, Nerman Giddens PA, Morcia E, Phelps WC. J Pediatr 1993;91:31-38.
- [26] Halvorson DJ, Kuhn FA. Otolaryngol Head Neck Surg 1996;114(1):113-115.
- [27] Suskind DL, Mirza N, Rosin D, Stanton D, Sachdeva R. Otolaryngol Head Neck Surg 1996;114(3):487-490.
- [28] Miller CS, White DK, Royse DD. Am J Dermatopathol 1993; 15(3):256-259.