



Research Journal of Pharmaceutical, Biological and Chemical Sciences

Simultaneous Fractures of Surgical Neck of Both Humerii in an Old Post- Menopausal Lady.

Kumaravel Shanmugasundaram*.

Department of Orthopaedic Surgery, Government Thanjavur Medical College, Thanjavur, Affiliated to the Tamilnadu Dr MGR Medical University Chennai 32, Tamil Nadu, India.
Orthopaedic Surgeon , National Pharma Hospital and Research Institute , Thanjavur, Tamil Nadu, India.

ABSTRACT

Bilateral fractures are rare occurrences. Simultaneous bilateral proximal humeral fractures are rare. We report the functional outcome in one such even in a post-menopausal female.

Keywords: fractures, post-menopausal, surgical neck

**Corresponding author*

Email: drskumaravel@gmail.com

CASE REPORT

An 80-year-old female fell face down while crossing a threshold in her house. She was conscious throughout this event and afterwards. She had bleeding from her nose. She was not able to get up. She was helped to sit on a chair. She noticed she was not able to move both her shoulders. She was brought to our hospital casualty. She had mild ooze from her nostrils. She was not able to abduct her shoulders. She had X-rays of both upper limbs (shown in figures 1 and 2).

From the clinical presentation and the X-rays she was diagnosed to have simultaneous surgical neck of humerus fractures. She underwent a CT scan of brain and facial bone which showed a fracture of nasal bone. Her CT of both shoulders showed fractures of surgical neck bilaterally. Her blood investigations including electrophoresis were normal. She was treated with bilateral arm slings and nasal Calcitonin spray- Ostospray®. She also had an Otonasolaryngologist opinion who advised conservative treatment for the nasal bone fracture. Functional assessment was done at two years after the initial presentation shown in figures 4 and 5. Her 2 year X-rays taken in abduction shows not only union but also the range of movement available [1-8].

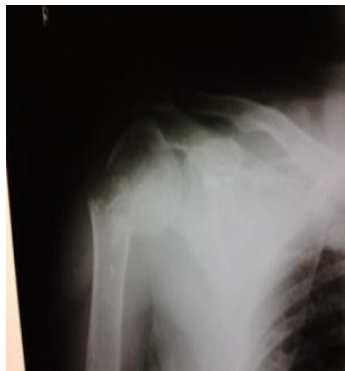

Figure 1: X-ray of the lady's right shoulder showing intact shoulder and fracture of surgical neck of humerus

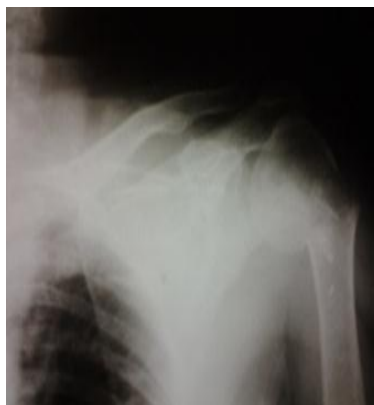

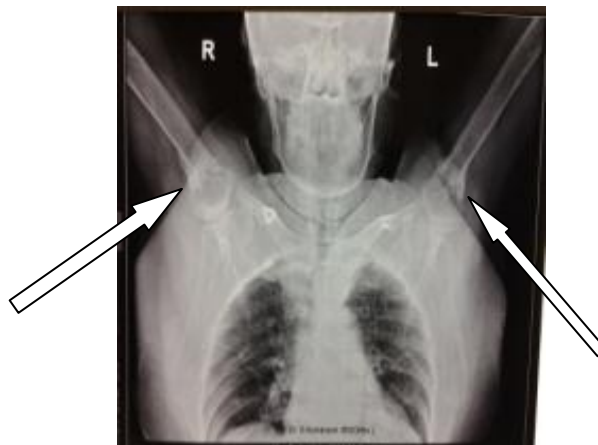
Figure 2: X-ray of the lady's right shoulder showing intact shoulder and fracture of surgical neck



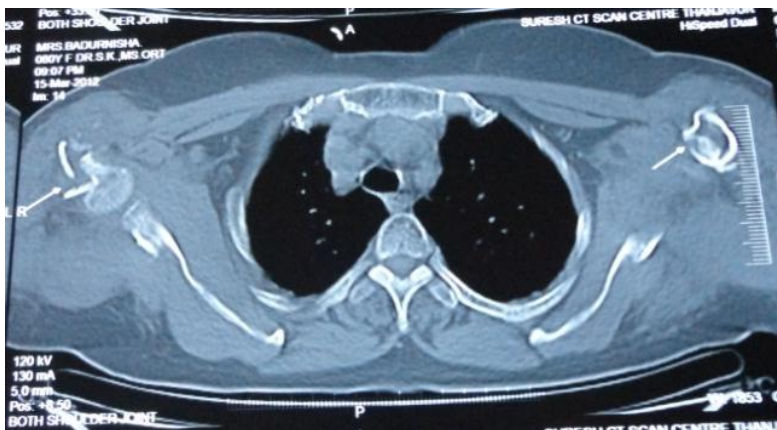
Figures 3: The extent of abduction of both shoulders of the patient at 2 year follow up.



Figures 4: The extent of internal rotation of both shoulders of the patient at 2 year follow up.



Her 2 year X-rays taken in abduction shows not only union marked by arrows but also the range of movement available in both the shoulder joints.



CT scan of both the shoulders showing fractures marked with arrows

DISCUSSION

There were six cases of bilateral proximal humeri fractures reported in literature. Fractures of the anatomical and surgical necks of the humeri were reported in a 53 year old man following convulsions. In another bilateral fractures of the humeral surgical neck in a 62-year-old woman, there was an associated primary biliary cirrhosis causing osteomalacia. Her fractures were treated conservatively with good result. The third case of bilateral proximal humeral fracture had multiple myeloma. Even in such cases of a pathologically weakened bone, bilateral fracture occurrence is rare. In such cases metastases must also be ruled out by radiography, laboratory investigations and sometimes biopsy. Such bilateral fractures are rare and sometimes associated with epilepsy and electrocution. A rare case of bilateral traumatic displaced proximal humerus fractures in a 40 years old man was treated with open reduction and internal fixation with proximal humerus locked plates on both sides and obtained a good functional outcome. In another interesting case report a 56-year-old female fell from stairs and sustained simultaneous bilateral four-part proximal humeral fractures. Open reduction and internal fixation using threaded pins and tension band suture were performed on one side, and shoulder replacement hemi-arthroplasty was required on the other. In a very unusual occurrence simultaneous fractures of both femoral necks and humeral heads totally four fractures was reported in a epileptic woman with multiple metastases from breast cancer after a convulsion.

There are two cases of bilateral fracture with anterior dislocation, which are also rare. First of these is a 42 year old man who had a freak incident with a weight falling over his back. His injury was initially missed due to the 3-part fracture of the proximal humeri fracture associated with the dislocation altering the clinical picture. However it was later identified and treated properly with open reduction and internal fixation through a deltopectoral approach using multiple Kirschner wires resulted in excellent and comfortable range of motion in both shoulders at one-year follow-up. The second of this type of case report is a 30 year old gentleman who had seizures due to alcohol withdrawal, presented after 20 days of osteopath treatment. He was found to have four part fracture on right side and two part fracture on left).

Open reduction and internal fixation with simple T-plate was done on right side and multiple K – wires were used on left side. At one year follow up .the patient had acceptable results. One case of bilateral posterior dislocations in a 59 year old male but with bilateral proximal humerii fractures was also encountered.

CONCLUSION

Bilateral fractures of proximal humerus are rare occurrences. In selected cases of an old unfit patient conservation gives acceptable results.

REFERENCES

- [1] Weeder SD. Radiol 1950;55(5).
- [2] Court-Brown CM, Macnicol MF. Clin Orthop Relat Res 1979;(143):148-50.
- [3] Singh AP, Mahajan S, Singh AP. Can J Surg 2008; 51(4): E95–E96.
- [4] Ellanti P and Harrington P. Case Reports in Orthopedics 2012:Article ID 941829.
- [5] Liebergall M, Mosheiff R, Lilling M. Orthop Rev 1988 ;17(8):819-20.
- [6] Sharma L, Pankaj A, Kumar V, Malhotra R, Bhan S. J Orthop Surg (Hong Kong) 2005;13(3):303-6.
- [7] Sunku N, Kalaiah KG, Marulasidappa P, Gopinath. J Orthop Case Rep 2012 ;2(4):7-9
- [8] Tellisi NK, Abusitta GR, Fernandes R J. Saudi Med J 2004; Vol. 25 (11): 1727-1729.