

Research Journal of Pharmaceutical, Biological and Chemical Sciences

Cinnamon Aqueous Extract Ameliorates Deltamethrin-Induced Hepatotoxicity In Albino Rats.

Nahid A Lamfon*

Consultant Family &Community Medicine, King Abullaziz medical City / National Guard Health Affair / Riyadh.

ABSTRACT

The present work studied the effect of cinnamon aqueous extract on hepatic injury induced by the pyrethroid insecticide, deltamethrin, in albino rats. Treating animals with deltamethrin at a dose level of $1/10$ LD₅₀, 3 days weekly for 6 weeks caused biochemical and histological alterations. Biochemical results revealed significant increase in serum level of ALT, AST and ALP, and decrease in total proteins. Examination of liver sections stained with H&E showed loss of normal structure of the hepatic cells, blood congestion, leucocytic infiltration, cytoplasmic vacuolation of the hepatocytes and fatty degeneration. Treating animals with deltamethrin and cinnamon revealed an improvement in the biochemical and histological changes observed in animals treated with deltamethrin. This effect of cinnamon extract may be attributed to its antioxidant activity.

Keywords: Deltamethrin, Cinnamon, Rats, Transaminases, Liver

**Corresponding author*

INTRODUCTION

Pyrethroids are a group of insecticides that is widely used in agriculture to control insects in vegetables, fruits and field crops. These insecticides are commonly divided into two types: Type I compounds or (T-syndrome pyrethroids), which lack an alphacyano substituent, and Type II compounds or (CS-syndrome pyrethroids), which contain an alpha-cyanophenoxybenzyl substituent (Naumann, 1990). Deltamethrin is a synthetic pyrethroid with potent insecticidal property. Deltamethrin is extensively used as an ectoparasiticide in animals and as insecticide in crop production and in public health programme (Tu et al., 2007). Owing to its rapid metabolism and low toxicity to humans and other non-target animals as well as its high potency on a large number of pests, it has become of choice in most countries (Chargui et al.2012). The insecticidal effects of deltamethrin is believed to result from its binding to a distinct receptor site on voltage-gated sodium channels and prolonging the open state by inhibiting channel deactivation and inactivation (Du et al.2010). Deltamethrin was found to cause different adverse effects in fish, birds and mammals. Abdel-Khalik et al. (1993) reported that treating pregnant rats with deltamethrin caused retardation of growth, hypoplasia of the lungs, dilation of the renal pelvis and increase in placental weight. Deltamethrin was found to cause suppress immune system in Balb/c mice (Lukowicz-Ratajczak and Krechniak 1992). It inhibited the mitotic index and increased the frequency of chromosomal aberrations in the bone marrow of rats (Agarwal et al., 1994). Sakr and Al-Amoudi (2012) reported that deltamethrin induced reproductive toxicity and endocrine disruption in male rats. Deltamethrin treatment has led to hepatorenal degeneration in rats (Abdel-Daim et al.2013).

Plant products have been the basis for many medicinal therapies. *Cinnamon (Cinnamomum verum)* leaves and bark are used extensively as spices in food or to produce essential oils in many countries. *Cinnamon* was used as medicinally and as flavoring for beverages, it was also used in embalming, where body cavities were filled with spiced preservatives. The plant has a hot taste and emits a spicy odor when crushed (Jayaprakasha et al.2003). *Cinnamon* is used to treat nausea and diarrhea and in wound healing (Kamath et al. 2003) and it has anti-bacterial and anti-fungal properties (Nir et al. 2000). It also showed anti-inflammatory (Tung et al., 2008), antioxidant (Su et al., 2007) and hypotensive effect (Preuss et al., 2006). The hepatoprotective of cinnamon was reported by some investigators (Eidi et al. 2012, Sakr and Al-barakati,2014). The purpose of the present work was to study the effect of cinnamon on hepatotoxicity of deltamethrin in albino rats.

MATERIALS AND METHODS

Deltamethrin

Commercial deltamethrin [α -cyano- 3-phenoxybenzyl-(1R, S)-cis, trans-3-(2,2-dibromovinyl) -2,2-dimethylcyclopropanecarboxylate], was used at a dose level of $1/10$ LD₅₀ (5.5 mg/kg b.w.) dissolved in corn oil.

cinnamon aqueous extract

The plant materials were obtained from the local market. Shade dried cinnamon bark was milled and extracted using ethanol 80 % in Soxhlet apparatus for 8 h. Then, the extract was evaporated to dryness and the final dry extract was stored in dark at -20°C until used for the experiments. The powder was dissolved in saline and was given to rats at a dose of 200 mg/kg b.w.

Animals

The present study was performed on Wister albino rats (160±10 g. body weight). Animals were housed in ventilated cages and were maintained under standard conditions with the temperature of 22°C ± 1°C, humidity of 45%, and 12:12 hours light/dark cycle. They were acclimatized for two weeks before treatments. Animals were randomly allocated to four groups of 10 animals:

Group1: Animals of this group were considered as control and were given 0.5 ml corn oil.

Group 2: Animals of this group were orally administrated cinnamon extract at a dose level of 200 mg/kg body weight 5 days / week for 6 weeks.

Group 3: Animal of this group were orally given deltamethrin at a dose level of $1/10$ LD₅₀ (0.6 mg/kg body weight) (Oda and El-Maddawy 2011) in corn oil, 3 days weekly for 6 weeks.

Group 4: Animals in this group were given $1/10$ LD₅₀ of deltamethrin followed by cinnamon extract at a dose level of 200 mg/kg b. w. 5 days / week for 6 weeks.

Histological Study

At the end of the treatment (24 hours after receiving the last treatment dose), animals were sacrificed; then, liver tissue was extracted and fixed in Bouin's solution. After fixation, specimens were dehydrated in an ascending series of alcohol, cleared in two changes of xylene and embedded in molten paraffin. Sections of 5 microns thickness were cut using rotary microtome and mounted on clean slides. For histological examination, sections were stained with Ehrlich's hematoxylin and counterstained with eosin.

Biochemical study

For biochemical study, blood samples were collected in clean dry centrifuge tubes and were left to clot at room temperature, and then centrifuged at 3000 round per minute (rpm) for 20 minutes. The activity of alanine aminotransferase (ALT), aspartate aminotransferase (AST) were determined in the sera according to Reitman and Frankel (1957). Alkaline phosphatase was determined by the method of Kochmar and Mossa (1976). Serum total protein was measured according to Lowry et al., (1951).

Statistical Analysis

Results were expressed as mean values \pm SD and statistical analyses were performed using SPSS statistical version 16 software package (SPSS® 4 Inc., USA). The criterion for statistical significance was set at $P < 0.05$.

RESULTS

Histological results

Examination of liver sections of control rats stained with H&E showed a normal histological structure (Fig.1a). Liver sections of rats treated with cinnamon extract either for 3 or 6 weeks did not show any histological change and normal hepatic architecture with normal hepatocytes was observed. Liver sections of rats treated with deltamethrin for 3 weeks revealed that most of the hepatic vessels, central and portal veins, were congested (Fig.1b). Masses of inflammatory cells, lymphocytes, eosinophils and neutrophils were scattered all over the tissue (Fig.1c). Many hepatocytes showed cytoplasmic vacuolation with pyknotic nuclei (Fig.2a). Liver sections obtained from animals treated with deltamethrin for 6 weeks showed many histopathological alterations. In these specimens, a large number of hepatocytes showed cytoplasmic vacuolization and masses of inflammatory cells were abundant. Fatty degeneration was recognized as scattered fat droplets in many areas of the liver (Fig.2b). After 3 & 6 weeks of combined treatment with deltamethrin and cinnamon, liver sections of rats revealed mild changes, but the hepatocytes appeared normal (Fig. 2c).

Biochemical results

Data in figure 3 showed that ALT increased significantly ($p < 0.05$) in sera of rats treated with deltamethrin for 6 weeks in comparison with controls. Insignificant increase was recorded in animals given deltamethrin and cinnamon extract. Meanwhile, there was significant increase in AST and ALP in sera of rats treated with deltamethrin (Figs.4&5). Treating animals with deltamethrin and cinnamon restored the values of these enzymes to normal values. Concerning the change in total proteins, animals administered with deltamethrin showed a significant decrease in serum proteins in comparison with controls (Fig.6). On the other hand, an increase in total proteins was observed in animals treated with deltamethrin and cinnamon.

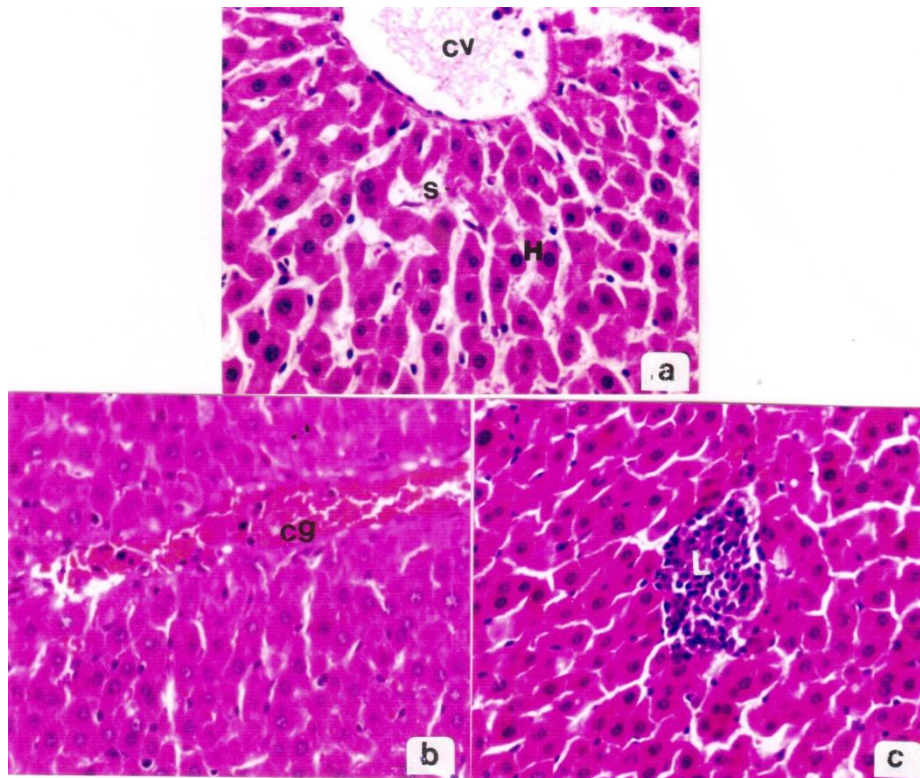


Figure 1: a. liver section of a control rat showing hepatic lobule formed of cords of hepatocytes (H), central vein (CV and sinusoids (S),
 b. liver section of a rat treated with deltamethrin for 3 weeks showing congested and enlarged central vein (cg) ,
 c. liver section of a rat treated with deltamethrin showing mass of inflammatory cells (L), (X400).

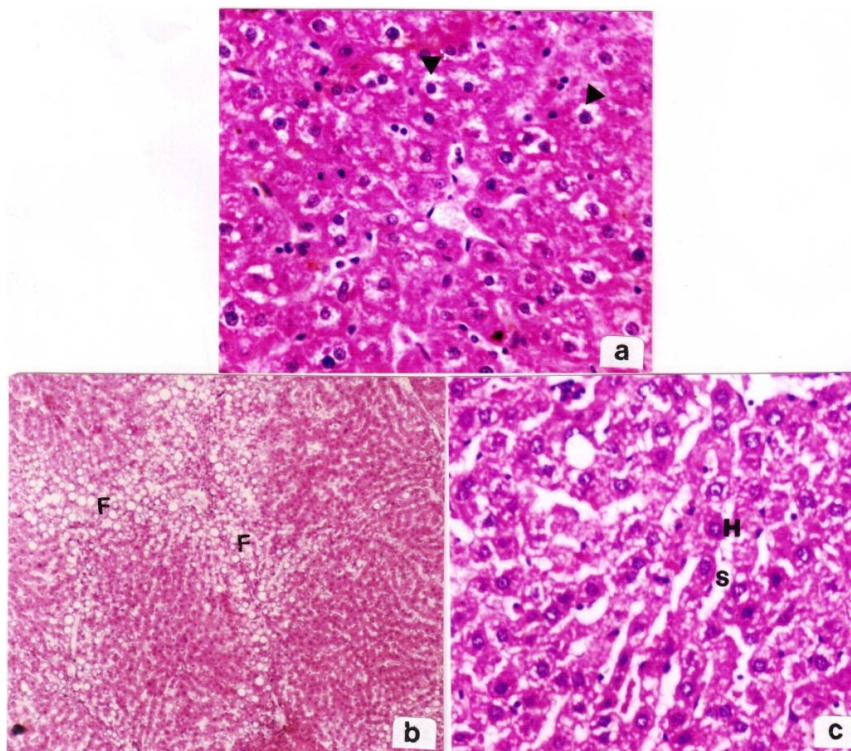


Figure 2: a. liver section of a rat treated with deltamethrin for 6 weeks showing cytoplasmic vacuolation (arrow head),
 b. liver section of a rat treated with deltamethrin for 6 weeks showing Fatty degeneration (F),
 c. liver section of a rat treated with deltamethrin+cinnamon showing normal hepatocytes, and wide sinusoids (S), (H&E, X 400)

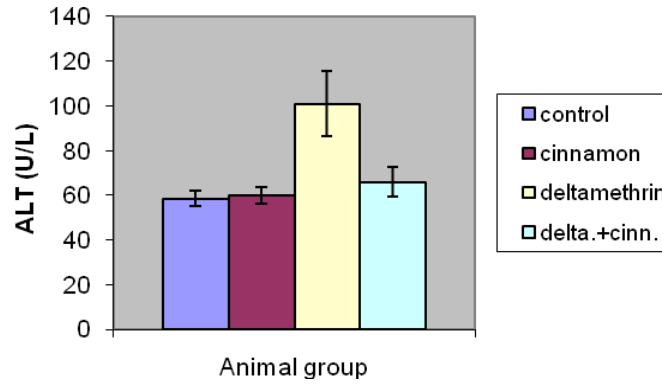


Figure 3: Change of ALT in different animal groups

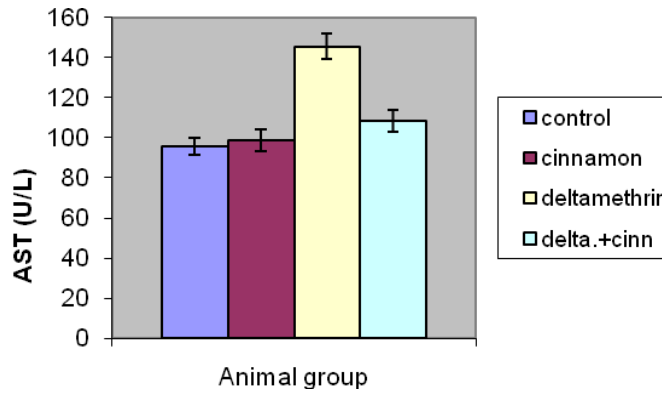


Figure 4: Change of AST in different animal groups

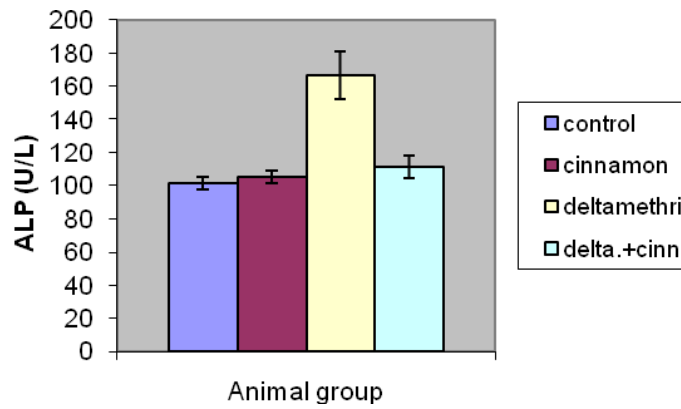


Figure 5: Change of ALP in different animal groups

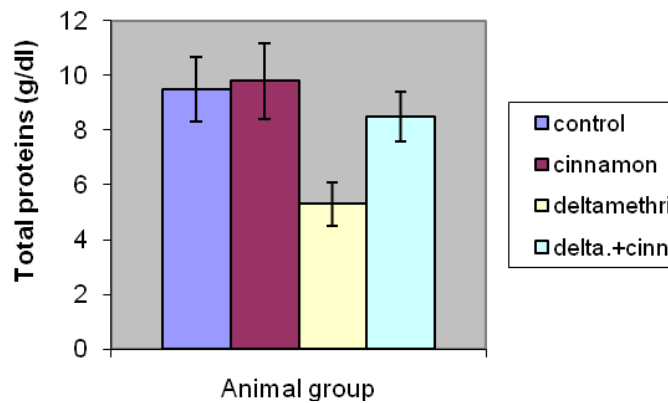


Figure 6: Change of total proteins in different animal groups

DISCUSSION

Liver play an important role in the detoxification process and face the threat of maximum exposure to xenobiotics and their metabolic by-products. The present results showed that exposing rats to deltamethrin induced biochemical and histological in the liver. Concerning the histological changes, the liver showed congestion of blood vessels, leucocytic infiltrations, cytoplasmic vacuolation of the hepatocytes and fatty degeneration. Similar results obtained by Abdel-Daim et al.(2013) who observed loss of hepatic architecture and hydropic degeneration as well as renal tubular deformities in rats exposed to deltamethrin. Other investigators reported many histopathological alterations in liver of animals exposed to deltamethrin (El-Sayed et al.2007, Chargui et al.2012).

Biochemical results showed an increase in serum level of ALT,AST and ALP in rats treated with deltamethrin. In agreement with these results, Chargui et al.(2012) reported elevation in these enzymes after exposure to deltamethrin. These enzymes leak out from the damaged hepatocytes into the blood stream in abnormal amounts and are considered as indicators of liver damage. Reduction in serum total proteins was recorded in rats administered with deltamethrin. Gomes *et al.*, (1999) reported that the reduction in proteins may be resulted from an impairment of hepatocytes and a decrease in amino acid availability and/or in hepatic protein capability would reduce the total serum concentration.

The mechanisms of the organophosphates toxicity have been reported. organophosphates act by inhibiting of acetylcholinesterase, leading to accumulation of acetylcholine and subsequent activation of cholinergic, muscarinic and nicotinic receptors (Ecobichon, 1996). Organophosphorus insecticides toxicity may takes place through electrophilic attack on the cellular constituents of hepatic and brain tissues (Samanta and Chainy, 1995) with simultaneous generation of reactive oxygen species (Sharma *et al.*, 2005). Reactive Oxygen Species have been implicated in hepato and neurotoxicity induced by several organophosphorus (Bagchi *et al.*, 1995; Mansour and Mossa, 2009). Deltamethrin was found to generate reactive oxygen species (ROS) and result in oxidative stress in intoxicated animals. El-Gohary et al., (1999) reported the deltamethrin induced lipid peroxidation and nitric oxide production in plasma of rats. Li et al.(2011) reported that deltamethrin increased free radical production in brain of rats. Deltamethrin treatment increased lipid peroxidation through elevated hepatic and renal MDA level, decreased hepatic and renal enzymatic; SOD and CAT as well as non-enzymatic; GSH antioxidant level (Abdel-Daim et al. 2013). It is suggested that hepatotoxicity induced by deltamethrin is the result of oxidative stress that arise as a result of excessive generation of ROS.

The present results showed that cinnamon extract ameliorates the biochemical and histopathological alterations induced by deltamethrin in rats. These findings are in accordance with the result of Moselhy and Ali (2009) who reported that the livers of CCl₄-intoxicated rats showed massive fatty changes, necrosis, broad infiltration of the lymphocytes and increase in serum ALT and AST. The ethanolic extract induced suppression of increased ALT and AST activities. They added that administration of ethanolic or aqueous extracts of cinnamon revealed hepatoprotective activity against the toxic effect of CCl₄, which is also supported by histological studies. Eidi et al.(2012) found that pretreatment with the cinnamon extract markedly reversed hepatotoxicity caused by the CCl₄ as indicated by decrease of transaminases and increase of total proteins. Sheng et al.(2008) reported that high serum cholesterol level increased AST and ALT in mice and 3 weeks of *cinnamon* treatment significantly decreased their levels suggesting that *cinnamon* may play an important role in improving liver function. Amin and Abd El-Twab .(2009) reported that hypercholesterolemia can cause liver damages and treating for 6 weeks with *cinnamon* caused amelioration in the activity of ALT and AST.

Numerous studies have showed that cinnamon extracts commonly function as antioxidants. Murcia et al., (2004) reported that cinnamon extracts exhibit a protective capacity against irradiation induced lipid peroxidation in liposomes, and quench hydroxyl radicals and hydrogen peroxide. Ethanolic extract of cinnamon has potent hepatoprotective action against CCl₄ by lowering the MDA level and elevating antioxidants enzymes activities (SOD and CAT)(Moselhy and Ali,2009). Extracts of cinnamon bark has revealed the presence of flavonoids, glycosides, coumarins, alkaloids, anthraquinone, steroids, tannins and terpenoids (Shihabudeen et al., 2011). It is suggested in this work that the hepatoprotective of cinnamon aqueous extract is attributed to its antioxidant effects of flavenoids comoponents.

REFERENCES

- [1] Abdel-Daim MM, Abuzead SMM, Halawa SM (2013). Protective Role of *Spirulina platensis* against Acute Deltamethrin-Induced Toxicity in Rats. PLOS ONE 8(9): e72991. doi:10.1371/journal.pone.0072991
- [2] Abdel-Khalik MM, Hanafy MS and Abdel-Aziz MI (1993). Studies on the teratogenic effects of deltamethrin in rats. DtschTierarztlWochenschr. 100; (4):142-3.
- [3] Agarwal DK, Chauhan LK, Gupta SK and Sundararaman V (1994). Cytogenetic effects of deltamethrin on rat bone marrow. Mutat Res. 311(1):133-8.
- [4] Amin, K.A., Abd El-Twab, T.M. (2009). Oxidative markers, nitric oxide and homocysteine alteration in hypercholesterolemic rats: role of atorvastatine and *cinnamon*. Int J Clin Exp Med , 2:254-265
- [5] Bagchi, D., M. Bagchi, E.A. Hassoun and S.J. Stohs, (1995). In vitro and *in vivo* generation of reactive oxygen species, DNA damage and lactate dehydrogenase leakage by selected pesticides. Toxicology, 104: 129-140.
- [6] Chargui I, Grissa I, Bensassi F, Hrira MY, Haouem S, (2012). Oxidative stress, biochemical and histopathological alterations in the liver and kidney of female rats exposed to low doses of deltamethrin (DM): a molecular assessment. Biomed Environ Sci 25: 672–683.
- [7] Du Y, Song W, Groome JR, Nomura Y, Luo N, et al. (2010). A negative charge in transmembrane segment 1 of domain II of the cockroach sodium channel is critical for channel gating and action of pyrethroid insecticides. Toxicol Appl Pharmacol 247: 53–59.
- [8] Ecobichon, D.J., (1996). Toxic Effects of Pesticides. In: Casarett and Doull's Toxicology, Klassen, C.D. (Ed.). McGraw-Hill, New York, pp: 643-698.
- [9] Eidi,A., Mortazavi, P., Bazargan,M., Zaringhalam,J (2012). Hepatoprotective activity of cinnamon ethanolic extract against ccl₄-induced liver injury in rats. EXCLI Journal 11:495-507
- [10] El-Gohary M, Awara WM, Nassar S and Hawas S (1999). Deltamethrin-induced testicular apoptosis in rats: the protective effect of nitric oxide synthase inhibitor. Toxicology. 132(1):1-8.
- [11] El-Sayed YS, Saad TT, El-Bahr SM (2007). Acute intoxication of deltamethrin in monosex Nile tilapia, *Oreochromis niloticus* with special reference to the clinical, biochemical and haematological effects. Environ Toxicol Pharmacol 24: 212–217.
- [12] Gomes, J., A.H. Dawodu, O. Lloyd, D.M. Revitt and S.V. Anilal, (1999). Hepatic injury and disturbed amino acid metabolism in mice following prolonged exposure to organophosphorus pesticides. Hum. Exp. Toxicol., 18 .33-37.
- [13] Jayaprakasha GK, Rao LJ, Sakaraiah KK.(2003). Volatile constituents from *Cinnamomum zeylanicum* fruit stalks and their antioxidant activities. Journal of Agriculture and Food Chemistry; 51: 4344-4348.
- [14] Kamath, J., Rana, A., Chowdhury A. (2003). Pro-healing effect of *cinnamon zeylanicum* bark. Phytotherapy Research, 18(8): 970-972.
- [15] Kochmar, J. and D. Mossa, (1976). Fundamental of Clinical Chemistry. 1st Edn., W.B. Saunders Company Philadelphia.
- [16] Li HY, Wu SY, Ma Q, Shi N (2011). The pesticide deltamethrin increases free radical production and promotes nuclear translocation of the stress response transcription factor Nrf2 in rat brain. Toxicol Ind Health 27: 579–590
- [17] Lowry OH, Rosebrough NJ, Farr AL, Randall RJ (1951). Protein measurement with the Folin phenol reagent. J Biol Chem 193: 265–275.
- [18] Lukowicz-Ratajczak J and Krechniak J (1992). Effects of deltamethrin on the immune system in mice. Environ Res. 59 (2):467-75.
- [19] Mansour, S.A. and A.H. Mossa, (2009). Lipidperoxidation and oxidative stress in rat erythrocytes induced by chlorpyrifos and the protective effect of zinc. Pesticides Biochem. Physiol., 93: 34-39.
- [20] Moselhy,S.S. and Ali,H.H. (2009). Hepatoprotective effect of Cinnamon extracts against carbon tetrachloride induced oxidative stress and liver injury in rats. Biol Res 42: 93-98.
- [21] Murcia, M. A., Egea, I., Romojaro, F., Parras, P., Jimenez, A. M., & Martinez-Tome, M. (2004). Antioxidant evaluation in dessert spices compared with common food additives. Influence of irradiation procedure. Journal of Agricultural and Food Chemistry, 52: 1872-1881.
- [22] Naumann K (1990) Synthetic pyrethroid insecticides :Structures and properties. Chemistry of Plant Protection, Springer-Verlag, Berlin, Germany.
- [23] Nir, Y.; I. Potasman,I.; Stermer,E.; Tabak,M.; Neeman,I. (2000). Controlled trial of the effect of cinnamon extract on *Helicobacter pylori*. Helicobacter., 5(2): 94-97.

- [24] Oda SS and El-Maddawy ZK (2011) Protective effect of vitamin E and selenium combination on deltamethrin induced reproductive toxicity in male rats. *Exp Toxicol Pathol.* 64 (6-8): 813-819
- [25] Preuss H.; Echard B.; Polansky M.; Anderson R.(2006). Whole cinnamon and aqueous extracts ameliorate sucrose induced blood pressure elevations in spontaneously hypertensive rats. *J Am Coll Nutr*;25:144- 50.
- [26] Reitman, S. and Frankel, S. (1957). A colorimetric method for the determination of serum glutamic oxalacetic and glutamic pyruvic transaminases. *Am. J. Clin. Pathol.* 28(1): 56-63.
- [27] Sakr, S.A. and Al-Amoudi, W.M. (2012). Effect of ginger extract on deltamethrin induced histomorphological and immunohistochemical changes in testes of albino rats. *Life Science Journal* 9(1):771-778
- [28] Samanta, L. and G.B. Chainy, (1995). Hexachlorocyclohexane-induced changes in lipid peroxidation, superoxide dismutase and catalase activities and glutathione content in chick liver. *Ind. J. Exp. Biol.*, 33: 131-133.
- [29] Sakr,S.A. and Al-barakati, A.Y.(2014). Effect of cinnamon on cypermethrin-induced nephrotoxicity in albino rats. *Int.J. Adv. Res.* 2(7):578-586.
- [30] Sharma, Y., S. Bashir, M. Irshad, S.D. Gupta and T.D. Dogra, (2005). Effects of acute dimethoate administration on antioxidant status of liver and brain of experimental rats. *Toxicology*, 20: 49-57
- [31] Sheng X, Zhang Y, Gong Z, Huang C, Zang YQ.(2008). Improved Insulin Resistance and Lipid Metabolism by Cinnamon Extract through Activation of Peroxisome Proliferator Activated Receptors. *PPAR Research*; 2008: 581348.
- [32] Shihabudeen, M.; Priscilla H.; Thirumurugan K. (2011). Cinnamon extract inhibits glucosidase activity and dampens postprandial glucose excursion in diabetic rats. *Nutr Metab* 2011;8:1-11.
- [33] Su, L.; Yin J.; Charles D.; Zhou K.; Moore J.; Yu L. (2007). Total phenolic contents, chelating capacities, and radical-scavenging properties of black peppercorn, nutmeg, rosehip, cinnamon and oregano leaf. *Food Chem*;100:990-7.
- [34] Tu H.T, Silvestre F, Bernard A, Douny C, Phuong N.T, Tao CT, Maghuin-Rogister G and Kestemont P (2007). Oxidative stress response of black tiger shrimp (*Penaeus monodon*) to enrofloxacin and to culture system. *Aquaculture*, 285: 244–24.
- [35] Tung, Y.; Chua M.; Wang S.; Chang S. (2008). Antiinflammation activities of essential oil and its constituents from indigenous cinnamon (*Cinnamomum osmophloeum*) twigs. *Bioresour Technol*;99:3908-13.