

# Research Journal of Pharmaceutical, Biological and Chemical Sciences

## Endoscopic Drainage of the Pancreatic Pseudocyst through the Stomach or Duodenal Wall.

**Vladimir Fedorovich Kulikovskiy, Alexander Aleksandrovich Karpachev, Alexander Valentinovich Soloshenko, Andrey Leonidovich Iarosh, Sergey Borisovich Nikolaev, Sergey Pavlovich Francev, Alexander Michailovich Mishustin, Ekaterina Pavlovna Bitenskaya, Yurii Yurievich Vlasuk, and Marina Alexandrovna Kolesnikova.**

Federal Autonomous Educational Establishment for Higher Vocational Education Belgorod State National Research University, 85, Pobedy St., Belgorod, 308015, Russia.

### ABSTRACT

In the article we have presented early outcome and long-term outcome of the usage of various methods of endoscopic drainage of the pancreatic pseudocyst through the stomach or duodenal wall in 56 patients. High efficiency of internal drainage of the cyst fluid through the stent, placed between the pseudocyst and the gastric lumen (cystogastrostomy) or between the pseudocyst and the duodenal lumen (cystoduodenostomy) has been shown. The procedure was technically successful in 100% cases. Postoperative infection of the cyst fluid occurred in 4 patients. Other complications (like bleeding, stent clogging or migration, iatrogenic perforation et al. were not detected). No mortality was observed.

**Keywords:** Endoscopic interventions, cystogastrostomy, cystoduodenostomy.

*\*Corresponding author*

## INTRODUCTION

Within the recent decade an evident tendency of substitution of surgeries on pancreas and its annexa with minimally invasive surgical procedures can be observed. Currently endoscopic drainage is becoming more and more popular as an alternative to surgical or percutaneous drainage of pancreatic pseudocysts [1, 2, 3, 4, 5, 6]. Ultrasound-guided endoscopic drainage of the pancreatic pseudocyst through the stomach or duodenal wall has become a standard and safe procedure in many clinics and medical centers, which can provide a safe puncture avoiding intervening blood vessels [7, 8, 9, 10]. Effectiveness of the usage of this method is high, though, the number of specific complications (such as bleeding, infection, stent clogging or migration, iatrogenic perforation et al.) may reach 25%, and the number of recrudescences – up to 10.9%; no mortality was observed [7]. In this research we have presented our expertise in using endoscopic interventions procedures while treating pancreatic pseudocysts.

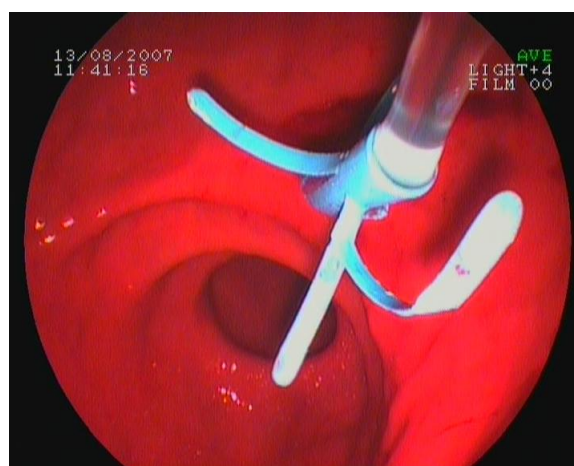
## THE METHOD

In this work we have presented our expertise in treatment of pancreatic pseudocysts in 56 patients that were receiving medical treatment in our clinic in 2000-2013. Endoscopic interventions for pancreatic pseudocyst management consist of: endoscopic drainage of the pancreatic pseudocyst through the stomach or duodenal wall –transluminal cystogastrostomy (CGS) or cystoduodenostomy (CDS)) – 30 cases; transluminal cystogastrostomy or cystoduodenostomy with the usage of single plastic stents (CGAst or CDAst) – 19 cases; transpapillary pancreatic duct stent – 3 cases; transluminal nasocystic drainage – 9 cases. The reasons of cysts' formation were the following: in 53 cases – acute pancreatitis (6 – gallstone pancreatitis, 47 - alcoholic pancreatitis), in 3 cases – trauma of pancreas. In all cases cysts' localization was limited by pancreatic head or body.

## THE MAIN PART

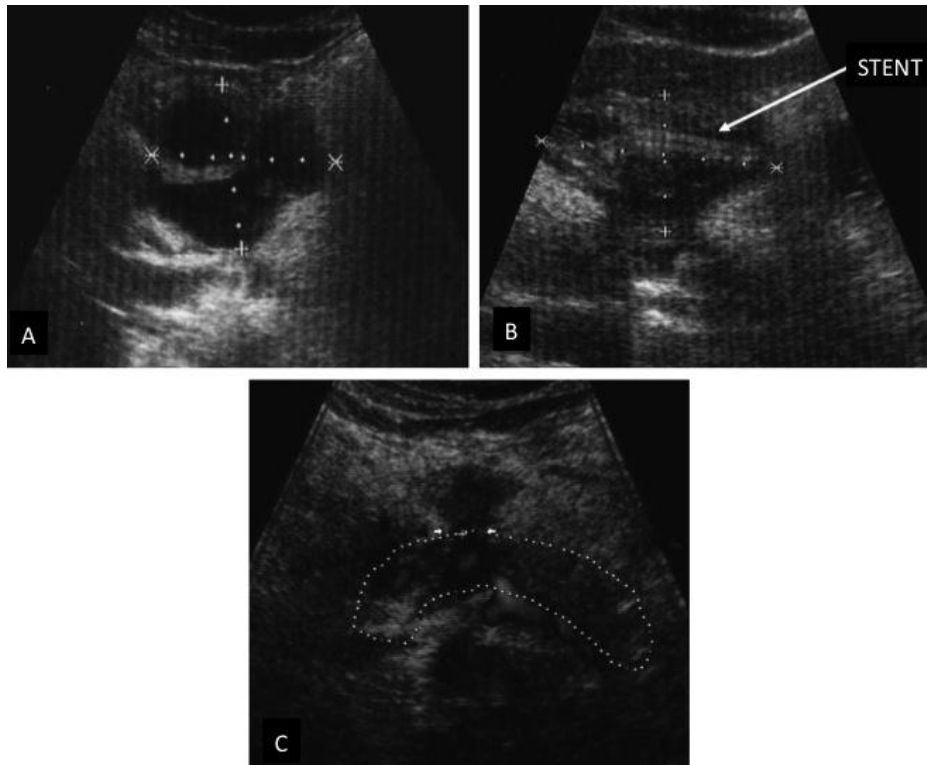
Before 2006, after finding pancreatic pseudocysts, we performed CGS or CDS. The size of created fistulas equaled up to 1.5-2.0 cm. We performed cystoradiography and defined the connection of the cyst with main pancreatic duct. While using this method, we faced the following problems: high risk of hemorrhage, low effectiveness of drainage, reflux of stomach and duodenum content into cyst's atrium and infections. In one case of infected pseudocyst CGS with nasocystic drainage was performed. In two patients (in 3 and 11 days, respectively) with infection and absence of effect from CGS, additionally ultrasound-guided percutaneous drainage was performed. CGS or CDS had no effect on two patients. In these cases surgery operations were performed.

Considering all abovementioned limitations of transluminal CGS or CDS, within the recent years we have started to perform transluminal CGSst or CDSst (Picture 1).



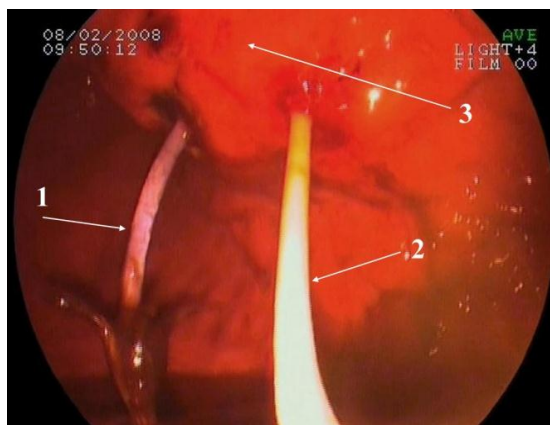
Picture 1: Transluminal cystogastrostomy with the usage of single plastic stent.

When control ultrasound investigation was performed in 3 months after the procedure had been taken, no residual cyst cavities were observed (Picture 2).



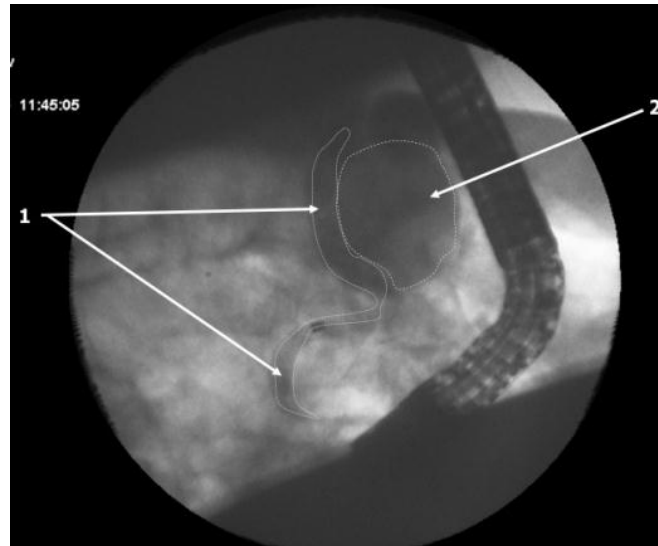
**Picture 2: Ultrasonography (A – before CGSst was performed; B – in two days after CGSst was performed; C – in 3 months CGSst was performed).**

In 4 cases in 3-4 days after the operation cyst's infection contamination occurred. This patient performed transluminal nasocystic drainage (Picture 3). In other 4 cases the main indication for the performance of CGSst combined transluminal nasocystic drainage were gigantic sizes of pseudocyst (20-30 cm).



**Picture 3: CGSst combined transluminal nasocystic drainage (1 – stent, 2 – cystonasal drainage; 3 – posterior wall of stomach).**

In one case on the 4<sup>th</sup> day after CGSst had been performed, subject to the existence of cyst's infection contamination, ultrasound-guided percutaneous drainage was performed. In three cases at endoscopic retrograde cholangiopancreatography (ERCP) connection of cyst with main pancreatic duct was defined (Picture 4). These patients had their transpapillary pancreatic ducts stented.



**Picture 4: ERCP. The dilated main pancreatic duct (1), pseudocyst (2).**

Within several months after performing of CGSst with or without transpapillary pancreatic duct stent and transluminal nasocystic drainage in all cases cysts' size decreased. In 180 days at control ultrasound investigation no cysts were found.

#### CONCLUSION

Thus, performance of CGSst at pancreatic cysts allowed avoiding the development of post-operational hemorrhages. However, we faced serious complication in the form of post-operational infection of cyst. This situation required performance if additional operative measures: transluminal nasocystic drainage or ultrasound-guided percutaneous drainage. Analysis of direct and remote results showed that CGSst is characterized with ease of performance and more safety, since there were no cases of hemorrhages. CGSst provides adequate internal drainage of cyst regardless of thickness and density of cyst sac and presence of blood vessels in operational area.

#### SUMMARY

We have demonstrated high efficiency of internal drainage of the cyst fluid through the stent, placed between the pseudocyst and the gastric lumen or between the pseudocyst and the duodenal lumen. This procedure was technically successful in 100% of cases. Postoperative infection of the cyst fluid occurred in 4 patients. Other specific complications (like bleeding, stent clogging or migration, iatrogenic perforation et al.) were not observed. There was no mortality.

#### REFERENCES

- [1] Mukai, S., T. Itoi, F. Moriyasu., 2014. Interventional endoscopy for the treatment of pancreatic pseudocyst and walled-off necrosis (with videos). *J Hepatobiliary Pancreat Sci.* Aug 20. doi: 10.1002/jhbp.146.
- [2] Due, S.L., T.G. Wilson, A. Chung, J.W. Chen., 2014. Endoscopic cyst-gastrostomy for pancreatic pseudocysts: refining the indications. *ANZ J Surg.* May 7. doi: 10.1111/ans.12648.
- [3] Mukai, S., T. Itoi, A. Sofuni, F. Itokawa, T. Kurihara, T. Tsuchiya, K. Ishii, S. Tsuji, N. Ikeuchi, R. Tanaka, J. Umeda, R. Tonzuka, M. Honjo, T. Gotoda, F. Moriyasu, 2014. Expanding endoscopic interventions for pancreatic pseudocyst and walled-off necrosis. *J Gastroenterol.* Apr 24.
- [4] Varadarajulu, S., J.Y. Bang, B.S. Sutton, J.M. Trevino, J.D. Christein, C.M. Wilcox, 2013. Equal efficacy of endoscopic and surgical cystogastrostomy for pancreatic pseudocyst drainage in a randomized trial. *Gastroenterology.* 145:583–590.
- [5] Baron, T.H., 2008. Endoscopic drainage of pancreatic pseudocysts. *J Gastrointest Surg.* 12:369–372.

- [6] Baron, T.H., W.G. Thaggard, D.E. Morgan, R.J. Stanley, 1996. Endoscopic therapy for organized pancreatic necrosis. *Gastroenterology*. 111:755–764.
- [7] Ng, P.Y., D.N. Rasmussen, P. Vilmann, H. Hassan, V. Gheorman, D. Burtea, V. Surlin, A. Săftoiu., 2013. Endoscopic Ultrasound-guided Drainage of Pancreatic Pseudocysts: Medium-Term Assessment of Outcomes and Complications. *Endosc Ultrasound*. Oct;2(4):199-203. doi: 10.4103/2303-9027.121245.
- [8] Wen, J., H. Liang, F.C. Cai, E. Q. Linghu, Y. S. Yang., 2014. Effectiveness and safety of endoscopic ultrasound-guided transgastric or transpapillary drainage in treating pancreatic pseudocyst. *Zhongguo Yi Xue Ke Xue Yuan Xue Bao*. Apr;36(2):194-7. doi: 10.3881/j.issn.1000-503X.2014.02.015.
- [9] Kahaleh, M., V.M. Shami, M.R. Conaway et al., 2006. Endoscopic ultrasound drainage of pancreatic pseudocyst: a prospective comparison with conventional endoscopic drainage. *Endoscopy*. 38:355–359.
- [10] Varadarajulu, S., C.M. Wilcox, A. Tamhane, M.A. Eloubeidi, J. Blakely, C.L. Canon., 2007. Role of EUS in drainage of peripancreatic fluid collections not amenable for endoscopic transmural drainage. *Gastrointest Endosc*. 66:1107–1119.