

Research Journal of Pharmaceutical, Biological and Chemical Sciences

Treatment of Chronic Elbow Dislocation in a 3 Staged Technique.

S Sri Krishna Sandeep*, R Balaraman, R Sathish Kumar, V Vijayanarasimhan, and A Sivakumar.

Department of Orthopaedics Sree Balaji Medical College, Chennai, Tamil Nadu, India.

ABSTRACT

Chronic dislocation of the elbow is an exceedingly disabling condition associated with severe instability, limitation of elbow function and significant pain. Due to the potentially conflicting goals of restoring elbow stability and regaining a satisfactory arc of motion, successful treatment is a challenge for the experienced trauma surgeon. We report our treatment strategy in two patients suffering from chronically unreduced dislocations of the elbow. The treatment protocol consists of in situ neurolysis of the ulnar nerve, distraction of the joint using unilateral Orthofix LRS external fixation, followed by open reduction of the joint and transarticular Kirschner wires and post operative mobilization and physiotherapy after wire removal. A stable elbow was achieved in both patients, without the need of release or reconstruction of the collateral ligaments. At final followup, the average range of movements is 0 - 120° (125 & 115°).

Keywords: Chronic elbow dislocation, limb reconstruction system (LRS), distraction, neurolysis of ulnar nerve, transarticular Kirshner wires, mobilization

**Corresponding author*

INTRODUCTION

Dislocation of the elbow is a common orthopaedic injury with an incidence of approximately 20% of all articular dislocations [1]. After the shoulder, the elbow is the second most frequently dislocated major joint in adults [2] and the most frequently dislocated major joint in the paediatric population [3]. At least 80% of elbow dislocations are posterior or posterolateral [4, 5], resulting in most cases from a fall on the outstretched hand with the forearm pronated. Lateral, postero-medial, medial, or anterior and divergent dislocations (characterized by displacement of the radius from the ulna) are much less common. Neurovascular complications occur in 5–13% of elbow dislocations and include injury to the ulnar, median and, less frequently, radial nerves and the brachial artery, in most cases in open dislocations or penetrating injuries [5, 6].

Fortunately most elbow dislocations do not have concomitant fractures, and are termed 'simple dislocations'[5]. Dislocations associated with fractures of the coronoid process, radial head or neck, distal humerus, or olecranon are termed 'complex dislocations'. These injuries usually require surgery to restore the osseous stabilizers of the elbow joint. Neglecting elbow dislocations, incomplete examination and assessment of elbow instability, or inadequate therapy may lead to chronic dislocation of the elbow. This exceedingly disabling condition is generally associated with severe instability, limitation of elbow function and significant pain. If the elbow is not reduced, there will be ligament and capsule contractures, biceps and triceps muscle contractures, heterotopic ossification and arthritic changes may develop rapidly [7]. The main goals of therapy, to restore a stable, concentric joint and regain a satisfactory arc of motion, are apparently conflicting, so successful treatment of chronic elbow dislocations is a challenge.

In the present study, we present a successful treatment protocol of chronically unreduced elbow dislocation which consists of neurolysis of ulnar nerve, Orthofix LRS hinged elbow external fixation and distraction, open reduction and transarticular Kirshner wires fixation and post operative mobilization and physiotherapy after the wire removal as a 3 staged procedure.

MATERIALS AND METHODS

We report the treatment of two male patients suffering from chronic unreduced dislocation of elbow. The average duration of unreduced elbow dislocation was 18 weeks (20 weeks and 16 weeks).

Patient 1 is a 39 year old man who met with a road traffic accident and sustained a posterolateral dislocation of left elbow 20 weeks back. He had refused any form of orthopaedic treatment and had undergone treatment by a native bone setter in the form of bamboo splints, 4 times reapplied over a period of 16 weeks. After removal of the splint, he had deformity and stiffness of the elbow. He had presented to us, and the 3 point bony relationship was altered, elbow instability present, no active movements were presented. Range of passive movements was 30 – 50° (Fig 1). Anteroposterior and lateral radiographs showed posterolateral dislocation of the elbow (Fig 2).

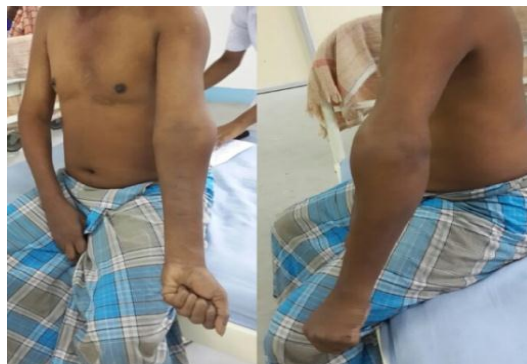

Figure 1: clinical photograph showing chronic dislocation of left elbow

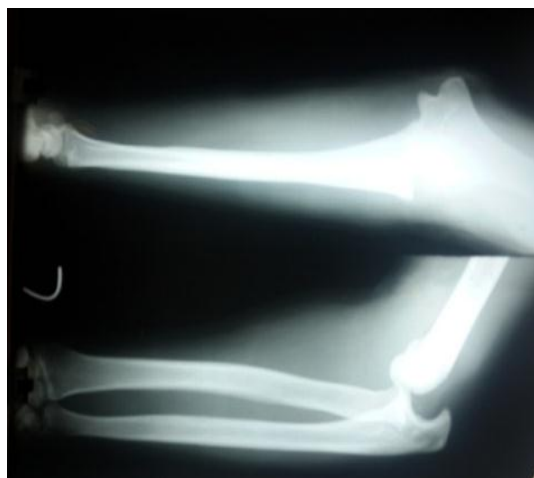

Figure 2: Anteroposterior and lateral radiographs of patient 1 demonstrating chronic posterolateral elbow dislocation 20 weeks after the injury.

Patient 2 is a 68 year old man who fell on his outstretched left hand and sustained injury to left elbow 16 weeks back. No specific treatment was taken by the patient. He was unable to move the left elbow and was not able to use the left upper limb since the injury. He had presented to our outpatient department. The 3 point bony relationship was altered, elbow instability present and no active movements were possible. Passive movements of 15 – 30° were present. Antero posterior and lateral radiographs showed chronic unreduced posterolateral elbow dislocation (Fig. 3)

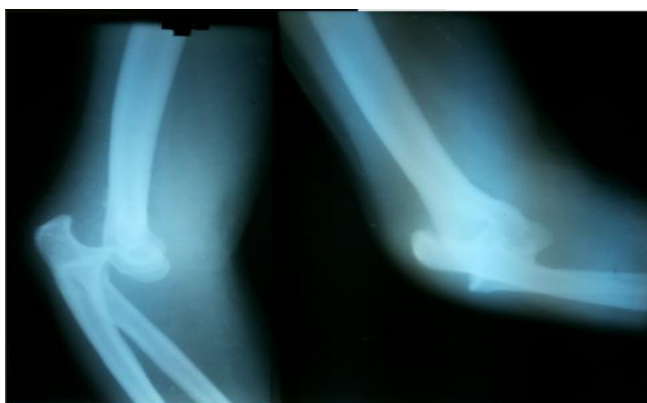

Figure 3: Anteroposterior and lateral radiographs of patient 2 demonstrating chronic elbow dislocation 12 weeks after the injury

Our protocol for management for both the patients was same and consisted of the following procedures:

Stage 1:

Initially, in situ neurolysis of the ulnar nerve was performed between the arcade of Struthers and the Osborne fascia, using a curved incision over the cubital tunnel and after cutting the medial fascia. In the same sitting, application of hinged humero-ulnar fixator with motion capacity (Limb Reconstruction system, (Fig. 4) was done. The application technique of the Orthofix® external fixator is described in detail elsewhere [39, 40]. Gradual distraction was done starting from the 2nd post operative day at the rate of 1mm done 4 times over a period of 24 hours (4mm / day) carried out for a period of 15 days. Pin site care was performed with a proprietary antiseptic and regular dressing of the wound weekly once done (Fig 5&6).




Figure 4: showing the Limb Reconstruction System (LRS) which was used

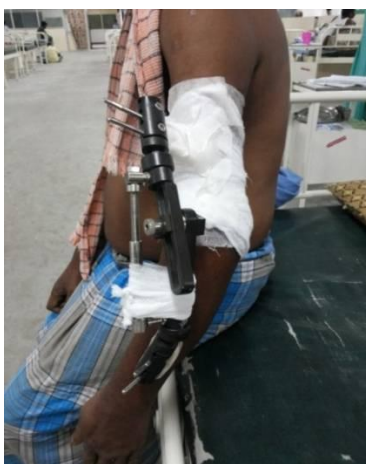

Figure 5: showing the LRS in situ in the process of distraction of the elbow joint

Stage 2:

After 2 weeks of the 1st procedure, patient was posted for open reduction through a midline posterior incision and Vshaped cut of the triceps done.

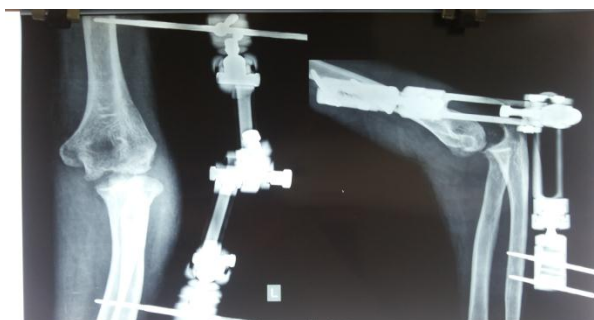

Figure 6: Anteroposterior and lateral radiograph showing the LRS in situ

Intraoperatively, there was extensive heterotopic fibrous tissue and hypertrophied fat at the articular surfaces in both the cases which were removed. Open reduction by pushing the olecranon process the joint could be reduced easily. Trans articular Kirschner wires were passed for maintenance of the reduction. Triceps sutured and wound closed with suction drain (Fig 7). The wires were left in place for a period of 2 weeks during which

regular dressing of the wound sites and pin sites were done. The suction drain was removed on 2nd post operative day.

Stage 3:

2 weeks later, the wires were removed and the patient was started on physiotherapy and mobilisation with the external fixator in situ (Fig 8). 2 weeks later, the external fixator was removed and the patient was started on strict physiotherapy protocol (Active and passive mobilization of the joint) (Fig 9).

To avoid heterotopic ossification and to reduce pain, indomethacin was prescribed 25mg bid with gastric protection for 2 weeks after the 1st procedure. At follow-up, the range of motion of the elbow was recorded and the stability of the elbow joint tested on examination.

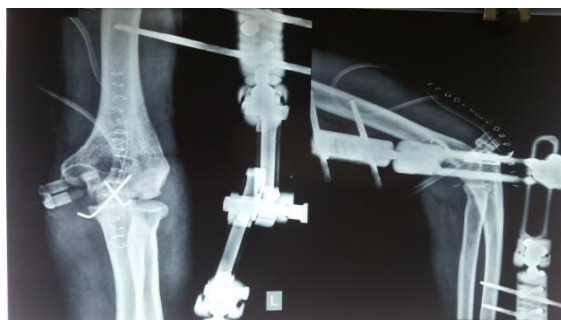

Figure 7: Anteroposterior and lateral radiographs showing reduced elbow with Kirshner wires in situ

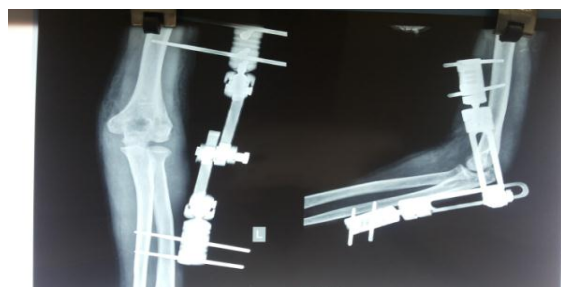

Figure 8: Anteroposterior and lateral radiographs showing reduced elbow after the Kirshner wires removal

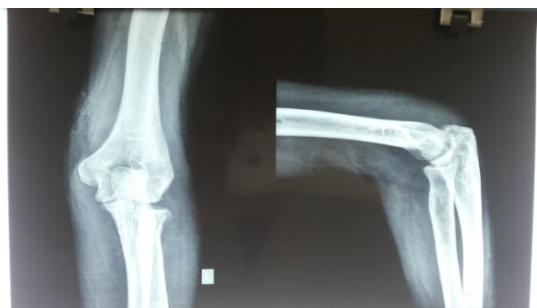

Figure 9: Anteroposterior and lateral radiographs showing reduced elbow after the removal of LRS

Radiographs in two planes were taken to assess articular alignment and post-traumatic arthrosis. Patients were evaluated using the Mayo Elbow Performance Score (MEPS) (Fig 13) [14] and the Disabilities of the Arm, Shoulder, and Hand (DASH) instrument [15] before the index operation and at final follow-up

RESULTS

No peri- or postoperative complications were recorded. No pin-site infections occurred. No re dislocation was recorded. The average period of follow-up was 5 months (6 and 4 months). Clinical examination at follow-up revealed no evidence of elbow instability. The average range of motion at follow-up was 0-120° flexion (125 & 115°) (Fig 10); forearm rotation was not restricted in any patient (Fig 11). No ulnar nerve dysfunction was observed. Radiographs at follow-up revealed concentric reduction and anatomic alignment of the ulno-humeral and the radiocapitellar joints in both patients. Mayo Elbow Performance Score (MEPS) shows Excellent results in both patients (Table 1).



Figure 10: Clinical photograph showing the range of motion of elbow at 5 months follow up



Figure 11: Clinical photograph showing forearm movements at 5 months follow up

DISCUSSION

Due to the apparently conflicting goals of restoring elbow stability and regaining a satisfactory arc of motion, treatment of chronic elbow dislocation is still a challenge for the experienced orthopaedic surgeon. Prolonged dislocation of the elbow causes contracture and fibrosis of the joint capsule and ligaments and shortening of the triceps and biceps muscle, leading to consolidation of the dislocation.

The standard treatment of chronic elbow dislocations had consisted of open reduction, v-y-muscleplasty of the triceps, with/without ligament reconstruction and/or cast immobilisation (Table 2; for review: Lyons et al. (2008) [16]). In 2001, Ruch and Triepel [17] reported successful treatment of five patients suffering from recurrent or chronically persisting elbow dislocations after failure of the initial operative or non-operative treatment, using hinged external fixation as an alternative to complete osseous and ligamentous reconstruction. Subsequently, several reports have been published of successful treatment of chronic elbow dislocations using hinged external fixation with or without repair or reconstruction of the collateral ligaments [7, 18–22] (Table 2). While preserving mobility of the elbow, hinged humeroulnar fixation provides guided stability to the joint. The soft tissues heal in a directed mode and lead to re-establishment of the ligament apparatus, and repaired or reconstructed collateral ligaments are protected [11].

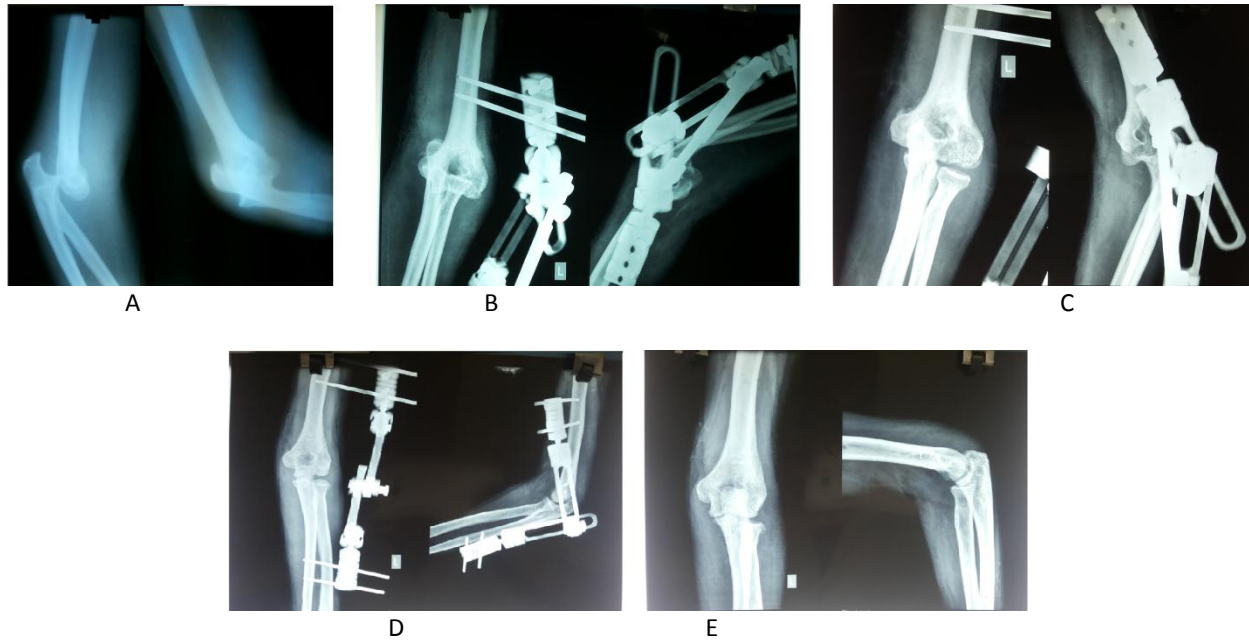


Figure 12: A-E—Anteroposterior and lateral radiographs of Patient 2 treated with Limb Reconstruction System (LRS) showing good reduction of elbow joint at 4 months followupupupup

MAYO ELBOW PERFORMANCE SCORE

Pain (max., 45 points)

- None (45 points)
- Mild (30 points)
- Moderate (15 points)
- Severe (0 points)

Mean

Stability (max., 10 points)

- Stable (10 points)
- Moderately unstable (5 points)
- Grossly unstable (0 points)

Mean

Range of motion (max., 20 points)

- Arc > 100 degrees (20 points)
- Arc 50 to 100 degrees (15 points)
- Arc < 50 degrees (5 points)

Mean

Function (max., 25 points)

- Able to comb hair (5 points)
- Able to feed oneself (5 points)
- Able to perform personal hygiene tasks (5 points)
- Able to on shirt (5 points)
- Able to put on shoes (5 points)

Mean

Mean total (max., 100 points)

>90 – Excellent 75 – 89 – Good 60 – 74 – Fair <60 – Poor

We have tried open reduction of the joint in the first stage in one of our previous cases of chronic elbow dislocation of more than 4-months. But intra operatively, we found severe contractures of ligaments, capsule, triceps and biceps muscle. We could not reduce the joint even after collateral ligament release, and had to sacrifice the head of radius to reduce the joint. Hence we have opted for this 3 stage procedure.

As reported here, our treatment strategy consists of initial in situ neurolysis of ulnar nerve. Neurolysis is done because, prolonged dislocation of the elbow leads to extensive fibrosis around the nerve, and significant tension is applied to it during distraction, reduction and flexion. Hence release of the nerve will prevent any complications of stretching of the nerve. Subsequently, closed mechanical distraction of the joint is done by unilateral Orthofix LRS external fixator gradually over a period of 15 days to bring the articular surfaces at the same level. Recent biomechanical studies of the forces acting on the elbow joint during distraction have shown that at least 1000 Newton act on the joint and fixator construct and that distraction of 60 mm (4mm / day over a period of 8 days) does not lead to any disruption of the ligaments or joint capsule. In agreement with recent reports [7, 17, 19], we did not reconstruct the collateral ligament complex, as the distraction of the joint had stretched the ligaments, muscle and capsular contractures making it easy to reduce the joint. This is especially true when a hinged fixator is used, because it has been shown to modulate and re-establish a biomechanically stable ligament complex [11]. At follow-up none of our patients showed evidence of joint instability.

As posttraumatic elbow stiffness is a common problem in reconstructive elbow surgery, a mechanical distraction technique was established using a Orthofix Limb Reconstruction System (LRS) with motion capacity to distract the articular surfaces and contracted joint capsule and ligamentous structures [9, 10]. The elbow fixator enables distraction to be maintained along the humeral and ulnar fixator links and withstands the forces tending to redislocate the joint and controls the intraarticular surface pressure of the ulno-humeral and radio-capitellar joints. It also permits movements at the elbow joint without posing the problem of redislocation. Pronation and supination is not affected by the external fixator.

At follow up, both patients achieved an excellent functional outcome with an average range of motion of 0-120° of flexion and no residual elbow instability. Our results suggest that this 3 stage technique using monolateral Orthofix LRS external fixator with motion capacity and slow distraction of the elbow joint is a promising method of management of chronically unreduced elbow dislocations to restore stability and to regain a satisfactory range of motion.

CONCLUSION

Due to the apparently conflicting goals of restoring elbow stability and regaining a satisfactory range of motion, treatment of chronically unreduced elbow dislocations is a challenge for the experienced orthopaedic surgeon. Over time treatment strategies have been modified, and recently, several reports of successful treatment of chronic elbow dislocation using hinged external fixation have been published. Our defined treatment protocol comprises of in situ neurolysis of ulnar nerve, distraction of elbow joint using unilateral Orthofix LRS fixator with motion capacity as a 1st stage and open reduction and transarticular Kirshner wires fixation as a 2nd stage and removal of the wires and mobilisation of the elbow joint as the 3rd stage treatment. It helps in mobilising the joint with the external fixator in situ and prevents stiffness due to the surgical procedures. The external fixator also counteracts the forces that tend to redislocate the elbow. It also provides a successful tool to restore elbow stability and regain an excellent functional outcome without the need for collateral ligament reconstruction.

REFERENCES

- [1] Jupiter JB. (1992): Trauma to the adult elbow fractures of the distal humerus. Trafton PG (eds) Skeletal
- [2] trauma, vol Saunders, Philadelphia, p 1141 King GJW. (2007): The complex dislocations of the elbow & treatment of elbow lesions.
- [3] Springer, Milan, p 103 Kuhn MA, Ross G (2008): Acute elbow dislocations. Orthop Clin North Am 39: p155-161
- [4] DeLee JC, Green DP, Wilkins KE (1984): Fractures and dislocations of the elbow. Rockwood CA, Green DP: Fractures in adults, 2nd edn. Lippincott, Philadelphia, p 559

- [5] Linscheid RL, Wheeler DK (1965): Elbow dislocations. JAMA 194: p113–118
- [6] Edean ED, Veldenz HC, Schwarcz TH, Hyde GL (1992): Recognition of arterial injury in elbow dislocation. J VascSurg16: p402–406
- [7] Jupiter JB, Ring D (2002): Treatment of unreduced elbow dislocations with hinged external fixation. J Bone Joint Surg Am 84-A: p1630–1635
- [8] Regan W, Morrey BF (1989): Fractures of the coronoid process of the ulna. J Bone Joint Surg Am 71:1348–1354
- [9] Mader K, Koslowsky TC, Gausepohl T, Pennig D (2007): Mechanical distraction for the treatment of posttraumatic stiffness of the elbow in children and adolescents. Surgical technique. J Bone Joint Surg Am 89Suppl 2: p26–35
- [10] Mader K, Pennig D, Gausepohl T, Koslowsky TC, Wolke AP (2004): Post traumatic stiffness of the elbow: arthrodialysis using unilateral hinged external fixation. Scientific exhibit at the 71st AAOS meeting, San Francisco, California, March 10–14
- [11] Pennig D, Gausepohl T, Mader K (2000): Transarticular fixation with the capacity for motion in fracture dislocations of the elbow. Injury 31Suppl 1: p35–44
- [12] O’Driscoll SW, Jupiter JB, Cohen MS, Ring D, McKee MD (2003): Difficult elbow fractures: pearls and pitfalls. Instr Course Lect 52: p113–136
- [13] Terada N, Yamada H, Seki T, Urabe T, Takayama S (2000): The importance of reducing small fractures of the coronoid process in treatment of unstable elbow dislocation. J Shoulder Elbow Surg 9: p344–346
- [14] Morrey BF, Adams RA (1992): Semiconstrained arthroplasty for the treatment of rheumatoid arthritis of the elbow. J Bone Joint Surg Am 74: p479–490
- [15] Hudak PL, Amadio PC, Bombardier C (1996): Development of an upper extremity outcome measure: the DASH disabilities of the arm, shoulder, and hand). The Upper Extremity Collaborative Group. Am J Ind Med 29:602–608
- [16] Lyons RP, Armstrong A (2008): Chronically unreduced elbow dislocations. Hand Clin 24: p91–103
- [17] Ruch DS, Triepel CR (2001): Hinged elbow fixation for recurrent instability following fracture dislocation. Injury 32 Suppl 4: p70–78
- [18] Degreef I, De Smet L (2007): Chronic elbow dislocation: a rare complication of tennis elbow surgery. Successful treatment by open reduction and external fixator. Chir Main 26: p150–153
- [19] Lo CY, Chang YP (2004): Neglected elbow dislocation in a young man: treatment by open reduction and elbow fixator. J Shoulder Elbow Surg 13: p101
- [20] Ohno Y, Shimizu K, Ohnishi K (2005): Surgically treated chronic unreduced medial dislocation of the elbow in a 70-year man: a case report. J Shoulder Elbow Surg 14: p549–553
- [21] Ring D, Hannouche D, Jupiter JB (2004): Surgical treatment of persistent dislocation or subluxation of the ulnohumeral joint after fracture-dislocation of the elbow. J Hand Surg 29A: p470–480
- [22] Sunderamoorthy D, Smith A, Woods DA (2005): Recurrent elbow dislocation—an uncommon presentation. Emerg Med J 22: p667–669
- [23] Balchandani RH (1969): Unreduced dislocations of the elbow. Proceedings of the Indian Orthopaedic Association. J Bone Joint Surg Br 51: p781
- [24] Ashby ME (1974): Old dislocations of the elbow. J Natl Med Assoc 66: p465–467, 47125.
- [25] Krishnamoorthy S, Bose K, Wong KP (1976): Treatment of old unreduced dislocation of the elbow. Injury 8: p39–42
- [26] Billett DM (1979): Unreduced posterior dislocation of the elbow. J Trauma 19: p186–188
- [27] Dryer RF, Buckwalter JA, Sprague BL (1980) Treatment of chronic elbow instability. Clin Orthop 148: p254
- [28] Naidoo KS (1982): Unreduced posterior dislocations of the elbow. J Bone Joint Surg Br 64: p603–606
- [29] Fowles JV, Kassab MT, Douik M (1984): Untreated posterior dislocation of the elbow in children. J Bone Joint Surg Am 66: p921–926
- [30] Martini M, Benselama R, Daoud A (1984): Neglected subluxations of the elbow. 25 surgical reductions. Rev Chir Orthop Reparatrice Appar Mot 70: p305–312 French
- [31] Arafles RP (1987): Neglected posterior dislocation of the elbow. A reconstruction operation. J Bone Joint Surg Br 69: p199–202
- [32] di Schino M, Breda Y, Grimaldi FM, Lorthioir JM, Merrien Y (1990): Surgical treatment of neglected elbow dislocations. Report of 81 cases. Rev Chir Orthop Reparatrice Appar Mot 76: p303–310 French
- [33] Bruce C, Laing P, Dorgan J, Klenerman L (1993): Unreduced dislocation of the elbow: case report and review of the literature. J Trauma 35: p962–965

- [34] Moritomo H, Tada K, Yoshida T, Kawatsu N (1998): Reconstruction of the coronoid for chronic dislocation of the elbow. *J Bone Joint Surg Br* 80: p490–492
- [35] Devnani AS (2004): Outcome of long-standing dislocated elbow treated by open reduction and excision of collateral ligaments. *Singapore Med J* 45:14–19
- [36] Mahaisavariya B, Laupattarakasem W (2005): Neglected dislocation of the elbow. *Clin Orthop Rel Res* 431: p21
- [37] Mighell MA, Dunham RC, Rommel EA, Frankle MA (2005): Primary semiconstrained arthroplasty for chronic fracture-dislocations of the elbow. *J Bone Joint Surg Br* 87:p191–195
- [38] Majima M, Horii E, Nakamura R (2007): Treatment of chronic dislocated elbows: a report of three cases. *J Shoulder Elbow Surg* 16:e1–e4
- [39] Pennig D, Gausepohl T, Mader K. (2000): Transarticular fixation with the capacity for motion in fracture dislocations of the elbow. *Injury* 31 Suppl 1 :p35-44.
- [40] Stavlas P, Gliatis J, Polyzois V, Polyzois D. (2004): Unilateral hinged external fixator of The elbow in complex elbow injuries. *Injury* 35 : p1158-1166.