



Research Journal of Pharmaceutical, Biological and Chemical Sciences

A Rare Fracture of the Superior Border of Scapula.

Kumaravel Shanmugasundaram*

Department of Orthopedics, Government Thanjavur Medical College, Medical College Road, Thanjavur 613004 / Orthopedic Surgeon, National Pharma Hospital and Research Institute, Thanjavur 613004, Tamil Nadu, India.

ABSTRACT

Shoulder injuries are usually identified and treated with regular X-rays. Occasionally there is every chance that some fractures are missed if not carefully looked for. We present one rare fracture in shoulder which was identified and treated. CT scan of the shoulder help in difficult situations. The paper reports a rare type fracture of superior border of scapula.

Keywords: Rare Fracture, Superior border of scapula, CT scan.

**Corresponding author*

INTRODUCTION

Shoulder injuries are usually recognized and treated with regular X-rays. Rarely there is every chance that some fractures of scapula are missed if specific regions are not carefully analyzed. We present one rare fracture in shoulder which was identified and treated.

Case Report

A 58 year old retired gentleman had a fall from his motor bike and he landed on his right shoulder. He presented with pain in his right shoulder and right side chest. On examination he was comfortable at rest. He had tenderness over the acromion process and right side ribs. His air entry is was almost equal on both sides. His shoulder and chest X-rays are seen in figures 1 and 2.

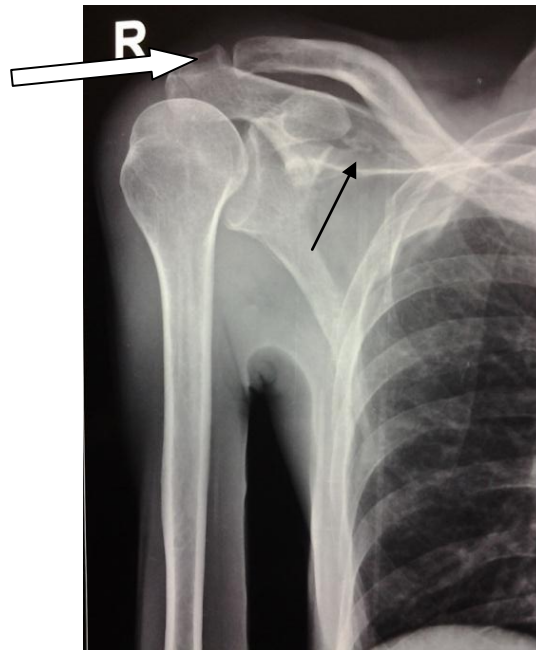


Figure 1: The patient's right shoulder radiograph. The white arrow marking the crack fracture of acromion. The black arrow pointing the avulsed small fragment of the upper border of scapula.

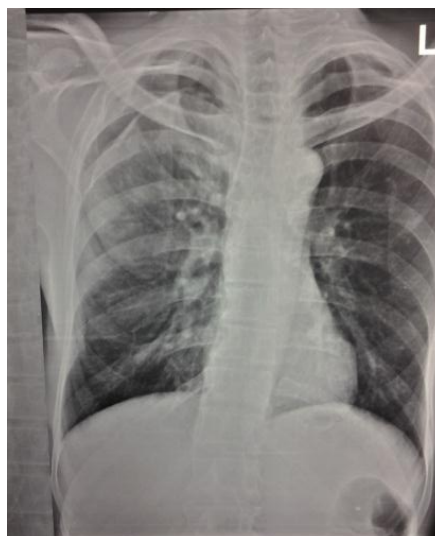

Figure 2: The patient's chest radiographs show comparatively poor ventilation of right lung. The angles of the lungs are well defined

In the patient's right shoulder radiograph (Figure 1) there was a small fragment of avulsion in the upper border of scapula. The right clavicle was normal. The X-ray of the chest did not show any lesion except for poor ventilation of the right lung. Figure 2 He was advised CT of thorax, right shoulder and brain. The brain CT was normal. In the CT of the thorax, there was a fracture of the right sixth rib in the mid-axillary line level along with collapse of the right lung especially the lower lobe along with pleural collection hemothorax. (Figure 3 and 4) In the CT of shoulder there was a rare type of avulsion fracture of the superior border of the scapula. Figure 5. A reconstruction of the scapula is shown in figure 6 showing the configuration of the above fracture. He had an intercostal drainage for the hemothorax .Patient's shoulder was treated conservatively in a sling. At six weeks follow up the patient had painless under arm movements and his intercostal drainage tube was removed with the site being clean and dry. .He was mobilized after six weeks i.e after the time required for adult cancellous bone healing. At six months follow up his shoulder range of movement improved. His repeat CT scan showed complete union of the avulsed fracture of upper border.

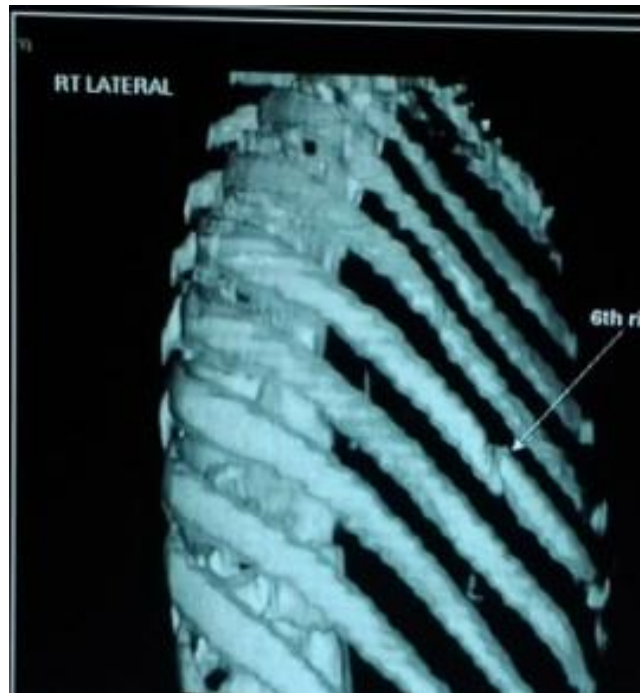

Figure 3: Reconstruction CT of the thorax. The arrow marks the fractured sixth rib.

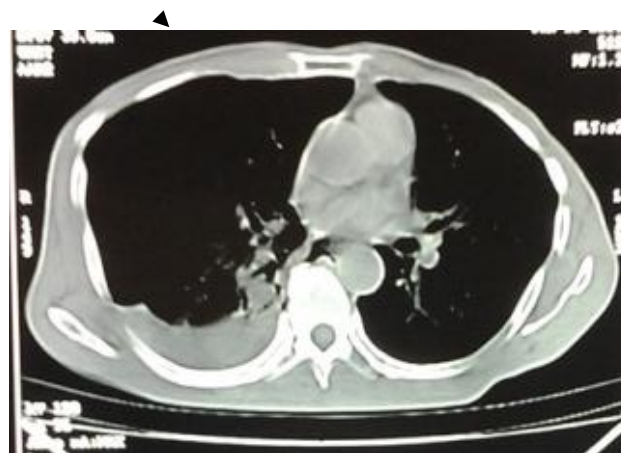


Figure 4: CT. thorax showing the hemothorax on the right side.

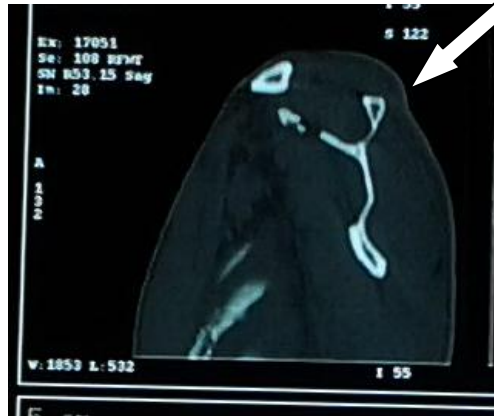


Figure 5: Saggital section of the CT scan showing the fracture of the upper border of scapula- marked with an arrow

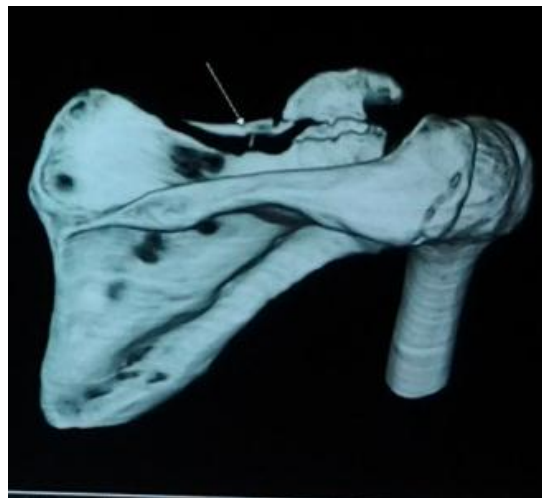


Figure 6: Reconstructed shoulder CT showing the fracture of the upper border of scapula- marked with an arrow

DISCUSSION

In adults fractures of scapula occur more frequently at the base of the coracoids, occasionally extending on to the upper border of scapula or glenoid [1]. The avulsion type of fractures of the upper border of the scapula is rarely described. Only a few case reports are seen [2]. In a series of twenty-four superior border of the scapula fractures reported, there was associated fracture of the coracoid process in all. In two cases there was an avulsion fracture by traction through the superior transverse scapular ligament resulting from the upward displacement of the coracoid [3]. There was a similar upward migration of the coracoids in our case. In one report there is fracture of the first rib, fracture of the upper border of scapula with fracture of the spinous process [4]. In another case there was bilateral fracture of the upper border of scapula with middle third fracture of clavicle [4]. The case was presented for rarity of occurrence of such fractures.

The case report also highlights the need for aggressively treatment he associated injuries were aggressively treated.

REFERENCES

- [1] Van Noort A. Scapular fractures. Chapter 37 – Bucholz Ed: Rockwood and Green's Fractures in Adults seventh edition: 1145-62
- [2] Ishizuki M, Yamaura I, Isobe Y, Furuya K, Tanabe K, Nagatsuka Y. J Bone Joint Surg Am 1981; 63(5):820-822.
- [3] Ogawa K Yoshida. Int Orthop 1998; 21(6): 371–373.
- [4] Arenas AJ. Pampliega T. Acta Orthop Belgica 1993; 59(4):398-400.