

Research Journal of Pharmaceutical, Biological and Chemical Sciences

An Analysis and Study of Retinal Images for Evaluating the Optic Disc.

Nadesh RK*, Suchitra J, and Arivuselvan K.

School of Information Technology and Engineering, VIT University, Vellore, Tamil Nadu, India.

ABSTRACT

This paper presents a algorithm to automatically detect the notch present in retina. Glaucoma is a eye disease which is caused due to high intra ocular blood pressure. The disease in later stages may even cause blindness if not detected at early stage. The automated system is developed to detect the presence of notch in the retina. By analyzing the optic cup and calculating the cup to disc ratio of the eye we classify the sample as healthy and non-healthy.

Keywords: Glaucoma, optic cup, notch detection, Segmentation

**Corresponding author*

INTRODUCTION

Glaucoma is a eye disease which occurs due to high intra ocular pressure in the fluid content of the eye. The intra ocular pressure leads to notching in the retinal part of the eye. This paper presents a algorithm to detect the notch present in the optic cup. The images from fundus photography show clearly the interior surface of the eye can be used for analysis.

To differentiate normal eyes from glaucomatous eyes the presence of notching in the optic cup is a method which is commonly used. Axons are destroyed in the case of presence of glaucoma which leads to the thinning of the neural rim. The thinning of the neural rim occurs in the inferior region of the cup. This will make the optic cup to enlarge in the vertical direction. The change in the shape of optic cup is widely used to determine the presence of notching.

The main algorithm involves disc segmentation, vessel segmentation and finally determination of ratio between the cup and disc which determines the presence of notching. The cup to disc ratio for normal eyes is 0.3. A large CDR ratio determines the presence of glaucoma.

Related Works

Glaucoma is detected in color fundus images using a algorithm [2] which involves preprocessing and image based feature extraction. Pixel intensity values, the texture involved, histogram parameters, special features for glaucoma and different classifiers are involved to detect the disease.

There is more complexity in the optic system and there are small objects in the image. Non uniform illumination makes the processing more complex. In previous work [3] an illumination correction method is involved which helps in further processing of the retinal image.

Sai Deepak et al [4] generalized moment pattern for representing the image. In this method converts the region of interest to GMP which helps in the detection of localized high contract lesions in retina to ensure the abnormality.

Manual thresholding analysis is generally used for disc segmentation of retinal images. Kavitha et al [5] proposed component analysis model and region of interest for disc segmentation. In component analysis method while analyzing the RGB components it was found that the optic disc can be segmented from the red image.

Bock et al [6] proposed a data driven approach for detecting glaucoma. After pre-processing, principal component analysis is used to reduce the dimensionality and further features like mean and variance are calculated from coefficients of fast Fourier transform. 2-stage classification method is used to detect glaucoma in the retina.

Macula is the region which helps in high resolution of vision. To detect macula in the retinal image Wong et al [8] proposed a method in which the contextual information is first obtained in the image and then a seeded mode method is used to determine the center of the macula.

To localize the optic disk a novel method was proposed by Sekhar et al [9] where morphological operations are done for isolating the brightest area and circular region of interest is used to locate the disk. Further in this work they have used hough transform to analyze the circular feature of the optic disk. A common ISNT rule is applied to detect the notching present in the retina. In healthy eye the retina is thicker at the inferior surface than the temporal. The order of thickness extends from inferior, superior nasal and temporal. Violation from the ISNT rule makes the rim thinner in the inferior surface which denotes the presence of notching. The algorithm proposed involves disc and vessel segmentation. Cup to disc ratio is mainly analyzed to detect the presence of notching in the eye.

Proposed Architecture

The proposed architecture (Figure 1) mainly involves four steps which include Image pre-processing, Disc Segmentation, Vessel Segmentation and calculation of cup to disc ratio.

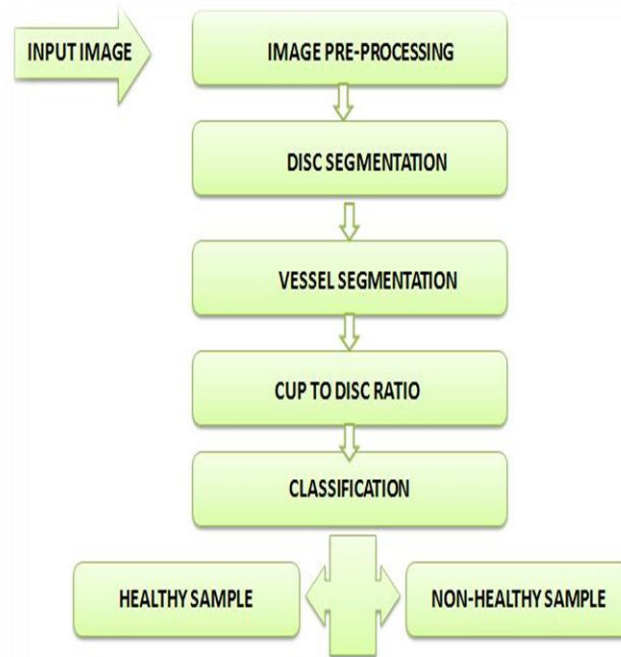


Figure 1: Proposed Architecture

The digital fundus image is used in the entire processing. The fundus image is created from the fundus photography. The image shows the interior surface including retina, optic disc and macula. The obtained image may contain noise so pre-processing is done to reduce the noise making the image suitable for further processing.

Pre-processing involves thresholding the red channel in the image. Grey scale image carries only intensity information. They are monochromatic images which capture the frequency which helps in processing than the original rgb image. The input image is converted to grey scale image in the first step. Morphology helps to process the images based on certain shapes. Morphological operations can be performed to the binary image or the grey scale image. Basic morphological operations such as dilation and erosion are performed to remove noise from the image. Dilation involves adding pixels to the boundaries whereas erosion involves removing pixels from the boundary. Depending on the size of structuring elements we decide the number of pixels to be added or removed during the processing. Image histogram is obtained to show the tonal distribution of the image.

For disc segmentation multi-scale enhancement filter is used to enhance the image. Image segmentation involves the process where the digital image is partitioned into multiple segments or set of pixels. By segmenting we assign labels to every pixel to characterize their visual properties. Mainly segmentation is used to locate the boundary of a particular object in the image. Edge detection is one of the segmentation methods in image processing. Edge detection is performed using the sobel operator which segregates the edge of the retina based on the threshold. The disk shape parameter is used for the structuring element to obtain the disc.

The vessels are segmented and the region of interest is analyzed to extract the properties of the optic cup. Region properties help to measure the properties of the particular region. The optic cup structure is analyzed for further classification. The cup-to-disc ratio ensures the classification of healthy to non-healthy eye. We have to compare the diameter of the cup to the total diameter of the disc. The cup-to-disc ratio is 0.3 in healthy eyes. A larger ratio determines the eye to be non- healthy.

EXPERIMENTS AND RESULTS

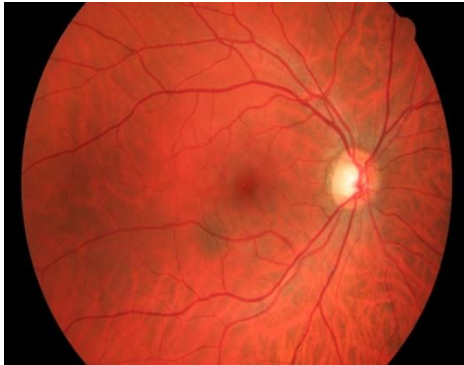


Figure 2: Healthy Sample

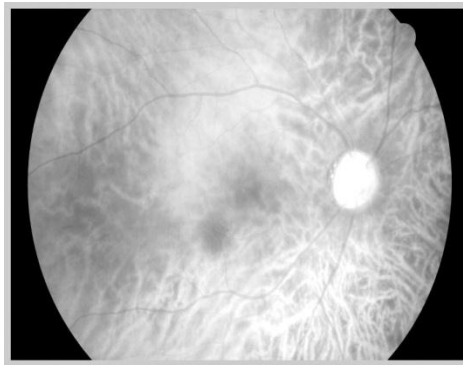


Figure 3: Filtered Healthy Sample

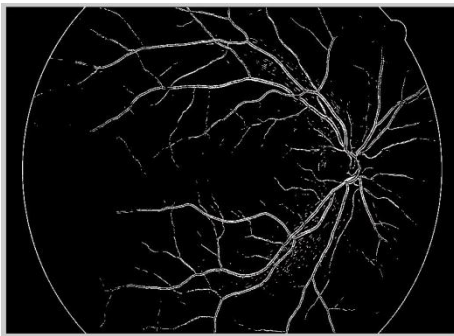


Figure 4: Segmented Healthy Sample

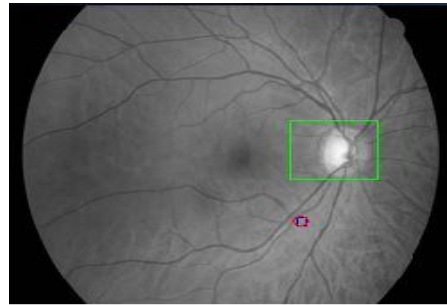


Figure 5: Optic cup for Healthy Sample

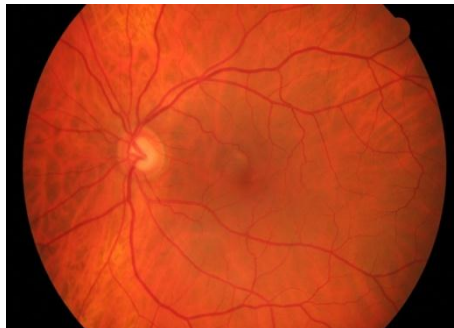


Figure 6: Non Healthy Sample

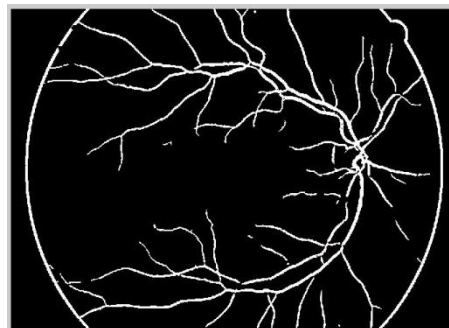


Figure 7: Segmented Non-healthy sample

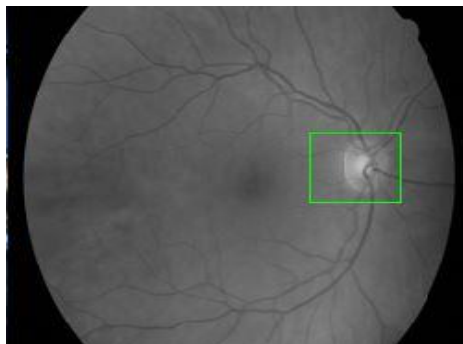


Figure 8: Optic Cup for Non healthy Sample

The proposed system was implemented with a set of fundus image samples. The input image (Figure 2) is read into the system. The image is converted to grey scale image and thresholding is performed to the red channel. Then the noise is filtered from the image (Figure 3) to make it fit for processing. The filtered image undergoes segmentation (Figure 4). Further the optic cup is detected (Figure 5) and the ratio is determined to classify as healthy or non-healthy sample. The process for a non-healthy sample (Figure 6) is represented. The implemented algorithm have been tested with 100 samples.

CONCLUSION

The proposed retinal image analysis system helps to speed up the inspection process. The algorithm implemented is efficient and accurate. Automated analysis of the samples helps to easily identify the disease present in the eye. Glaucoma is an eye disease which in later stages will lead to blindness. So early detection is needed this can be done in an automated way.

REFERENCES

- [1] Madhusudan Mishra, Malaya Kumar Nath and Samarendra Dandapat. Int J Comp Comm Technol 2011;2(4).
- [2] Rudiger Bock, Jorg Meier, Georg Michelson, and Joachim Hornegger "Classifying Glaucoma with Image-Based Features from Fundus Photographs", Springer Berlin Heidelberg, 2009
- [3] Laszlo G. Nyulab "Retinal image analysis for automated glaucoma risk Evaluation" Medical Imaging, Parallel Processing of Images, and Optimization Techniques, 2010
- [4] K Sai Deepak, Madhulika Jain, Gopal Datt Joshi, Jayanthi Sivaswamy. ICVGIP 2012, December 16-19.
- [5] S Kavitha, S Karthikeyan, K Duraiswamy. Early Detection of Glaucoma in Retinal Images Using Cup to Disc Ratio. Second International conference on Computing, Communication and Networking Technologies, 2010
- [6] Rudiger Bock, Jorg Meier, Laszlu G. Nyul, Georg Michelson, Joachim Hornegger. Retina Image Analysis System for Glaucoma Detection. 2010.
- [7] Prageeth PG & David J, Sukesh Kumar A. Early Detection of Retinal Nerve Fiber Layer Defects using Fundus Image Processing. IEEE, 2011.
- [8] Damon WK. Wong, Jiang Liu, Ngan-Meng Tan, Fengshou Yin, Xiangang Cheng, Ching-Yu Cheng, Gemmy C.M. Cheung and Tien Yin Wong, "Automatic Detection of the Macula in Retinal Fundus Images using Seeded Mode Tracking Approach" , 34th Annual International Conference of the IEEE EMBS, September 2012
- [9] Sumeet Dua U. Rajendra Acharya, Pradeep Chowriappa S. Vinitha Sree. IEEE Trans Inform Technology Bio Med 2012;16.
- [10] SSA Salem, NM Salem and AK Nandi. MBEC 2007;45(3):261-273.