

# Research Journal of Pharmaceutical, Biological and Chemical Sciences

## Placement of Implants in Maxilla: A Case Report.

Vijay Ebenezer<sup>1\*</sup>, R Balakrishnan<sup>1</sup>, Pradeep Christopher<sup>2</sup>, and T Muthu Mani<sup>1</sup>.

<sup>1</sup>Department of Oral and Maxillofacial Surgery, Sree Balaji Dental College and Hospital, Bharath Unniversity, Pallikaranai, Chennai, 600100, Tamil Nadu, India.

<sup>2</sup>Department of Oral and Maxillofacial Surgery, Thaimoogambigai Dental College and Hospital, Mogappair (West), Anna Nagar, Chennai, 600017, Tamil Nadu, India.

### ABSTRACT

Placement of implant in posterior maxilla is most difficult due to its anatomic features. In this case report implant placement with sinus lift, without use of bone graft as filling material is done without affecting the stability of the implants.

**Key words:** implant, maxilla, sinus membrane, bone.

*\*Corresponding author*

## INTRODUCTION

The posterior maxilla has been described as the most difficult and problematic intraoral area confronting the implant practitioner, requiring a maximum of ingenuity for the achievement of successful results [1]. Both anatomical features and mastication dynamics contribute to the challenge of placing titanium implants in this region.

Anatomic factors include decreased bone quantity, enlarged antrum, softer and poorer bone quality especially with older edentulous or partially edentulous patients who have experienced alveolar resorption in the wake of tooth loss. Mastication dynamics also affect the long-term stability of implants placed in the posterior maxilla. Whereas masticatory forces of 155N have been reported in the incisor region, the premolar and molar regions have exhibited forces of 288N and 565N, respectively. Parafunction can increase these forces as much as threefold, applying significant stress to the bone-implant interface and the component hardware [2].

Also, in implant dentistry, the posterior maxilla implant has been a source of concern and apprehension, due to the risk of sinus perforation, damage to the Schneiderian membrane and its complications [3, 4].

Initial stability of the implant is a key factor during implant placement and for successful osseointegration. Initial stability of posterior maxillary implants could be improved by the accurate bicortical engagement of the implant with the crestal cortical bone and the floor of the sinus cortical bone [3].

### Case Report

The patient was 58 year old man with a history of controlled diabetes under medication. He presented with missing right upper cuspid, bicuspid and molars. He had previously also undergone extraction of left upper molars atraumatically due to decay. Patient also complained of mobility in the left upper bicuspid. Radiographic evidence showed loss of vertical dimension of ridge due to bone loss ( fig 1). It was decided to extract the mobile teeth and replace the missing upper left and right posterior teeth with implants. Post extraction the patient was reviewed after 3 months.

Patient was operated under local anesthesia and strict aseptic protocol. A mid crestal incision was performed for flap elevation at the site of implant placement and bone was then exposed. A precision drill was used to locate the proposed site of the implant, then 2mm twist drill was used then 3mm twist drills in sequence as per manufacturer's recommendation was used. Implant with diameter 3.0mm and length of 11.5 and 13mm were selected. The sinus floor is elevated by osteotome, bone piles up in front of the penetrating osteotomes, allowing the sinus floor to be displaced upwards. Teasing of the Schneiderian membrane is done. After the site was prepared, implant was placed. No bone graft material was used.

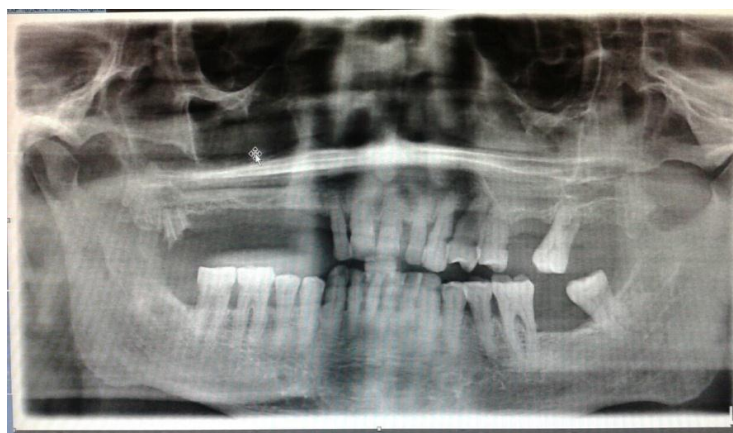


Figure 1: Pre-operative OPG

Implants were positioned and the stability was monitored by using manual torque wrench. Torque of 45N was achieved in each implant placement. A cover screw was then placed and the wound was sutured with 3.0 black silk. (Fig 2)

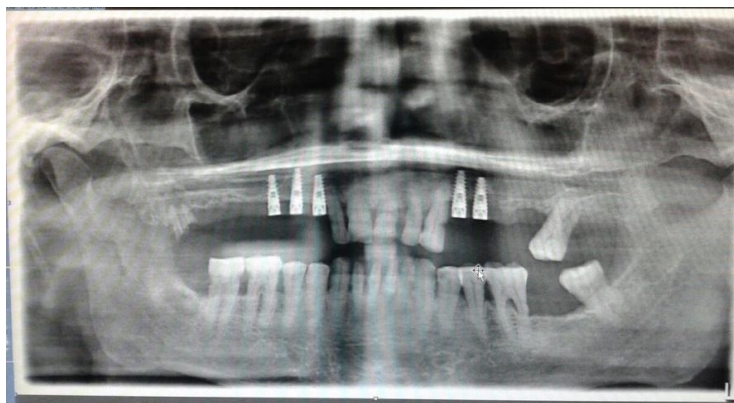


Figure 2: Post-operative OPG 5months

### DISCUSSION

As the choice of the best grafting material has been questioned over the years, the search for the suitable graft material for sinus augmentations of the dental implants may be resolved in an unexpected way if successful and reliable sinus augmentations can be performed without any grafting material [5,6].

In this case, the sinus membrane was teased from the bone surface and the sinus floor was lifted. No bone graft was used to fill the space. Studies done by Shalabi et al., Nedir et al., Emmerich et al [5-8] confirmed that a graft material is not needed to promote osteogenesis and maintain the bone volume around the implants. The sinus floor elevation described by Summers [9,10] involves a grafting material that is condensed in the osteotomy site to elevate the sinus membrane. If the Schneiderian membrane is perforated, the grafting material can migrate into the sinus and cause inflammation [5,11,12]. The present protocol, by eliminating use of a filling material has completely eliminated this risk as well. From the patients' point of view, this technique is a one stage procedure; it eliminates the need for bone harvesting which is usually associated with discomfort; it eliminates concerns about using cadaver or animal derived biomaterials [5,6,13].

Studies by Sang-Han Sul also showed that the surgical procedure by which implants are inserted into the sinus cavity by elevating the sinus membrane without adding any graft material had little influence on the histologic characteristics of the sinus membrane<sup>14</sup>. In addition, the technique is cost-effective and less time consuming compared to the classical lateral window technique [15,16].

### CONCLUSION

This case report showed that implant placement without use of bone graft as filling material following sinus lift does not affect the stability of the implant. The thick band of gingival attached to the smooth collar of implant also helps in providing stability.

### REFERENCES

- [1] Cochran DL, Schenk R, Buser D, Wozney JM, Jones AA. J Periodontol 1999;70:139-150.
- [2] Thomas J. Balshi & Glenn J. Wolfinger. Periodontol 2000, Vol 33, 2003,67-81.
- [3] Nasser Nooh. J Int Oral Health 2013; 5(3):28-34.
- [4] Ten Bruggenkate CM, van den Bergh JP. Periodontol 2000. 1998;17:176-82.
- [5] Nedir R, Nurdin N, Vazquez L, Szmukler-Moncler S, Bischof M, Bernard JP. J Clin Periodontol 2010;37:1023-8
- [6] Nedir R, Bischof M, Vazquez L, Nurdin N, Szmukler-Moncler S, Bernard JP. Clin Oral Implants Res 2009;20:701-7.



- [7] Shalabi MM, Manders P, Mulder J, Jansen JA, Creugers NH. Int J Oral Maxillofac Implants 2007;22:110-6.
- [8] Emmerich D, Att W, Stappert C. J Periodontol 2005;76:1237-51.
- [9] Summers RB. Compendium 1994;15:698-710
- [10] Summers RB. Compendium 1994;15:152-62.
- [11] Pikos MA. Implant Dent 2008;17:24-31.
- [12] Raghoobar GM, Timmenga NM, Reintsema H, Stegenga B, Vissink A. Clin Oral Implants Res 2001;12:279-86.
- [13] Sani E, Veltri M, Cagidiaco MC, Balleri P, Ferrari M. Int J Oral Maxillofac Surg 2008;37:966-9.
- [14] Sul S.-H., Choi B.-H., Li J., Jeong S.-M., Xuan F. Oral Surg Oral Med Oral Pathol Oral Radiol Endodontol 105 (4)
- [15] Listl S, Faggion CM Jr. J Clin Periodontol 2010;37:777-87.
- [16] Tatum H Jr. Dent Clin North Am 1986;30:207-29.