

Research Journal of Pharmaceutical, Biological and Chemical Sciences

Kienbock's Disease in A 23yr Old Male: A Case Report and Review of the Literature.

Sasikumar K*, Venkatachalam K, Abilash Rinald GS, Sivacharan S, and Rajash Babu AK.

Department of Orthopaedics, Sree Balaji Medical College and Hospital, Bharath University ,Chennai, Tamil Nadu, India.

ABSTRACT

To present the diagnostic, clinical features, and management of Kienbock's disease and create awareness of the differential diagnosis of this condition in patients presenting with insidious, progressive dorsal wrist pain. A 23-year old male presented with insidious progressive dorsal sided wrist pain. A diagnosis of Kienbock's disease was made based on magnetic resonance imaging. A 3mm ulnar-minus variance was found and a joint leveling procedure to shorten the radius was performed. Conservative therapy was provided pre and post surgical management. This case report demonstrates the importance of findings on MRI and clinical examination in the accurate diagnosis and management of a patient with wrist pain.

Keywords: Kienbock, Kienbock's disease, lunatomalacia, avascular necrosis, osteonecrosis, lunate

**Corresponding author*

INTRODUCTION

Robert Keinbock in 1910 described the Keinbock disease as those occurring due to disruption of blood supply to the lunate. It is the osteonecrosis of the lunate bone belonging to the carpus bone. Plain radiographs usually show sclerosis, fragmentation, cysts and articular involvements. The etiologic is unknown. Due to its unknown aetiology the treatment options for this disease still remains controversial. The differential diagnosis can be lunate fracture and dislocation or scapholunate strain. Our case report is about a 23 year old student with Keinbock's disease.

CASE REPORT

Our patient a 23 year old male, a college student presented with intermittent pain more on moving the wrist. The pain started 2 years ago but has aggravated since 5 months. There was no diurnal or postural variation of the pain.

The pain was mainly in the dorsal and palmar side of the wrist. There was history of slip and fall from bus 2 years ago. There was no pain at the time. The pain was waxing and waning in type. Patient felt more pain while driving his two wheeler. An outside physician had diagnosed him as a case of contusion and was treated for the same. On examination patient had no swelling, signs of inflammation or bruising. The pain was concentrated mainly in the scapholunate and triangular fibro cartilaginous regions. There was no pain present over the lunate, or other carpal bones. The active range of movements was full with mild pain. There was pain present on axial loading alone. Resisted range of movements however produced pain which was dull aching type and it was confined to the lunate bone. There was no distal neurological deficits. Bilateral x rays of both wrist. The ulnar variance was 3mm. There was mild sclerosis of the lunate present. The proximal carpal arc was maintained. The magnetic resonance imaging showed abnormal signals in the right lunate. With 2mm loss of height.

There was no fluid collection.

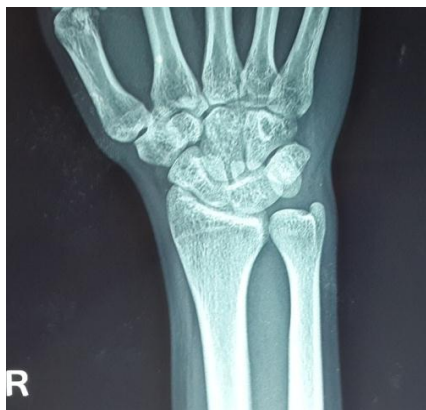

Figure 1: right AP wrist Radiograph appears normal

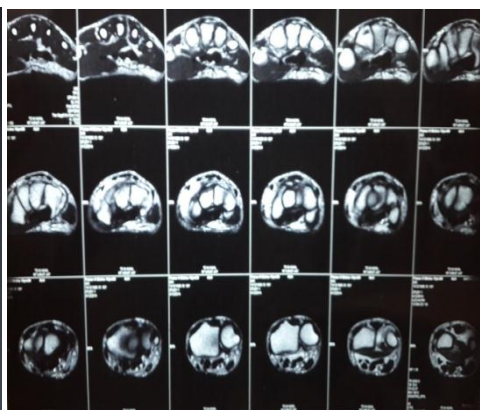


figure 2: right coronal T1 MRI shows abnormal signals at lunate

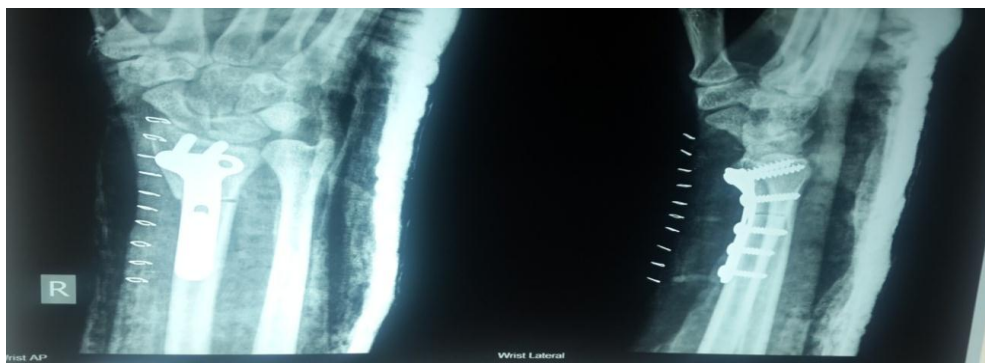

Figure 3: right AP and lateral view showing post op 3mm radial shortening

Patient is diagnosed as stage 1 keinbock's disease. Initially planned for conservative management through fibre cast and immobilization for 6 weeks. Patient had pain even after immobilization. Hence planned for surgical management.

Patient was given ECST by our physiotherapist for 3 weeks and patient symptoms have not reduced. Hence 3mm radial shortening, core decompression lunate and bone grafting done. Patient was immobilised in cast for 6 weeks. After 6 weeks cast was removed and mobilization of wrist started. Wax bath was given as an adjuvant therapy. The patient was asked to do active and passive movements of wrist. After 10 weeks of surgery patient was started on range of motion exercise for wrist. Serial of x rays were taken and there was no progression of disease. After 1 year of surgery patient had painless movements of wrist.

DISCUSSION

Keinbock's in 1910 has found out that lunatomalacia is due to rupture of the ligaments surrounding the lunate with disruption in its blood supply [1,4,5,6]. Which results in aseptic necrosis, bone collapse, and disturbance in nutrition of bone [1,4,5,6]. The aetiology of disease is still a controversy even after years [3]. Diagnosis of keinbock's disease is a challenge due to its rareness and coincidence with symptoms of wrist sprain. Most common in males between 20 to 40 years of age [2,3,6,7]. Common in athletes and manual workers. Mostly unilateral sometimes can be bilateral [2,3,7]. Previous history of trauma to wrist is usually present. The etiology of keinbock is still considered to be unknown till date. Various etiological theories and research activities on the keinbocks disease are still underway. Avascular necrosis of the lunate bone as a consequence of lunate bone collapse due to excessive bony stress and loading is on the basis of mechanical theory [14,15]. Micro fractures of lunate trabeculae leading to bony collapse is caused by excessive load. ulnar minus variant is one of the common most mechanical etiological factor. Axial load cannot be shared to radius by ulna due to ulnar shortening, which compels the force to be transmitted to lunate, further causing nut cracker phenomenon. Mechanical loading is increased by the radio ulnar joint due to the trapezoid shape of the lunate, thus causing compressive loading which causes fragmentation and lunate collapse. [6, 8,9].

Other theories like vascular theory suggest etiology of keinbocks is due to limited arterial supply to the lunate. Due to limited anastomosis of arterial supply, the lunate bone undergoes osteonecrosis. Interosseous pressure increases due to impairment of venous outflow of lunate thus again causing osteonecrosis.

Most widely presumed theory is the traumatic theory, which states that keinbocks is due to rupture of ligaments of the lunate bone, thus causing disruption to blood supply of lunate, further causing sclerosis with micro fracture [3,10,11,12].

Blood supply of lunate is mainly from the wrist sources of palmar and dorsal arteries including radial and ulnar artery [14,15]. Lunate is the most vulnerable carpal bone to undergo osteonecrosis due to its limited blood supply at its proximal pole [16]. Cerebral Palsy, hypercoagulability, systemic corticosteroid use, sickle cell anemia also contribute to osteonecrosis of lunate [2,3,6,7,13].

Degree of osseous changes in lunate and its chronicity are the key factors in easy diagnosis of osteonecrosis. cystic changes, collapse of articular surface, sclerosis, fragmentation and perilunate arthritis can be visualized radiologically. early diagnosis through a radiographic image is difficult, so a magnetic resonance imaging could be considered in cases with persistent pain even after conservative management. [17,18,19].

Lichtman classification [3,6,20,21] is important as it dictates the management options. Stage 1, radiograph shows normal articular surface and density of lunate, MRI shows decreased signal intensity of lunate at its distal portion. Stage 2 fracture lines are seen with normal articular surface of lunate [3,6,20,21,22]. Stage 3 which is subdivided into stage 3a and 3b. stage 3a is common stage of pioneer presentation due to collapse of articular surface of lunate. Stage 3b is fixed rotation of scaphoid proximal migration and collapse of carpal height [3,6,20,21,22]. Stage 4 is collapse of lunate with peri-lunate arthritis [3,6,20,21,22].

Management of keinbocks disease is depended mostly on its stages based on litchman

classification.[3,6].keinbocks can be treated conservative to surgery the most common conservative treatment are immobilization with cast or splinting and activity modification^[3,6,23,24].

Table 1: Management of Kienbock’s disease according to Lichtman classification [3,6]

Stage	Radiographical Findings
Stage I	Cast immobilization for 3 months with use of analgesics and NSAIDS
Stage II and IIIA with ulnar negative variance	3 month trial therapy of immobilization with use of analgesics and NSAIDS Joint leveling technique (radial shortening, ulnar lengthening, capitate shortening)
Stage II and IIIA with ulnar positive variance	3 month trial therapy of immobilization with use of analgesics and NSAIDS Vascularized bone graft and external fixation; radial wedge or dome osteotomy; capitate shortening
Stage IIIB	Internal carpal arthrodesis; lunate excision with or without replacement; proximal row carpectomy; joint leveling
Stage IV	Proximal row carpectomy; carpal arthrodesis; wrist denervation

There are multiple surgical methods for management of keinbock's disease. For stage 1 conservative management is ideal choice with cast, immobilization is given with analgesics and NSAIDS. STAGE 2 and stage 3A with ulna variance is initially treated with trail of conservative management for 3 months, if conservative therapy fails then joint leveling technique is considered. A positive ulnar variant indicates surgical management with vascularized bone grafts and external fixation is done, however this procedure does not revascularise the lunate but slows down its process of degeneration in the affected wrist, intercarpal arthrodesis, excision of lunate, carpectomies are considered primary option of management.[26]

Extracorporeal shockwave therapy is conservative treatment for osteonecrosis as it may increase the vascular endothelial growth factor in osteogenesis, and angiogenesis which allows the affected bone to revascularise .[29,30,31,32]

Keinbocks disease prognosis is highly dependent on stage of the disease.

SUMMARY

Keinbocks disease is a condition which is rare and its etiology is unknown. The case shows the importance of the diagnosis of the disease by the primary healthcare practitioner and responsible for management of keinbock's disease

REFERENCES

[1] Kienböck R. Concerning traumatic malacia of the lunate and its consequences: degeneration and compression fractures. Clin Orthop Relat Res. 1980;149:4–8.

[2] Lamas C, Carrera A, Proubasta I, Llusà M, Majo J, Mir X. The anatomy and vascularity of the lunate: considerations applied to Kienbock’s disease. Chir Main. 2007; 26: 13–20.

[3] Schuind F, Eslami S, Ledoux P. Kienbock’s disease. J Bone Joint Surg (Br). 2008;90(2):133-9.

[4] Peltier LF. The classic: concerning traumatic malacia of the lunate and its consequences: degeneration and compression fractures. Clin Orthop. 1980;149:4-8.

- [5] Ståhl F. On lunatomalacia (Kienböck's disease): a clinical and roentgenological study, especially on its pathogenesis and late results of immobilization treatment. *Acta Chir Scand.* 1947(Suppl);126:1-133.
- [6] Beredjiklian PK. Kienböck's disease. [Internet]. *J Hand Surg.* 2009 Jan;34(1):167-75.
- [7] Vandendungen S, Dury M, Foucher G, Marinbraun F, Lorea P. Conservative treatment versus
- [8] scaphotrapeziotrapezoid arthrodesis for Kienböck's disease. A retrospective study. *Chirurgie de la Main.* 2006 ;25(3-4):141-145.
- [9] Keith PP, Nuttall D, Trail I. Long-term outcome of nonsurgically managed Kienböck's disease. *J Hand Surg.*2004;29(1):63-67.
- [10] Dias JJ, Lunn P. Ten questions on Kienböck's disease of the lunate. *J Hand Surg(Eur).* 2010 Sep ;35(7):538-43.
- [11] Gelberman RH, Salamon PB, Jurist JM, Posch JL. Ulnar variance in Kienböck's disease. *J Bone Joint Surg Am.*1975;57(5);674-6.
- [12] Lluch A, Garcia-Elias M. Etiology of Kienböck's disease. *Tech Hand Up Extrem Surg.* 2011;15(1); 33-37.
- [13] Chung KC, Spilson MS, Kim MH. Is negative ulnar variance a risk factor for Kienböck's disease? A metaanalysis. *Annals Plastic Surg.* 2001;47(5):494-9.
- [14] De Smet L, Degreef I. Treatment options in Kienböck's disease. *Acta Orthop Belg.* 2009;75(6):143-4.
- [15] Botte MJ, Pacelli LL, Gelberman RH. Vascularity and osteonecrosis of the wrist. *Orthop Clin North Am.* 2004;35(3):405-21.
- [16] Freedman DM, Botte MJ, Gelberman RH. Vascularity of the carpus. *Clin Orthop Relat Res.* 2001, 383: 47-59.
- [17] Gelberman RH, Bauman TD, Menon J, Akesson WA. The vascularity of the lunate bone and Kienböck's disease. *J Hand Surg.* 1980;5:276).
- [18] Pichler M, Putz R. The venous drainage of the lunate bone. *Surg Radiol Anat.* 2003;24:372-376.
- [19] Melenhorst WBWH, Maas M, Houpt P, Overgoor MLE. A unique case of partial, radial sided lunatomalacia. *J Hand Surg(Eur).* 2010;35(7):586-8.
- [20] Coleman BG, Kressel HY, Dalinka MK, Scheibler ML, Burk DL, Cohen EK. Radiographically negative avascular necrosis: detection with MR imaging. *Radiology.* 1988, 168: 525-8.
- [21] Goeminne S, Degreef I, De Smet L. Reliability and reproducibility of Kienböck's disease staging. *J Hand Surg(Eur).* 2010 Sep ;35(7):555-7.
- [22] Lichtman DM, Lesley NE, Simmons SP. The classification and treatment of Kienböck's disease: the state of the art and a look at the future. *J Hand Surg(Eur).* 2010;35(7):549-54.
- [23] Evans G, Burke FD, Barton NJ. A comparison of conservative treatment and silicone replacement arthroplasty in Kienböck's disease. *J Hand Surg.*1986;;11(1):98-102.
- [24] Innes L, Strauch RJ. Systematic review of the treatment of Kienböck's disease in its early and late stages. *J Hand Surg.* 2010;35(5):713-7, 717.
- [25] Delaere O, Dury M, Molderez a, Foucher G. Conservative versus operative treatment for Kienböck's disease: A retrospective study. *J Hand Surg: Journal of the British Society for Surgery of the Hand.* 1998;23(1):33-36.
- [26] Takahara M, Watanabe T, Tsuchida H, Yamahara S, Kikuchi N, Ogino T. Long-term follow-up of radial shortening osteotomy for Kienböck's disease. *J Bone Joint Surg.* 2009;90;1705-11.
- [27] Salmon J, Stanley JK, Trail IA. Conservative management versus radial shortening. *J Bone Joint Surg B.* 2000;820-823.
- [28] Soucacos PN, Urbaniak JR. Osteonecrosis of the human skeleton. *Orthop Clin North Am.* 2004;35(3): xiii-xv. Pellenberg UZ. Treatment options in Kienböck's disease *Hand, The.* 2009 ;75715-726.
- [29] Alves EM, Angrisani AT, Santiago MB The use of extracorporeal shock waves in the treatment of osteonecrosis of the femoral head: a systematic review. *Clin Rheumatol.* 2009;28(11):1247-51.
- [30] Wang CJ, Wang FS, Ko JY, Huang HY, Chen CJ, Sun YC, et al. Extracorporeal shockwave therapy shows regeneration in hip necrosis. *Rheumatology.* 2008;47(4):542-6.
- [31] Wang CJ, Wang FS, Yang KD, Huang CC, Lee MSS, Chan YS, et al. Treatment of osteonecrosis of the hip: comparison of extracorporeal shockwave with shockwave and alendronate. *Arch Orthopaedic Trauma Surg.* 2008;128(9):901-8.
- [32] Furia JP, Rompe JD, Cacchio A, Maffulli N. Shock wave therapy as a treatment of nonunions, avascular necrosis, and delayed healing of stress fractures. *Foot Ankle Clin.*2010;15(4):651-62.
- [33] Taniguchi Y, Tamaki T, Honda T, Yoshida M. Rotatory subluxation of the scaphoid in Kienböck's disease is not a cause of scapholunate advanced collapse (SLAC) in the wrist. *J Bone Joint Surg(Br).* 2002 Jul ;84(5):684-7.