

Research Journal of Pharmaceutical, Biological and Chemical Sciences

Management of Mandibular Fractures with Conventional Miniplates - A Review.

Saravana Kumar*, Balakrishnan, Abu Dakir, Muthumani, NP Prabu, and Waikhom Arvind.

Department of Oral and Maxillofacial Surgery, Sree Balaji Dental College And Hospital, Chennai, Tamil Nadu-600100, India.

ABSTRACT

The management of trauma has evolved greatly over the past many years. Various bone plating have been introduced for stable fixation of mandibular fractures. The present concept of treating mandibular fractures is with non-compression mini plates which relieves the patient from a hazardous intermaxillary fixation with wires and gives better stability and osteosynthesis. When placed along the Champy's line of Osteosynthesis Miniplates gave maximum stability and Osteosynthesis. This article presents an overview of management of mandibular fractures with mini plates.

Keywords: Mandibular Fractures, Miniplates, Champy's line.

**Corresponding author*

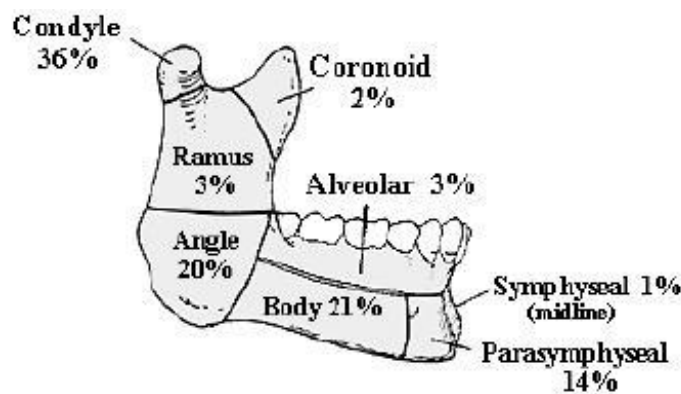
INTRODUCTION

Mandibular fractures are more common than middle third fracture (anatomical factor). It could be observed either alone or in combination with other facial fractures. Minor mandibular fracture may be associated with head injury owing to the cranio-mandibular articulation. Mandibular fracture may compromise the patency of the airway in particular with loss of consciousness. It has been found that fracture of mandible can occur with frontal impact force as low as 425 lb (190 Kg) (Condylar fracture). Fracture of condyle is regarded as a safety mechanism to the patient. Frontal force of 800-900 lb (350-400 Kg) is required to cause symphyseal fracture. Mandible is more sensitive to lateral impact than frontal one. Frontal impact is substantially cushioned by opening and retrusion of the jaw (Nahum 1975). Long canine tooth and partially erupted wisdom represent line of relatively weakness. The most significant advancements related to the management of fractures of the mandible are based on specific technical refinements in the methods of internal fixation. Recent mandibular fracture management techniques have allowed for decreased infection rates and biological stable fixation of bone segments. The present concept of treating mandibular fractures is with non compression mini plates which relieves the patient from a hazardous intermaxillary fixation with wires and gives better stability and osteosynthesis. This review article presents an overview of management of mandibular fractures with mini plates.

Literature review

History reveals that mandible fractures and treatment dates back as early as 1650 BC in papyrus by Edwin Smith. Hippocrates described the treatment of fracture to be done with gold wirings and he himself did circumferential dental wiring for mandibular fractures. In 1275 Salicetti first presented maxillomandibular fixation as a treatment for fractures of the mandibles, [1, 2] After a decade it as Gilmer who revived Salicetti's technique and practiced it clinically more efficiently in 1887. [3] Mostly throughout the 20th century intermaxillary fixation along with splints and bandages were the only modality of treatment for mandibular fractures. Few unsuccessful reports of treating mandibular fractures by open reduction with silver wires or iron loops had been reported [4, 5]. In 1976, Spiessl and others continued to advance techniques of open reduction and internal fixation (ORIF) and developed the principles now advocated by the Arbeitsgemeinschaft fur Osteosynthesefragen (Association for Osteosynthesis/ Association for the Study of Internal Fixation (AO/ ASIF) [6]. These plates were heavy and bulky. However these plates did help to achieve better stability rather than the conventional inter maxillary fixation by wirings. Even though these plating techniques had benefits of avoiding maxillomandibular fixation by wiring, including comfort, return to normal mastication and normal oral function, in reality, these heavy compression plates had a high morbidity. The neck scars were undesirable, nerve damage to both the facial and inferior alveolar nerves was common and infection of the plates frequent; a second operation to remove the plates was always necessary. The principles of heavy compression plating could not be applied to the thin bones of the upper facial skeleton. Next came the system of lag screws where big screws are attached through the fragmented segments and they are tightened to bring the fractured ends together. This system didn't show much promise and had limited use in mandibular fractures even though intraoral surgical techniques were used.

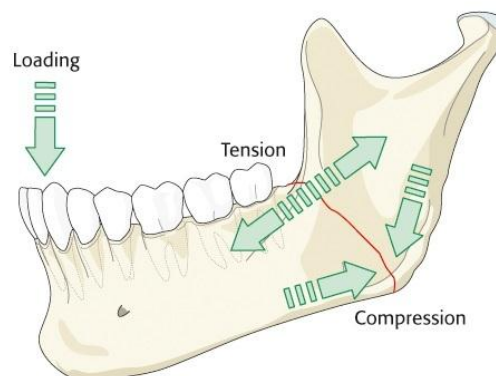
MANDIBULAR FRACTURES



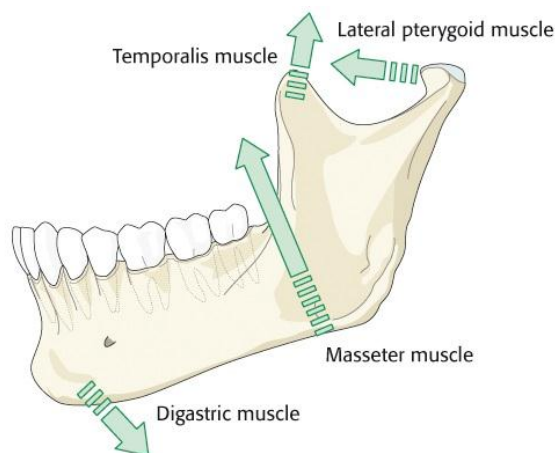
Michelet and his colleagues introduced the concept of internal fixation with small miniplates for fixing and stabilizing mandibular fractures in 1970 [7]. Champy and his co workers in 1978 modified this technique to use small, bendable and noncompression mini plates along the ideal line of osteosynthesis(8) for treating mandibular fractures. These plates were fixed with monocortical mini screws. They were not heavy. When placed along the Champy’s line of osteosynthesis they gave maximum stability and osteosynthesis. Last but not least the use of small miniplates was successfully integrated into the rest of the facial skeleton, being refined and miniaturized for the periorbital and cranial non-load bearing areas.

It is very important to know the classification of mandibular fractures. The mandible fractures can be classified by Dingman and Natvig [9] on the basis of anatomy as - midline (Fractures between central incisors), symphysis fractures (Bounded by vertical lines distal to canine teeth), parasymphysis fractures (Fractures occurring in the area of symphysis), body of mandible fractures (From the distal symphysis to a line coinciding with the alveolar border of the masseter muscles), angle fractures (Triangular region bounded by the anterior border of the masseter muscle to the posterosuperior attachment of the masseter muscles), ramus (fractures bounded by the superior aspect of the angle to two lines forming an apex at the sigmoid notch), coronoid(includes the coronoid process of the mandible superior to the ramus region) and condylar(Area of the condylar process superior to the ramus region) fractures. There are several other classifications of mandibular fractures in literature. Second most important thing is to know about the biomechanics of mandibular fractures.

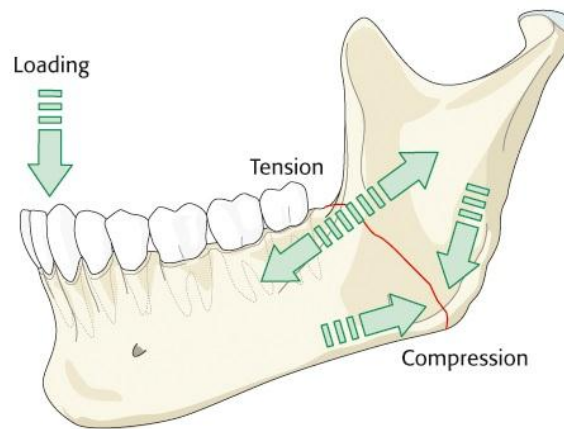
Biomechanics of the mandible is a complex topic. Forces applied to the mandible cause varying zones of tension and compression, depending on where the bite force is located. The superior portion of the mandible is designated as the tension zone and the inferior portion is designated as the compression zone.



The mandible is a hoop of bone that deforms with movement based on the origin and insertion of the muscles of mastication viz masseter, temporalis, medial and lateral pterygoid muscles.

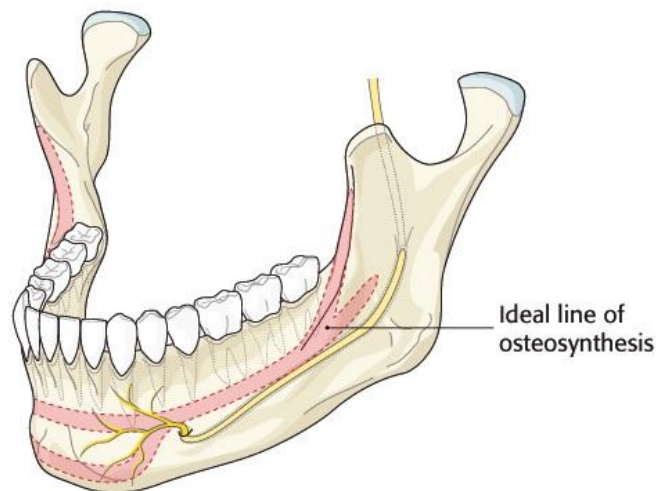


The superior border of the mandible is the tension zone and the inferior border is the compression zone.

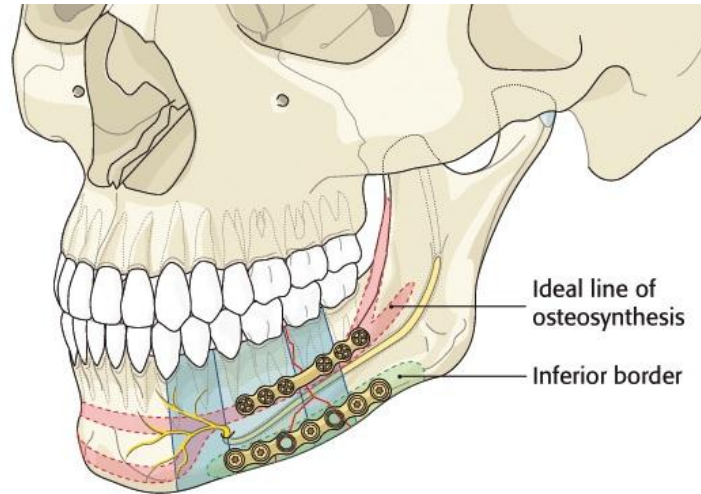


The mandible is similar to a hunting bow in shape, strongest in the midline (symphysis) and weakest at both ends (condyles). The most common area of fracture in the mandible is therefore the condylar region. A blow to the anterior mandibular body is the most common reason for condylar fracture. The force is transmitted from the body of the mandible to the condyle. The condyle is trapped in the glenoid fossa. Commonly, a blow to the ipsilateral mandible causes a contralateral fracture in the condylar region. If the impact is in the midline of the mandible, fractures of the bilateral condylar region are very common.

Champy popularized the treatment of mandible fractures with miniplate fixation along the ideal lines of osteosynthesis. This is a form of load-sharing osteosynthesis to be applied in simple fracture patterns having an acceptable amount of bone stock.



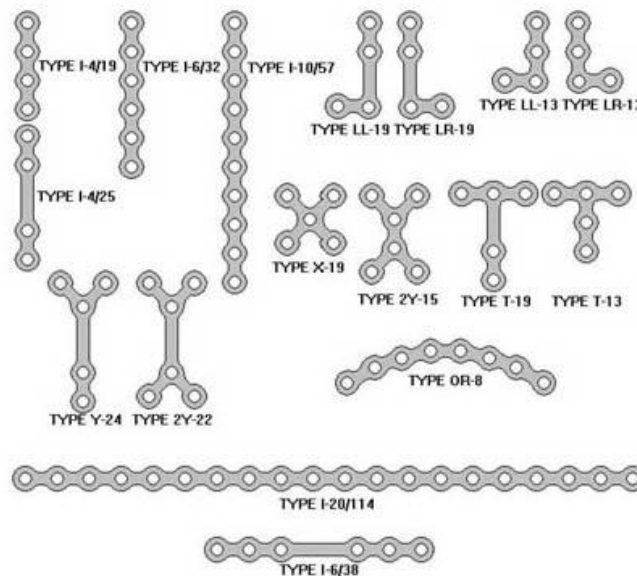
The ideal line of osteosynthesis in the body region runs at the vertical height of the tooth apices from the canine region to the oblique line. This carries into the oblique ridge which turns into the anterior outer rim of the ramus. All biomechanical models developed to date have shown that two points of fixation (ie, two plates) provide much more stability than a single one. The basal triangle decreases the bone buttressing and interfragmentary support. This condition demands a degree of stability beyond pure load sharing. The superior border plate is positioned on the ideal line of osteosynthesis. The inferior border plate is located at the base of the mandibular body in a longitudinal field below the course of the mandibular canal.



It is Champy and his coworkers who started the system of semi rigid fixation with mini plates and screws. This form of load-sharing osteosynthesis with the miniplate fixation technique popularized by Champy suggests that when the plates are placed along the ideal line of osteosynthesis they give maximum stability and proper osteosynthesis.


MINIPLATES (SEMI RIGID FIXATION)

Champy *et al.*, defined the "ideal lines of osteosynthesis" based on experiments of GEBOAS (Group of Research in Bones and Joint Biomechanics of Strasbourg) [10]. It is Champy and his coworkers who revolutionised the system of semi rigid fixation with mini plates and screws. This form of load-sharing osteosynthesis with the miniplate fixation technique popularized by Champy suggests that when the plates are placed along the ideal line of osteosynthesis they give maximum stability and proper osteosynthesis.. These plates were first introduced as stainless steel plates. It consisted of mono-cortical, juxta alveolar, and subapical osteosynthesis without compression and intermaxillary fixation using miniaturized malleable plates. Small size of the plate(thickness - 2mm), easy adaptability, easy placement, and use of intraoral approach led to increased use of mono-cortical plates in maxillofacial surgery. [11]



Introduced by Champy and his coworkers this method has been successfully used since then and underwent several modifications. However these plates can be placed by intraoral surgical approaches. The

technique suggests placing a single miniplate in the subapical region or along the external oblique ridge when fractures are posterior to the mental foramen. Anterior to the foramen 2 miniplates are used to resist the forces of torsion. In mandible fracture, an arch bar is preferred for MMF. This equates to a second line of resistance in particular with biting load anterior to the fracture line. The superior plate is inserted first in order to achieve preliminary fixation. This will prevent inadvertent displacement of the fragments during subsequent contouring and the insertion of the inferior border plate. The 1st miniplate is placed in the subapical region and the 2nd plate 5mm inferior to the first plate and fixed with monocortical mini screws of 2mm diameter. These screws are generally self tapping which comes in several lengths such as 2mm, 4mm, 6mm, 8mm and 10mm. Usually in mandible for fixing the miniplates (2 or 2.5) x 8mm or (2 or 2.5) x 10mm screws are used. These mini plates are used to stress shield the forces of tension and torsion. At the same time it allows the biomechanical forces of compression to work which is the advantage of this technique.



DISCUSSION

Several factors guide the management of mandibular fractures like dental and orthopaedic principles like reduction of the fracture site to its correct anatomical position, restoration of pre morbid occlusion and rigid immobilization of the fractures which facilitates healing, optimal and early restoration of function, prevention of infection, malunion or nonunion of fracture [12]. Management of mandibular fractures started with maxillary mandibular fixation with stainless steel wires. After that decade has passed and the treatment modality advanced from wiring to lag screws to miniplates. Champy et al first introduced the semi rigid mini plates. Michelet et al (1973) began experimenting with monocortical non- compression miniplates. Using a simple cantilever beam model, Champy et al showed that the superior mandibular border was subjected to tension and splaying, and the inferior border was subjected to compression. The transition zone between the areas of tension and compression has been referred to as a “line of zero force” running along the inferior alveolar nerve. Champy’s experiment with miniplates further delineated the “ideal line of osteosynthesis” within the mandible. The miniplate uses the tension-banding principle as described by Champy et al [8] A single miniplate seemed to be more successful (overall complication rate, 7%) than the lag screws (14%) in the management of mandibular angle fracture. However, Luhr and AO/ASIF advocates felt that miniplates did not offer adequate stabilization of the fractures, thereby necessitating the need of further inter-maxillary fixation. [13] Farmand and Dupoirieux presented 3-D plates with quadrangular shape formed by joining two miniplates with interconnecting crossbars [13]. Because of the quadrangular configuration of the plates, they provided good stability and resistance to torsional forces. Easy use, good resistance against torque forces, and compact form of the plates were some of their advantages. The author in Sree Balaji Dental College And Hospital studied 100 cases of mandibular fractures for past 1 year consisting of 41 parasymphysis fractures, 35 body fractures, 17 angle fractures and 7 symphysis fractures and all were treated with conventional mini plate fixation. As per Champy’s ideal line of osteosynthesis two plates were placed in symphysis and parasymphysis fracture region and single mini plate in the body and angle fracture. 5% of total patients underwent for infection followed by plate removal and 2% suffered parasthesia which was present for 5 and 6 months respectively after which the patients regained the sense.



REFERENCES

- [1] Salicetti G. *Cirurgia* 1275.
- [2] Prevost N. Translation of Salicetti's *Cirurgia*. Lyons, France 1492
- [3] Gilmer TL. *Arch Dentistr* 1887; 4: 388
- [4] Buck G. *Annalist NY* 1846; 1:245.
- [5] Dorrance GM, Bransfield JW. *The History of Treatment of Fractured Jaws*, vols 1 and 2 Washington, DC, 1941.
- [6] Spiessl B. *New concepts in maxillofacial bone surgery*. Springer-Verlag, Berlin 1976
- [7] Michelet FX, Deymes J, Dessus B. *J Maxillofac Surg* 1973; 1: 79.
- [8] Champy M, Lodde JP, Schmitt R, et al. *J Maxillofac Surg* 1978;6: 14.
- [9] Dingman RO , Natvig P. *Surgery of facial fractures*, Philadelphia,1964, WB Saunders.
- [10] Champy M, Pape HD. The strasbourg miniplate osteosynthesis. In: Kruger E, Schilli W, editors. *Oral and Maxillofacial Traumatology*. vol. 2. Berlin: Quintessence; 1986. p. 19-43.
- [11] Cawood JI. *Br J Oral Maxillofac Surg* 1985;23:77- 91.
- [12] Harold Kai Tu, David Tenhulza. *J Oral Maxillofac Surg* 1985; 43: 585-589
- [13] Luhr HG. *Otolaryngol Clin North Am* 1987; 20:573-606.
- [14] Farmand M, Dupoirieux L. *Rev Stomatol Chir Maxillofac* 1992; 93: 353-7.