

# Research Journal of Pharmaceutical, Biological and Chemical Sciences

## Retrocuspid Papillae: A Study on Its Prevalence.

Rajashekhara BS<sup>1</sup>, Manjunatha BS<sup>2\*</sup>, Bhavana Dave<sup>3</sup>, and Rachappa MM<sup>4</sup>.

<sup>1</sup>Faculty, College of Dentistry, Salman Bin Abdulaziz University, AlKharj, Kingdom Of Saudi Arabia.

<sup>2</sup>Faculty of Dentistry, College of Dentistry, Al-Hawiyah, Taif-21944, University of Taif, Kingdom of Saudi Arabia.

<sup>3</sup>Department of Pediatric and Preventive Dentistry, K M Shah Dental College and Hospital, Sumandep Vidyapeeth, Pipariya-391760, Vadodara, India.

<sup>4</sup>Department of Paediatric Dentistry, Child Dental Health, Oman Dental College, P.O.Box 835, Postal Code 116, Muscat, Sultanate of Oman.

### ABSTRACT

Localized gingival nodule may be a clinical sign of a pathologic process of the gingiva. These may be a normal variation or a simple reactive lesion to metastatic tumor to the gingiva. Retrocuspid papilla is one such structure, occurs as a small round to oval soft nodule represents an anatomic variation. The aim of the present study was to assess and compare prevalence of retrocuspid papillae (RCP) in school children of Vadodara city. The present study was conducted by the Department of Pedodontics and Preventive Dentistry, KM Shah Dental College and Hospital, Vadodara, India. A total of 1320 school children categorized into group A consisted of 1020 preschool children aged between 3 to 5 years and group B consisting of 300 school children aged between 7 to 9 years of Vadodara city were taken for the study. Sixty seven (67%) of children in group A showed the presence of retrocuspid papillae and in group B only 30 % children recorded the presence of retrocuspid papillae. Bilateral presence of RCP was found in 89% children in group A and 76% in group B. Studying in detail and establishing some more facts about this normal anatomic structure will be definitely useful in clinical diagnosis of lesions affecting the gingiva.

**Keywords:** Anatomic variation, gingival nodule, mandibular canine, retrocuspid papilla

*\*Corresponding author*

## INTRODUCTION

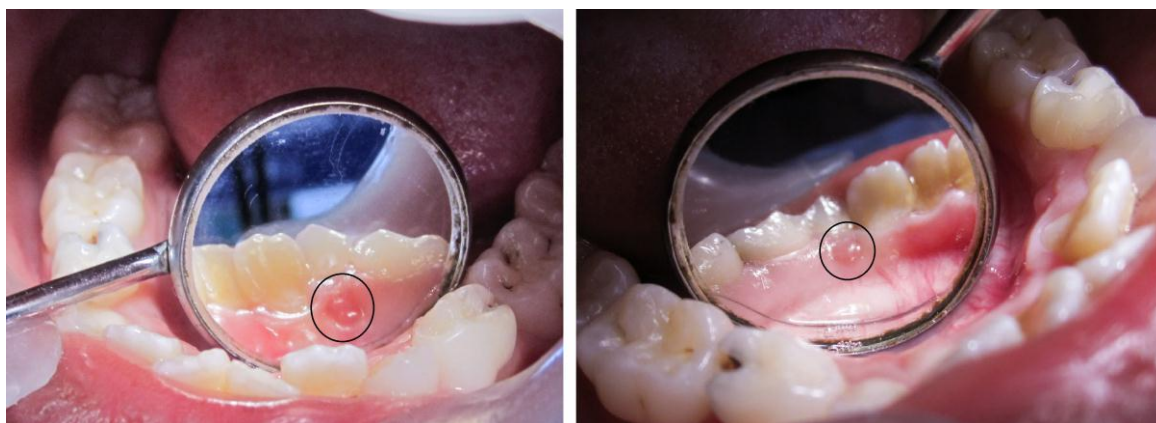Retrocuspid papilla (RCP) is a constrained round or oval, dome-shaped sessile nodule found on the lingual surface of the mandibular cuspids near the mucogingival junction. RCP was first described by Hirschfeld in 1947 and are may be linked to the vasculature in the region [1]. Few authors believed that RCP is an analogous to the incisive papilla and represents a focus of fibro vascular connective tissue covering the osseous foramen of a nutrient blood vessel [2,3]. Since data on Retrocuspid papillae in the pediatric population are very few, this study was undertaken in the Indian population. The aim of the present study was to examine the prevalence of RCP in two groups of pediatric population from India.

## MATERIALS AND METHODS

The present study was conducted between October 2010 to March 2011 over a period of 45 days by the Department of Pedodontics and Preventive Dentistry, KM Shah Dental College and Hospital, Vadodara, India. A total of 1320 children aged between 3 to 5 years and 7 to 9 years residing in Vadodara city were included in the study. The children in the study are taken from Dept OPD, camps and screening at schools and anganwadis. The Department has also adopted some schools to improve the dental awareness and oral hygiene habits among these children. Prior to the beginning of the study, the study proposal was submitted and approval was obtained from the Institutional ethical committee. Consent of parents of children was also obtained for the study. The oral examination was done in 1320 children for the prevalence of unilateral or bilateral retrocuspid papillae (Figure 1). Each patient was examined by one examiner with at most sterile conditions to eliminate the interexaminer bias (variability). The data was collected; compiled and statistical analysis was done. Children with the following findings were excluded from the study.

- Localized, multiple and generalized gingival swellings.
- Gingival enlargement in patients with systemic diseases.

**Figure 1: Clinical images showing presence of prominent retrocuspid papilla (close-up view).**



## RESULTS

Simple statistical analysis using Chi-square test was done to compare the results. The following observations were observed from the study:

- Children of group A showed 67% (683 individuals) presence of retrocuspid papillae. In group B, only 30% (90 individuals) children were having retrocuspid papillae (Figure 2).
- Bilateral presence of RCP was noted in 89% and 76% in group A and group B respectively (Figure 3).
- Among boys, 70 % in group A and 31% in group B were having retrocuspid papillae. In girls, 64% in group A and 29% in group B had RCP (Figure 4).
- Bilateral presence of RCP of about 91% and 72% was noted amongst boys in group A in group B separately. About 87% and 77% in group A and group B girls had bilateral retrocuspid papillae (Figure 5).

Figure 2: Bar chart showing presence of RCP in group A and B.

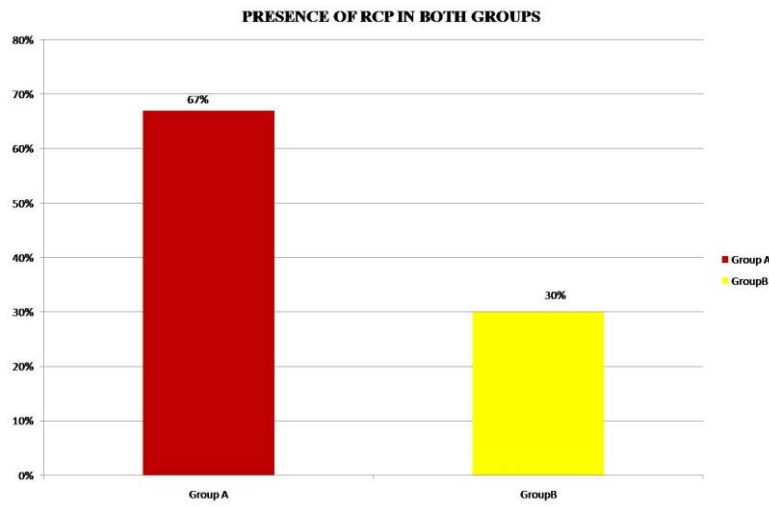


Figure 3: Photograph showing both unilateral and bilateral presence of RCP in group A and B.

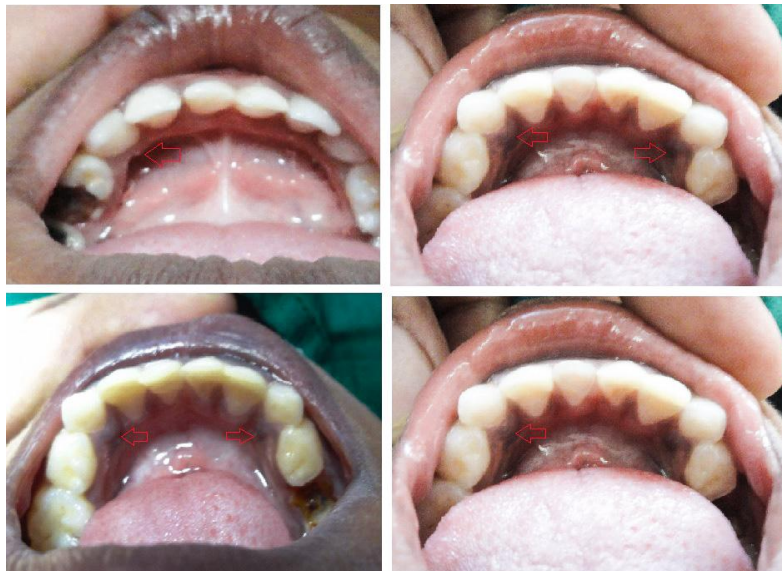

Figure 4: Bar chart showing percentage of RCP in males and females in both group A and B.

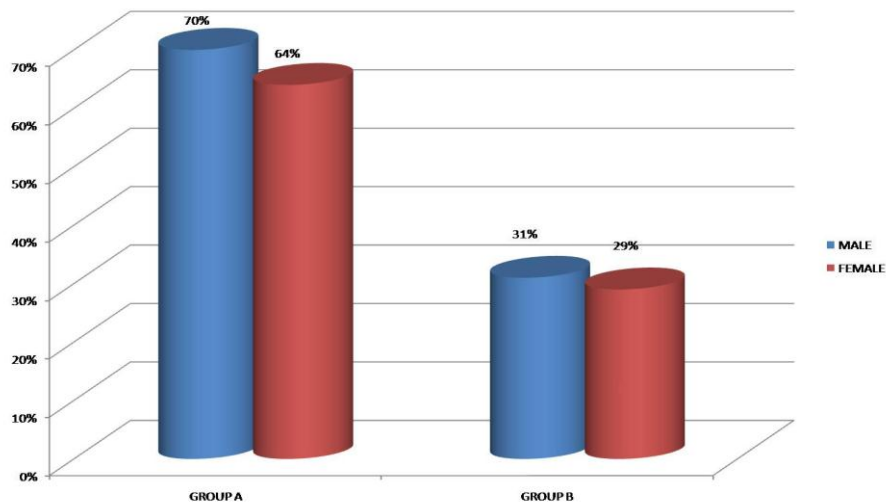
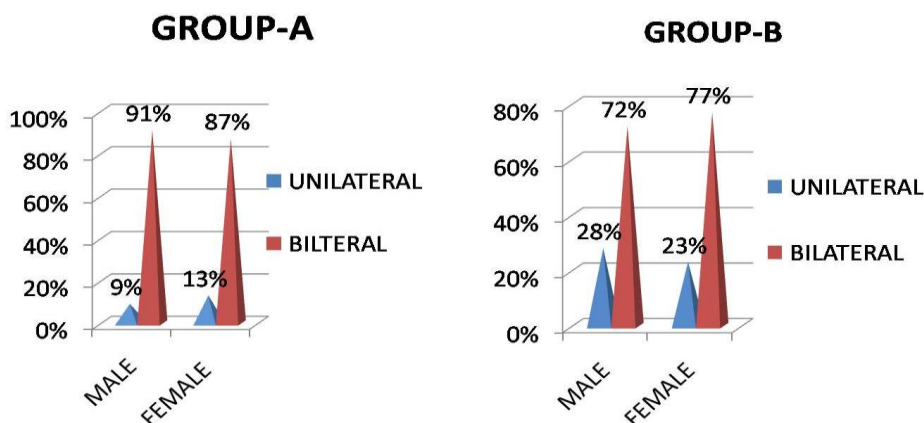


Figure 5: Bar chart showing uni/bilateral presence of RCP in males and females in both group A and B.



### DISCUSSION

A retrocuspid papilla are soft, small, smooth, well defined round or oval swellings seen on the lingual aspect of lower gingiva near the cuspid or canine teeth. Retrocuspid papilla is very common and usually pink in color measuring about 1-3mm [4]. These are usually documented clinically and sometimes mistaken for other pathologic conditions such as gingival abscess or draining sinus from tooth especially if inflamed. Absence of any source of infection is much easier to make the clinical diagnosis of RCP [5]. In the present study, we rule out pathologies mimicking RCP by assessment for any carious tooth, periodontal diseases as well as mobility of teeth.

Hirschfeld reported the presence of RCP in 99% of children between 3-16 years old [1]. Berma [5]net al and Everett et al found approximately 51.7% prevalence for RCP in young children [5,6]. Easley and Weis reported 85.2% of RCP in an Israeli population of less than 26 years. The prevalence of RCP was 38.5% in younger and 11.3% in adult group [7,8]. This indicated greater occurrence of retrocuspid papillae in younger age group children. However, there were only few studies that provided information about RCP for which this prevalence could be compared. Few authors stated that a possible genetic influence on clinical presence of RCP [5].

The present study revealed that 67% of children were having retrocuspid papillae in 3-5 years age group and 30% in 7-9 age groups. Earlier studies have indicated that prevalence of RCP decrease with increasing age [5,7,8]. Hence preschool and school children are taken for the study. We thought that group A consist of of children of 3 to 5 years will have a complete set of primary dentition and in group B having children of 7 to 9 years of age group show the mixed dentition. Keeping these in mind, we tried to correlate the relation between the prevalence of RCP and the type of dentition.

According to a hypothesis related to formation of RCP is from fusion of blood vessels of encircling plexus of cuspids of deciduous and permanent teeth with blood vessels of lingual mucosa [1,9]. Others postulated that RCP is predominantly composed of thin walled vessels represent a type of hamartomatous formation [6].

According to Hirschfeld, decreased RCP with increased age may be due to functional changes such as mastication, abrasion, attrition, and atrophic changes [1].

Clinical importance of RCP is that they may mimic few pathological gingival conditions such as pyogenic granuloma, peripheral giant cell granuloma, irritation fibroma, gingival cyst, localized periodontal abscess, or a tumor metastasis to the gingiva and are to be differentiated [2,8].

RCP are distinguished at a microscopic level by stellate fibroblasts within the fibrous connective tissue [10]. Histologically, RCP shows acanthosis with elongated rete-ridges, enhanced vasculature with little

inflammation [1,6]. However, Hedin et al [11] reported that as RCP is poorly documented entity when submitted as surgical biopsies. They are considered to be a normal variation of healthy tissue and should not be biopsied.<sup>10</sup> Due to its clinical appearance and distinctive location, RCP don't require biopsy, but irritation fibroma and GCF both necessitate biopsy for definitive diagnosis [4].

In the present study, a total of 1320 children of aged between 3 years to 9 years were taken and histological examination after biopsy was practically not feasible in such young individuals for clinically distinct, normal anatomical structure (RCP). Furthermore, our intention was to know the prevalence of RCP. So biopsy was not considered in the study.

Among the most recent studies on RCP, Hedin et al performed immunohistochemical (IHC) staining with factor XIIIa antibody and results revealed reactive spindle-shaped cells mainly localized in the connective-tissue papillae [11].

In the present study, RCP were analyzed for unilateral or bilateral presence and observed that bilateral presence was significantly more among all the age groups. Our observation was in contrast to Landry et al and they suggested RCPs were present significantly more often among females in the Honduras group and unilateral distribution was more frequent than a bilateral distribution.<sup>3</sup> In Nicaragua group, a bilateral distribution was most prevalent [3]. The authors believe that the present study is the largest sample of pediatric population to be reported in the literature so far. None of the previous reported studies have considered such a large pediatric sample involving two different age groups.

#### CONCLUSION

The prevalence of RCP in the 3-5 years sample was high as compared to 7-9 years populations and found to be more common of about 67% among the younger age group of 3-5 years. This study highlighted influence of ethnic variation among various populations. RCP is considered to be a "normal anatomical structure" or an "anatomical variation" of the gingiva that regresses with age and requires no treatment.

#### ACKNOWLEDGEMENTS

The authors wish to thank all school teachers for their uncomplaining co-operation given during the study. They also wish to thank Mr.Javli, statistician, KLE Institute of Dental Sciences and Hospital, Belgaum, India for helping with the statistical analysis and interpretation.

#### REFERENCES

- [1] Hirschfeld I. Am J Orthod 1947;33:447-57.
- [2] Buchner A, Merrell PW, Hansen LS, Leider AS. J Periodontol 1990;61(9):585-9.
- [3] D'Aoust P, Landry R, Ganske R, Carrier J. Ont Dent 1991;68(8):39, 43, 45 passim.
- [4] Neville BW, Damm DD, Allen CM, Bouquot JE. Oral and maxillofacial pathology. 2<sup>nd</sup> edition. Philadelphia (PA):WB Saunders;2002:439-40.
- [5] Berman FR, Fay JT. Oral Surg Oral Med Oral Pathol 1976;42(1):80-5.
- [6] Everett FG, Hall WB, Bennett JS. Periodontics. 1965;59:81-3.
- [7] Easley JR, Weise RW. J Dent Child 1970; 37:523-526.
- [8] Gorsky M, Begleiter A, Buchner A, Harel-Raviv M. Oral Surg Oral Med Oral Pathol 1986; 62:240-243.
- [9] Levin MP, Cutright DE. J Periodontol 1977;48:464-6.
- [10] Farlex.<http://www.medical-dictionary.thefreedictionary.com/retrocpuspid+papilla>. Mosby's Dental Dictionary, 2<sup>nd</sup> edition. Elsevier: 2008.
- [11] Hedin CA, Gerner L, Larsson A. Scan J Dent Res 1994;102:290-4.