

# Research Journal of Pharmaceutical, Biological and Chemical Sciences

## Study of Diabetic Retinopathy in End Stage Renal Disease.

Ajith S\*.

Department of Ophthalmology, Sri Siddhartha Medical College, Tumkur-572107, Karnataka, India.

### ABSTRACT

Eye is a mirror that reflects pathological changes occurring in many organs of the body. Chronic renal failure is irreversible and progressive process that result in End stage renal disease [ESRD] where patient depend on renal replacement for survival<sup>1</sup>. In this study we are looking for diabetic retinopathy in patients with ESRD of diabetic origin. To record the stage of retinopathy in end stage renal disease patients of diabetic origin and record the progress of retinopathy at the end of 6 months and 12 months in these patients. The study was done in Sri Siddhartha Medical College, Tumkur from May 2014 to May 2015. This is a prospective non randomized study of 50 patients who were diagnosed end stage renal disease of diabetic etiology with or without hypertension. Majority of patients were in age group of 55-60 years accounting 60%, men 32% and women 28%. All patients were known to be diabetic for more than 5 years. Patients who were diabetic for about 11-15 years were the majority. All patients of NIDDM with ESRD had retinopathy.

**Keywords:** Diabetic Retinopathy, Diabetic Nephropathy, End Stage Renal Disease, Diabetes mellitus.

*\*Corresponding author*

## INTRODUCTION

Eye is a mirror that reflects pathological changes occurring in many organs of the body. Numerous systemic disorders affect both eye and kidney. Examination of eye is an indispensable part of clinical assessment of patient with renal disorders.

Chronic renal failure is irreversible and progressive process that result in End stage renal disease [ESRD] where patient depend on renal replacement for survival [1].

Richard bright in 1836 first associated renal disease with blindness [2]. In ESRD 80% of patients will have secondary hypertension [3]. Ocular morbidity may be due to coexisting risk factors like hypertension, diabetes, uremia and anemia. The ophthalmologist may be consulted for a variety of reasons about the patients whose problem appear renal. Diabetes is the most common disorder with ocular and renal manifestations [4]. Blindness due to proliferative retinopathy or maculopathy is approximately 5 times in diabetic patients with nephropathy compared with non albuminuric patients [5]. Conjunctival degenerative changes eg: Pinguicula are frequently seen in chronic renal failure [6]. inflammatory reactions of conjunctiva and episclera can be associated with sudden marked raise in serum calcium [7]. In India majority of end stage renal disease patients are of type 2 diabetes and 5% of diabetic patients die of end stage renal disease. In this study we are looking for diabetic retinopathy in patients with ESRD of diabetic origin.

### Aims and Objectives

- To record the stage of retinopathy in end stage renal disease patients of diabetic origin.
- To record the progress of retinopathy at the end of 6 months and 12 months in these patients.

### MATERIALS AND METHODS

The study was done in Sri Siddartha Medical College, Tumkur from May 2014 to May 2015. This is a prospective non randomized study of 50 patients who were diagnosed end stage renal disease of diabetic etiology with or without hypertension. The onset of end stage renal disease was restricted to be less than 6 months.

The following criteria were to be noted to fulfill the diagnosis of ESRD.

- Raised BUN about 100mg/dl at time of diagnosis
- Raised serum creatinine about 8mg/dl.
- Signs and symptoms of uremia for more than 3 months.
- Known diabetic for more than 5 years with retinopathy.
- Only NIDDM patients were included.

Patients with underlying etiology other than diabetes and hypertension were rejected. Patients underwent hemodialysis once a week. The type of dialysis is bicarbonate and few patients underwent acetone dialysis.

### Ophthalmological examination

Ophthalmological examination is made twice and whenever the patient reports with diminished vision. Complete ophthalmological evaluation included Best corrected visual acuity, slit lamp examination, Direct ophthalmoscopy, Fundus examination with 90D lens and slit lamp, fundus photographs and FFA suspicion of neovascularization, Diabetic retinopathy is classified as per ETDRS classification.

**RESULTS**

**Table 1: Age and Sex Distribution of the Study Population**

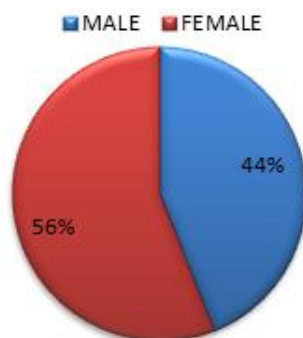
Age	No of patients -male	percentage	No of patients - female	percentage
55-60	16	32	14	28
61-65	2	4	8	16
66-75	4	8	6	12
Total	22	44	28	56

Majority of patients were in age group of 55-60 years accounting 60%, men 32% and women 28%.  
 Figure 1: Sex Distribution of the Study Population

**Table 2: Duration of Diabetes Mellitus in Relation to ESRD**

Duration of DM[Years]	No of patients
5-10	6
11-15	28
16-20	14
>20	2

Only NIDDM patients were taken for study. All patients were known to be diabetic for more than 5 years. Patients who were diabetic for about 11-15 years were the majority.



**Table 3: Severity of Diabetic Retinopathy at Base Line**

Severity of diabetic retinopathy	NO. of Eyes	Percentage
Mild NPDR	0	0
Moderate NPDR	8	8
Severe NPDR	44	44
Very severe NPDR	24	24
Early PDR	18	18
High risk PDR	6	6

All patients of NIDDM with ESRD had retinopathy. Non proliferative retinopathy in the form of severe retinopathy is the commonest retinopathy. No new vitreous haemorrhage or retinal detachment was noted.

**Table 4: Severity of Diabetic Retinopathy at Follow up.**

Severity of diabetic retinopathy	NO. of eyes	%
Mild NPDR	0	0
Moderate NPDR	8	8
Severe NPDR	40	40
Very severe NPDR	28	28
Early PDR	18	18
High risk PDR	6	6

Majority of eyes were of severe NPDR. No new vitreous haemorrhage or retinal detachment noted.

### DISCUSSION

This study was a nonrandomized prospective including 50 patients with ESRD on dialysis of diabetes mellitus origin conducted in Sri of Siddhartha medical college. Patients were referred from the department of nephrology for detailed ophthalmological checkup. Renal failure was diagnosed with the criteria mentioned in patients and methodology. All patients underwent routine haemodialysis.

Frequency of retinopathy and nephropathy is explained in WESDR study. An increasing frequency of retinopathy was found increasing duration of diabetes. Prevalance rose sharply from 13.61% in those with diabetes of less than 5 years to 95.3%.

In the Indian study John et al it was found that out of 86% of people with diabetic retinopathy 20% of the people had proliferative changes. Whereas in this study the distribution of retinopathy was mild NPDR 0%, moderate NPDR 8%, severe NPDR 44%, very severe NPDR 24%, early PDR 18% and high risk PDR 6%.

### CONCLUSION

End stage renal disease of NIDDM is always associated with retinopathy as both are microvascular damage of the same disease. Severe NPDR is most common retinopathy. Patients between 55-60 yrs who are known to be diabetic are commonly associated with ESRD and retinopathy. ESRD is found commonly in females.

### REFERENCES

- [1] Weather et al Oxford text book of medicine Vol3 Oxford Univ 1996;3294-5.
- [2] Duke elders S. Dohree JH, System of Ophthalmology Vol10, 1<sup>st</sup> Edition, Chapter 4, 315-47.
- [3] Stein JH et al, Internal medicine 3<sup>rd</sup> edition USA little Brown and Comp 1990;809-10.
- [4] Duane JD, Duane's Clinical Ophthalmology Vol.5. Revised Ed USA; Harper and Row 1987; Chapter 31; 1-2.
- [5] Schmechel H, Heinrich U. Diabetes Metabol 1993;19;135-42.
- [6] Cohen S et al. Queensland J Med 1974;43;281-917.
- [7] Klassen-Broekman, Van Bijsterveld. J Ophthalmol 1995;5;7-12.