

Research Journal of Pharmaceutical, Biological and Chemical Sciences

Rare Presentation of Salivary Gland Swellings.

Magesh Kumar J*, P Suresh Babu, P Sasikumar, and KS Ravishankar.

Department of General Surgery, Sree Balaji Medical College & Hospital, Bharath University, Chromepet, Chennai – 600044, Tamil Nadu, India.

ABSTRACT

Cystic lesions of the parotid gland are uncommon and it comprises approximately 5% of all salivary gland tumours. Cystic development as part of specific neoplasms of the salivary glands is well recognized, including those that occur in the pleomorphic adenoma, Warthin's tumour, mucoepidermoid carcinoma, acinic cell carcinoma, and the adenoid cystic carcinoma. As far as parotid concerned superficial parotidectomy is the treatment of choice in benign conditions. Haemangioma of salivary gland especially parotid is quite common in paediatric population, but is exceedingly rare to find it in submandibular gland of adult males. Hemangiomas may arise from the gland proper, or by invasion of subcutaneous blood vessels into the gland structure. As far as submandibular gland haemangiomas are concerned, the treatment of choice is surgical resection. Our case report is of two different cases where the salivary gland swellings presented in the anatomical region of the salivary glands the diagnosis was made as parotid duct cyst and cavernous hemangioma of submandibular gland.

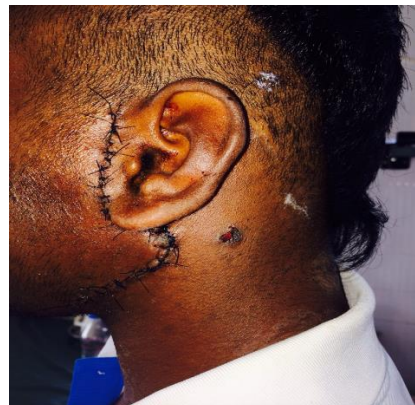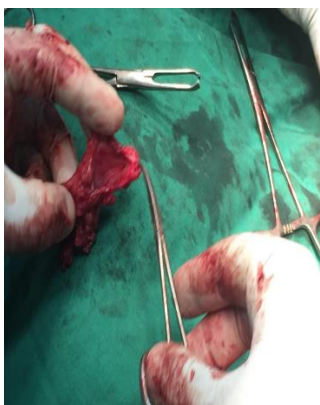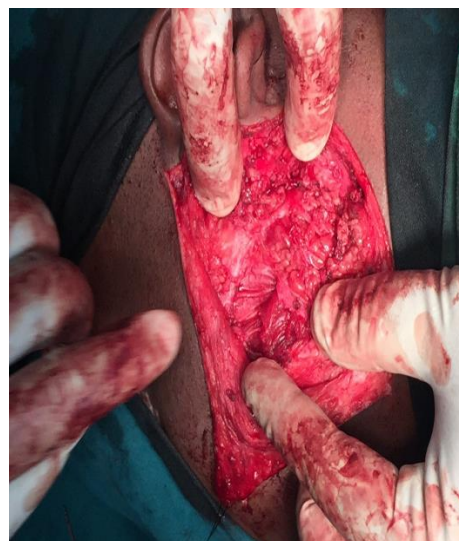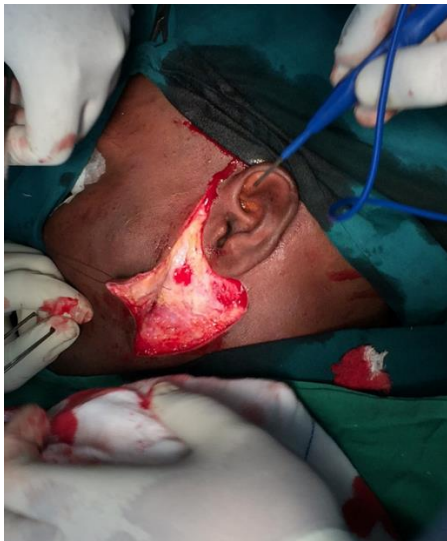Keywords: salivary gland, parotid cyst, submandibular gland hemangioma

**Corresponding author*

CASE REPORTS**Case -1**

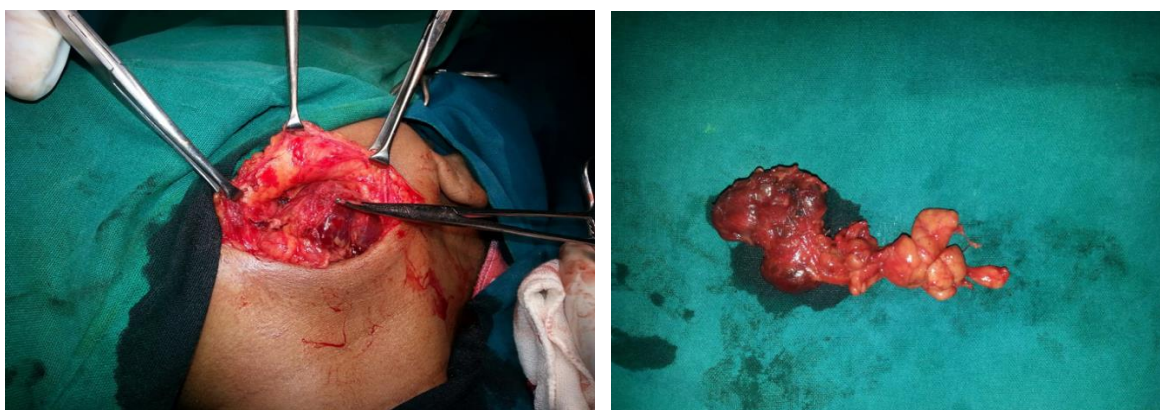
A 22 year old Patient came with C/O swelling in the Lt. parotid region since childhood, attained to the present size ,No H/O pain, No H/O Difficulty in movements of jaw or eating food, No H/O Trauma ,No H/O Fever, No other systemic complications & comorbidity. On Examination A mobile soft swelling of 3*3cm present in the left parotid region in front of the tragus. There is no local warmth, tenderness, Transillumination is negative, the Skin pinchable is over the swelling, Ear lobe lifted up on the left side, Skin over the swelling normal, No lymph nodes palpable, Oral cavity looks normal, Movements of jaw normal. All baseline investigations done which are normal, USG suggestive of – cystic swelling of the parotid gland probably - retention cysts, lymphangiomatous lesion in left parotid region.

CECT is suggestive of - ?dermoid cysts, lymphangiomatous malformations, other benign cystic tumours, FNAC – fluid aspirated, inconclusive. With this picture we planned for excision biopsy along with superficial parotidectomy, it was performed and the excised specimen sent for histopathology which is suggestive of salivary duct cyst. Post-operative stay was uneventful and patient was discharged without any complications .

**Case -2**

A 40 year old female came with the c/o swelling in the submandibular region since 2 years, no evidence of fever & trauma. There is no h/o excessive saliva secretion, No h/o weight loss & loss of appetite. There is no h/o difficulty in jaw movements. On

examination a ovoid shaped swelling of 4*3 cm is present in the left submandibular region, which is soft in nature not tender and no increase of temperature and not freely mobile. Skin over the swelling is normal. Movements associated with jaw are normal and oral cavity looks normal. No other swelling present in the neck. No lymph node palpable. All baseline investigations were done. USG of the swelling shows a large herterogenous lesion predominantly cystic with increased vascularity seen inferior to the submandibular gland probably – lymphangiomatosis, cystic hygroma. With this scenario excision biopsy of the swelling along with the gland removal was planned and done. Excised specimen histopathology is suggestive of capillary cavernous angioma⁽⁷⁾ . post-operative stay was uneventful.



DISCUSSION

Cystic lesions of the parotid gland are uncommon and it comprises approximately 5% of all salivary gland tumors. Cystic development as part of specific neoplasms of the salivary glands is well recognized, including those that occur in the pleomorphic adenoma, Warthin's tumor, mucoepidermoid carcinoma, acinic[8] cell carcinoma, and the adenoid cystic carcinoma. They can occur as a result of traumatic severance of salivary gland ducts, partial or complete blockage of the excretory ducts, or stasis of salivary flow in ducts. Many of them represent cystic components of neoplasm. In most cases, the appearance of these cysts on computed tomography (CT) or magnetic resonance imaging (MRI) is not specific enough to allow the differentiation of a simple parotid cyst from a brachial cleft cyst [7] . Most lesions are slowly enlarging painless swellings affecting a single gland. Hence, the diagnosis is seldom made preoperatively and sometimes a superficial parotidectomy is needed. The clinical diagnosis of parotid cyst is often based on a slowly enlarging painless lump in the parotid region, the examination not always confirming the cystic nature of the lesion. Investigations are important for diagnosis and treatment planning of these lesions. Fine needle aspiration biopsy (FNA)[4] is useful in certain cases. Ultrasound is useful in showing cystic nature of the lesion. Management of such lesions should be superficial parotidectomy when a conservative approach cannot safely remove the lesion.

The submandibular triangle normally contains the submandibular gland, lymph nodes and fat[6]. Haemangioma of salivary gland especially parotid is quite common in paediatric population, but is exceedingly rare to find it in submandibular gland of adult males. In the salivary glands two main types of haemangiomas occur : cavernous and capillary. Capillary type is lobulated, lacks a capsule, is purplish in colour and infiltrates the gland involved. Microscopically solid masses of cells and multiple anastomosing capillaries replacing the acinar structure of the gland are seen. The cavernous type is formed by dilated blood vessels or sinusoids lined by endothelium[3]. It is also devoid of a capsule and is infiltrative in nature.

Hemangiomas may arise from the gland proper, or by invasion of subcutaneous blood vessels into the gland structure. There is no confirmative non-invasive investigation exists. Plain X-ray may show multiple calcified phelebolith. Ultrasonography reveals heterogeneous, hypoechoic lesions with calcified pheleboliths[5].CT scan shows tumour with enhancing quality of blood vessels.Sialography and angiography have been mentioned and can be done. Nuclear medicine imaging with 99m Tc red blood cell scintigraphy[5] has also been reported useful in differentiating sialadenitis from hemangiomas. As far as submandibular gland haemangiomas are concerned, the treatment of choice is surgical resection. Other modalities of treatment include laser, cryotherapy, embolization and corticosteroid [1-9].

CONCLUSION

Thus a proper clinical examination and meticulous surgical steps is essential to establish the diagnosis. Parotid duct cyst are quite rare. And capillary cavernous hemagiomas are rare in the submandibular region. This case is been reports for its rarity. we should be able to distinguish it from the benign tumors of the parotid gland as it may greatly affect the treatment plan.

REFERNCES

- [1] Rajendran R. Tumors of the Salivary Glands. In: Rajendran R, editor. Shafer's Textbook of Oral Pathology. 5th ed. Amsterdam: Elseiver; 2007. pp. 309–56.
- [2]. Mcmenamin M, Quinn A, Barry H, et al: Cavernous haemangioma in the submandibular gland masquerading as sialadenitis. Oral Surg Oral Med Pathol Oral Radiol End 1997; 146-8
- [3]. Brad WN, Douglas DD, Carl MA, Jerry EB. 2nd ed. Philadelphia: Saunders; 2002. Oral and Maxillofacial Pathology; pp. 389–436.
- [4]. P. Mukunyadzi, "Review of fine-needle aspiration cytology of salivary gland neoplasms, with emphasis on differential diagnosis," American Journal of Clinical Pathology, vol. 118, pp. S100–S115, 2002.
- [5]. Bradley M, Stewart I, King W, Metreweli C. The role of ultrasound and 99mTc RBC scintigraphy in diagnosis of salivary gland hemangioma. Br J Oral maxillofac Surg 1991; 29: 164-5.
- [6]. Bialek EJ, Jakubowski W, Zajkowski P, Szopinski KT, Osmolski A. US of the major salivary glands: Anatomy and spatial relationships, pathologic conditions, and pitfalls. Radiographics. 2006;26:745–63.
- [7]. Benson BW. Salivary gland radiology. In: White SC, Pharoah MJ, editors. Oral Radiology, Principles and Interpretation. 6th ed. Maryland Heights: Mosby Elseiver; 2009. pp. 578–96.
- [8]. Baker LL, Dhillon WP, Hieshma GB, DowdCF, Freiden IJ. Haemangiomas and vascular malformations of the head and neck: MR Characteristics. Am J Neuroradiol, Mar-Apr 1993; 14(2): 307-14.
- [9]. Seifert G. Mucoepidermoid carcinoma in a salivary duct cyst of the parotid gland. Contribution to the development of tumours in salivary gland cysts. Pathol Res Pract. 1996;192:1211–7.