

# Research Journal of Pharmaceutical, Biological and Chemical Sciences

## Clinical Presentation of Abdominal Tuberculosis in Indian Scenario: A Retrospective Study.

**Parvathy R Menon, Srikanth Nambiar, Girish Thunga\*, Vinay Patidar, Kanav Khera, and  
Yogesh Vohra.**

Department of Pharmacy Practice, Manipal College of Pharmaceutical Sciences, Manipal, Karnataka, India.

### ABSTRACT

Tuberculosis (TB) is global public health emergency with 24% of all cases being reported from India. TB of the abdomen is often vague and non-specific in presentation and a great mimic of other diseases. With the objective of characterizing the demographic, clinical and treatment features of abdominal TB, all patients, without an age restriction with diagnosis of abdominal TB in the years of 2011 and 2012 were included. Median age was found to be 35. Abdominal pain (68.9%), fever (44.4%), weight loss (44.4%) were most frequent symptoms in the study group. The highest proportion of patients had peritoneal TB (46.3%). We found that 69% of the patients had hyponatremia at their first presentation. The study showed male predominance and showed no relation with HIV co-infection. A significant number of patients with abdominal TB too exhibit hyponatremia, and might be a valuable data just as it is in pulmonary and meningeal TB. The absence of a specific tool for the diagnosis of abdominal TB along with its proclivity to mimic other diseases makes its diagnosis tricky. However, once diagnosed correctly; it remains a disease well managed with medical therapy alone.

**Keywords:** Extrapulmonary tuberculosis; Peritoneal Tuberculosis; Gastrointestinal Tuberculosis; Abdominal tuberculosis.

*\*Corresponding author*

## INTRODUCTION

Tuberculosis (TB) is an age-old, re-emerging communicable infectious disease which is nothing less than a health crisis. Mycobacterium tuberculosis was identified as the organism causing TB by Robert Koch in 1882 [1] was a breakthrough as was the discovery of anti-mycobacterial drugs like streptomycin, isoniazid, rifamycins, and pyrazinamides, which led to a new era in prevention and treatment of this infection. The current scenario as reflected in the WHO report 2014, ballpark 90 lakh people to have developed TB and 15 lakh to have died from this disease in the year of 2013. The fast developing resistance pattern of the bacteria and the lack of viable new drugs in the treatment of TB are two crucial issues, which along with the co-epidemic of HIV/TB may have attributed to the comeback of this disease. Tuberculosis today is far more than an infectious disease endemic to Asia and Africa, it is a global public health problem. Having said so, India still accounts for 24% of the total reported cases of TB and thus has been given the highest global priority by the WHO. Though the death toll from the disease has been declining every year, the numbers are still alarmingly high with increasing cases of drug resistance calling for keen and close look into this disease.

Based on the clinical manifestations of TB, it may be of the pulmonary or extra pulmonary form, common being the pulmonary presentation. Extra pulmonary TB (EPTB) is defined simply as tuberculous infection and disease of organs excluding lungs. These include mycobacterial infection of pleura, genito-urinary tract, lymph nodes, meninges, joints and bones, abdomen, skin, etc [2]. Of these, abdominal TB (AT) is placed 6th with regard to the frequency of occurrence. The presentation of disease is often obscure and non-specific making the diagnosis difficult. Also, AT is a great mimic of infectious and non infectious diseases like inflammatory bowel disease, lymphoma, cervical carcinoma, advanced ovarian cancer, colon cancer, pancreatic cancer, Yersinia infection, actinomycosis and amebomas [3] [4] [5]. For these reasons, diagnosis of AT remains a challenge, missing or delaying the diagnosis of which can lead to serious rise in mortality.

## AIM

The objective of the study was to characterize the demographic and clinical features and treatment pattern of abdominal TB.

## METHOD

The study involved collection of data retrospectively from the medical records archived in records department of Kasturba Medical College on patients admitted with the diagnosis of Abdominal TB.

Diagnosis was made when:

- 1) Tubercles /caseating granulomas were observed
- 2) AFB was visualised in the biopsy sample or ascetic fluid
- 3) A positive response to empirical anti-tuberculosis drugs was noticed.

Between January 2011 and December 2012, 2600 cases of TB were reported, of which 90 were confirmed cases of Abdominal TB. All patients, without an age restriction who were diagnosed with abdominal TB in Kasturba Medical College in these 2 years were included in this study. The data of these patients were retrospectively analysed with regard to all aspects of diagnosis and treatment. For data analysis, SPSS version 20.0 was used.

However, in some patients, the diagnosis was not confirmed; they defaulted or requested for early discharge. These patients were not included in the sample for analysis due to incomplete data on fundamentals.

## RESULTS

Of the 2600 cases of TB in the years of 2011 and 2012, 90 (3.4%) cases of TB were confirmed as that of Abdominal TB. In a sample of 90 patients, 56.2% were male patients, of Indian race and the median age was observed to be 35 years. Remaining details have been tabulated below.

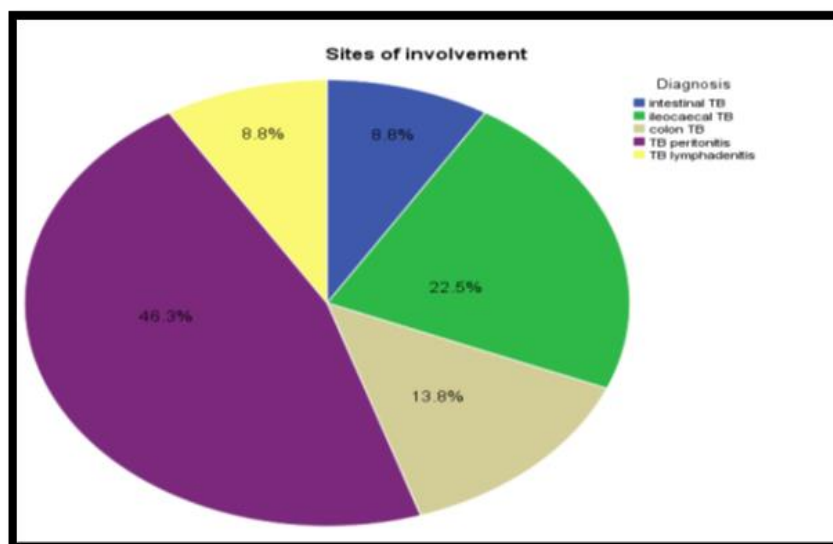
**Table 1: Demographic Features of Abdominal Tuberculosis patients**

Demographic Parameter	Comment
Median Age ± IQR (years)	35±28
Age range (years)	7 to 76
Gender	
Male; n (%)	51 (56.2%)
Female; n (%)	39 (43.8%)
Race	Indian
Tuberculosis in population ( number of cases)	2600
Percentage of cases confirmed as AT	3.46%
Personal History	
Pulmonary TB	6
HIV	3
Family history of TB	3

**Table 2: Clinical Features of Abdominal Tuberculosis**

Symptoms	Number (%)	Signs	Number (%)
Abdominal Pain	62(68.9)	Ascites	42(46.7)
Fever	40(44.4)	Abdominal tenderness	25(27.8)
Weight loss	40(44.4)	Bowel obstruction	12(13.3)
Abdominal distension	38(42.2)	Abdominal mass	6(6.7)
Vomiting	29(31.1)	Hepatomegaly	6(6.7)
Loose stools	25(26.7)	Fistula- in- Ano	2(2.2)
Cough	21(23.3)	Neck stiffness	1 (1.1)
Fatigue	15(15.6)		
Breathlessness	6(6.7)		
Night sweats	2(2.2)		

Pain in abdominal, fever and weight loss with emaciation were most frequent symptoms as seen in the patient group. Ascites (identified by free fluid or shifting dullness) and tenderness on palpation were observed in many patients during physical exam.



**Figure 4.1: Sites of involvement of Abdominal TB**

\*We found TB peritonitis to have the highest incidence, sometimes associated with lymph node disease. The common site of the GIT involved was the ileocaecal region, followed by colon and intestine. We did not come across any case involving stomach or visceral organs like liver or pancreas.

**Table 3: Preliminary biochemical investigations pertinent to AT**

Routine Biochemical Investigations	Number (Percentage)
Hematology	
Elevated ESR	70 (77.8%)
Leucocytosis	26 (29%)
Hypoalbuminemia	54 (60%)
Hyponatremia	62 (69%)
Mean sodium ± SD	130.94 ± 7.8

Elevated erythrocyte sedimentation rate (ESR) and hypoalbuminemia (Albumin < 3.5 g/dL) are indicators of inflammation in AT. However, white blood (WBC) count was not elevated in a significant proportion of patients in spite of AT being an infectious disease.

**Table 4: Initial diagnostic and specific confirmatory tools**

Initial diagnostic Technique	Number (Percentage)
Mantoux Test	
Reactive	10 (11.1%)
Non- reactive	16 (17.7%)
Not performed	64 (71.2%)
CXR abnormality	25 (27.8%)
Imaging	
USG done	56 (62.2%)
CT performed	25 (27.7%)
Type of AT	Confirmatory diagnostic tools
Peritoneal TB	<ul style="list-style-type: none"> <li>• Imaging techniques</li> <li>• Ascitic fluid analysis</li> <li>• Laparoscopy</li> </ul>
TB of the GIT	<ul style="list-style-type: none"> <li>• Imaging Techniques</li> <li>• Endoscopy</li> </ul>

Initial phase of diagnosis involves routine laboratory and radiographic imaging techniques. Confirmation of AT is carried out depending on the part of abdomen affected as has been enlisted above. Laparoscopy was often considered as the last resort for obtaining a confirmatory diagnosis, with some turning into a laprotomy.

Category I include the initiation phase of treatment with Isoniazid (H), Rifampicin(R), Pyrazinamide (z) and Ethambutol (E) for the first two months followed by the continuation phase of treatment with Isoniazid (H) and Rifampin(R) for the next 4 months. Though most patients received Cat I medications with T.Pyridoxine 20/40 mg, there were exceptions which are enlisted in the following table.

**Table 5: Various treatment regimens in AT**

Factors concerning selection of regimen	Alteration in regimen
Treatment naive patients	Category I medications
Patients with a history of pulmonary TB (the reactivation of which had caused AT)	HRZE and streptomycin(S) during initiation phase.
Anti-tuberculosis therapy (ATT) induced hepatitis	Levofloxacin, Streptomycin and Ethambutol.
Relapsed patient	Category II medications*
Concurrent alcoholic liver disease	HRE and Streptomycin

\*Cat II includes 2 months of HRZES, then a month of HRZE continued by 5 months of HRE.

Out of 16 adverse drug reactions reported, 13 were ATT induced hepatitis. A case of ATT induced gastritis, streptomycin induced ototoxicity, and isoniazid induced psychosis each were the others.

## DISCUSSION

Abdominal tuberculosis (AT) covers TB of the gastrointestinal tract and the peritoneum, and rarely the infection of associated lymph node and intra-abdominal organs like liver, spleen, pancreas, etc. [6] AT accounted for 3.4% of the total number of TB cases in the time period of study. In developed countries, TB is often attributed to co-infection with HIV, an aging population or trans-global migration [7][8] [9] while in developing countries like India, TB is often tied to low socioeconomic status, illiteracy, overcrowding and lack of accessible healthcare. Only 3 patients were co-infected with HIV in our sample population, which is in contradiction to the data from developed countries where HIV has prominent connection with TB.

Certain studies show a female predominance in AT incidence [10, 11]. In contrast, our study showed that 56.2% patients diagnosed with AT were males. Median age was found to be 35 years with age ranging from 7 to 76 with no bimodal distribution, suggesting that it is a disease more prevalent in young adults.

With regard to site of infection; peritoneum was most frequently affected followed by ileocaecum, colon, lymph nodes and intestine and no case with solid organ involvement was found. AT may be primary in origin or secondary to the re-activation of infectious foci elsewhere in the body. Ingestion of sputum in patients with active pulmonary TB, reactivation of TB after years in those whose have a history of pulmonary TB from hematogenous spread from primary focus or spread from adjacent organs or a lymphatic spread [12,13]. The features of AT like transverse ulcers, peritoneal tubercles, thickening of the peritoneum, matted mesenteric lymph nodes and omental thickening were observed on biopsy in our study. It has been reported that caseating granulomas, ulceroconstrictive/ulcerative type of lesions on histology examination are useful for study [14].

Symptoms may last for weeks to months, or sometimes for years. AT symptomatology is either constitutional (fever, fatigue, night sweats and loss of weight) or localised. Pain in abdomen, fever, weight loss with emaciation and vomiting were the most common symptoms in the study.

We came across cases which deviate from the typical presentation of AT. A case with reduced appetite, abdominal pain and distension was diagnosed to have gastritis after series of upper endoscopies and treated with rabeprazole until a CT taken revealed inflammatory thickening of bowel with ulcerations. The diagnosis was made after recurrent symptoms, and called out to be abdominal TB. A Case with elevated CA 125 on further investigations revealed to show cystic lesions, omental caking and adnexal masses with extensive peritoneal deposits. Thus, abdominal tuberculosis imitates malignancies too.

Because of its varied and non-specific presentation, it mimics gastritis, inflammatory bowel disease and malignancies, and only a high index of doubt can lead to timely diagnosis. Also, differential diagnosis of AT is an onerous task often requiring distinction between Crohn's disease and AT. It is a critical and at the same times a difficult task to differentiate Crohn's disease and Abdominal tuberculosis. While steroids are the choice of treatment for Crohn's, they retard the immune response against bacilli in AT, making misdiagnosis dangerous.

Though most laboratory and radiographic studies were rarely diagnostic, high ESR and hypoalbuminemia were found in 77.8% and 60% respectively which are in keeping with the inflammatory process. Hypoalbuminemia is a result of inflammation, but can also be contributed by inadequate protein intake as a significant pool of patients was poorly nourished. Leucocytosis was observed only in 29%, and thus may not be a reliable indicator of AT.

Hyponatremia is described as reduced serum sodium (Na) concentration below 136 mEq/L and a serum sodium concentration lower than 115 mEq/L is considered as severe hyponatremia, which is often life-threatening [15, 16]. There are early reports of hyponatremia in patients with active TB where inappropriate antidiuretic hormone secretion has been thought to lead to water retention along with sodium depletion. [17]. These were followed by reports of SIADH induced hyponatremia in pulmonary, miliary and central nervous system TB [18]. However, there are no convincing reports of hyponatremia in AT. In this study, though we have not evaluated patients for the etiology of hyponatremia, 69% of the patients had hyponatremia at their first presentation and were asymptomatic. Mean sodium was  $130.94 \pm 7.8$  (ranging from 100 to 142). This

shows that a significant number of patients with abdominal TB too exhibit hyponatremia, and might be a valuable data just as it is in pulmonary and meningial TB [19].

A total of 56 patients out of 90 underwent ultrasound scan which revealed abnormalities like ascites, fluid filled dilated loops, mesenteric lymphadenopathy and omental thickening, whereas only 25 patients took a CT scan. Radiography of abdomen seldom provides a diagnosis; however, a CT scan identifies caseating enlarged lymph nodes, thickening of omentum and other peritoneal changes and obstruction of bowel due to strictures. If the symptoms and/or radiographic evidence suggested tuberculosis of the gastrointestinal tract, an upper GI scopy or a colonoscopy was performed as required. It was useful in making diagnosis of AT of the gastrointestinal tract by visualisation of ulcero-proliferative lesions or tubercles followed by biopsy. In peritoneal TB, examination of peritoneal fluid has proven to be of great help. Classical signs suggesting TB in aspirated ascitic fluid was straw coloured, exudative (with protein greater than 2.5g/dL) often with a low serum ascetic albumin gradient (SAAG), low glucose and ADA above 36 U/L (SAAG). Lymphocytic predominance and low glucose were almost always found. Adenosine deaminase (ADA) was found to be elevated in 67.5 % of patients with peritoneal TB and is a sensitive marker for its diagnosis since ADA is believed to rise in tuberculous ascetic fluid due to stimulation of T- cells by antigens produced by the bacteria. Laparoscopy is been used for diagnosis of AT since 1970's with good specificity when etiology of ascites is undiagnosed [20, 21]. Bhargava *et al* [21] studied 86 patients with exudative ascites of which 38 had tuberculosis, and found that visual appearances are more helpful than histology or culture. In our study, 36 patients underwent laparoscopy, in which tubercles on the peritoneum with or without adhesions were noted.

The standard EPTB treatment regimens as per RNTCP guidelines are based on the categorisation into "serious ill" or "not seriously ill". Abdominal TB falls under the category of seriously ill, and it is recommended to follow Category I medication for a period of 6 months without any changes in HIV positive patients. A 6-month short -course chemotherapy (SCC) regimen, which is same as Cat I medications was found to be as effective as the standard 12-month regimen of H and E with streptomycin for the first 2 weeks [23]. Conventional therapy of anti-tuberculosis drugs included 2 months of HRZE and 4 months of HR was prescribed in most patients. However, streptomycin was added whenever the patient had a history of pulmonary TB.

#### STUDY LIMITATIONS

One of the limitations in this study is the retrospective nature of the data collection and analysis; however, in no way was the study objective compromised. Secondly, not all tests were performed in all patients either because they were not necessary or because of financial restrictions. Also, the inability to confirm diagnosis of AT in certain cases can be viewed as a limitation.

#### CONCLUSION

In a study based on surgical findings, a correct clinical diagnosis of AT could be only made in 50% of the cases [24] and Hoon [25] reported 34% accuracy of diagnosis based on clinical features. Never the less, this scenario has improved with high ADA as a finding in ascetic fluid and use of laparoscopy for diagnosis of AT, but the process of its diagnosis is still tough. No single test or procedure serves as a gold standard for the diagnosis of AT. Another worrisome development is the finding of resistance to H and R, two primary anti-tuberculosis drugs. However, once diagnosis is made in a timely manner, AT remains a disease that can be well managed with medical therapy alone rarely requiring surgical intervention.

#### REFERENCES

- [1] [http://nobelprize.org/nobel\\_prizes/medicine/laureates/1905/koch.html](http://nobelprize.org/nobel_prizes/medicine/laureates/1905/koch.html)
- [2] World Health Organization (WHO). Treatment of Tuberculosis. Guidelines for National Programmes, 3rd ed. WHO/CDS/TB 2003.313. Geneva, Switzerland: WHO, 2003.
- [3] Yavuz A, Bulus H, Aydin A, Coskun A. Turk J Gastroenterol 2012; 23(1): 95-7.
- [4] Mukhtar AU. Cent Afr J Med 2000; 46(2): 44-5.
- [5] Micha JP, Brown JV, Birk C, Van Horn D, Rettenmaier MA, Goldstein BH. Eur J Gynaecol Oncol 2007; 28(4): 316-8.
- [6] Lazarus AA, Thilagar B. Dis Mon 2007; 53:32-8.



- [7] Marshall JB. Am J Gastroenterol 1993; 88: 989–99.
- [8] Kapoor VK. Postgrad Med J 1998; 74: 459-467.
- [9] Horvath KD, Whelan RL. Am J Gastroenterol 1998; 93: 692-696.
- [10] Singhal A, Gulati A, Frizell R, Manning AP. Eur J Gastroenterol Hepatol 2005; 17: 967-971.
- [11] Bolukbas C et al. BMC Gastroenterol 2005;5: 21
- [12] Kapoor VK. Ind J Tub 1991; 38: 119
- [13] Sharma MP, Bhatia V. Indian J Med Res 2004; 120: 354-76.
- [14] Vij JC, Malhotra V, Choudhary V, Jain NK, Prasad G, Choudhary A, Gulati P. Indian J Tub 1992; 39:213-20.
- [15] Adroque HJ, Madias NE. N Engl J Med 2000; 342(21):1581-9.
- [16] Nzerue CM, Baffoe-Bonnie h, You W, Falana B, Dai S. J Natl Med 2003; 95(5):335-43.
- [17] Chung DK, hubbard WW. Am Rev Respir Dis 1969; 99(4):595-7.
- [18] Cockcroft DW, Donevan RE, Copland GM, Ibbott JW. Can Med Assoc J 1976; 115(9):871-3.
- [19] Singh BS, Pataki AK, Deb M. Indian Pediatr 1994; 31(11):1345-50.
- [20] Trujillo NP. Gastroenterol 1976; 71:1083–5.
- [21] Wolfe JH, Behn AR, Jackson BT. Lancet 1979; 21:852–3.
- [22] Bhargava DK, Kushwaha AK, Dasarathy S, Shriniwas P. Gastrointest Endosc 1992; 38: 571-574.
- [23] Balasubramanian R et al. Int J Tuberc Lung Dis 1997; 1(1): 44-51.
- [24] Das P, Shukla HS. Br J Surg 1976; 63: 941
- [25] Hoon JR, Dockerty MB, Pemberton JM. Int. Abstr Surg 1950; 91: 417.