

Research Journal of Pharmaceutical, Biological and Chemical Sciences

The Effectiveness of Laser Therapy on Pain and Function in FBS: A Case Report.

Animesh Hazari¹, Radhika Jadhav¹, Shyamasunder Bhat N.², and G Arun Maiya^{1*}.

1-Department of Physiotherapy, SOAHS, Manipal University, Manipal, Karnataka, India.

2-Department of orthopedics, KMC, Manipal University, Manipal, Karnataka, India.

ABSTRACT

Failed Back Syndrome (FBS) is a resultant of lumbar laminectomy which cannot give the expected results to the patients and surgeons. Fail back syndrome can also be called as Fail Back Surgery Syndrome (FBSS). Early tissue mobilization and scar formation is very important for early functional recovery. Neural Scarring is one of the important complications that are responsible for FBS. Low Level Laser Therapy (LLLT) has been used for tissue and scar healing. The main aim of the study was to assess the effects of LLLT on FBS. A 60 year male developed FBS as he underwent laminectomy and discectomy for IVDP at the level of L4-5, L5-S1 and was complaining of pain during day today activities. Examination revealed pain and tenderness over the same level. Pain at rest was experienced which increased on daily activities. On examination the pain was found to be ischemic in origin with no neural involvement. Plantar pressure analysis suggested high pressure on right heel. These findings lead to decreased functional outcome, quality of life and also participation in social activities. Patient was treated with low level laser therapy (LLLT), 78 Hz for 3 min with cluster probe (3.4J/cm², EC LASER- wavelength 632.8nm, power output 30mw) followed by strengthening program. There was a significant reduction in pain and tenderness. Results showed 70% reduction on VAS (10 pre- treatment and 3 post treatment) and also there was an improvement in the plantar pressure weight distribution and hence the gait pattern. From results we can conclude that LLLT is effective in improving chronic pain caused due to FBS and it is also responsible for improving weight distribution. LLLT helps to increase vascularity and decrease neural scarring thereby reduces pain and improves gait pattern

Keywords: FBS, neural scarring, chronic pain, LLLT.

**Corresponding author*

INTRODUCTION

Failed Back Surgery (FBS) is a resultant of lumbar laminectomy which does not meet the pre-surgical expectation of the patient and the surgeon [1]. It is diagnosed as a syndrome because of its heterogeneous group of causes [2]. The estimated global prevalence of unsuccessful surgeries in lumbar disk is 20%-40% [3]; which ultimately results into FBS. Fail Back Syndrome can also be called as Fail Back Surgery Syndrome (FBSS). The most common manifestation of this disorder includes persistent or recurrent low back pain which may or may not be associated with sciatica.

'Neural Scarring' is one of the important complications that are responsible for FBS. Early tissue mobilization and scar formation is very important for early functional recovery. Formation of scar on the skin is usually asymptomatic, however scar generated deeper and surrounding the nerves can generate few symptoms. Neural scarring can eventually cause pain as a result of scar contraction which impinges on nerve root. Also, the fragment of the disc can cause nerve root compression due to scarring if not removed completely. Previous studies have reported some delayed onset of severe symptoms related to FBS due to scar tissue formation around retained fragments [2].

Low Level Laser Therapy (LLLT) is a non-thermal mean that affects biological system by acting both at tissue as well as cellular level [4]. LLLT has been extensively used for tissue and scar healing on external wounds and ulcers with a higher degree of scientific evidence as it is proposed to have analgesic, anti-inflammatory and bio-stimulating effect [5]. However the beneficial effects of LLLT therapy on neural scarring following FBSS has not been studied or reported. Therefore the study aims to clinically assess the beneficial effects of LLLT on FBS.

The case report presented here in which Low Level Laser Therapy (LLLT) showed satisfactory result to improve chronic pain caused by FBS.

CASE HISTORY

A 60 year male came to Laser clinic, Kasturba Hospital, Manipal, with complain of chronic back pain which was affecting his day today activities. He had a past history of IVDP at the level of L₄-L₅ and L₅-S₁, 15 years ago. In the event, he underwent laminectomy and discectomy at the same level. After six months following surgery, he started feeling pain over L₅-S₁ and over left ischial tuberosity she also experienced weakness in left lower extremity. As the pain was not consistent in last 15 year, he did not take any medical consultancy. However, pain aggravated in last 2 months, and therefore he came for medical consultancy. The demographics of the patient are as follows: age-60 years, weight-60Kg and height-155 cm.

CASE FINDINGS

Objective examination revealed a pain score of 8 out of 10 on the VAS scale and mild tenderness was present over L3, L4 and L5 on palpation but there was no neural involvement. The sensory examination was normal whereas motor examination revealed slight weakness of extensor hallucis on left side. These all factors affected his quality of life. Plantar pressure analysis was also performed using static foot scanner I-Step Aetrex USA which suggested high pressure on right heel as shown in the figure 1 below:

Fig1: Plantar pressure analysis before intervention

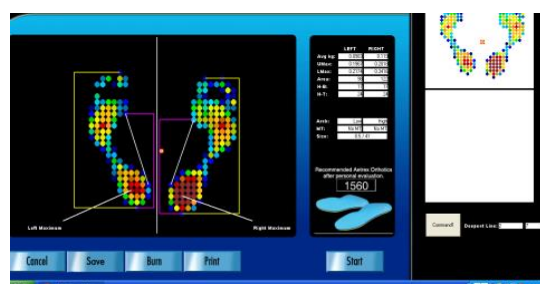
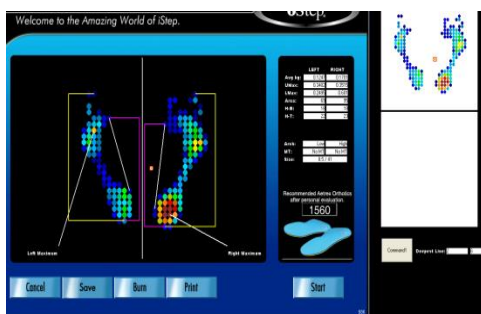


Fig2: Plantar pressure analysis after one month follow up (Significant reduction in overall values can be seen).



CASE INTERVENTION PLAN

Focus of the treatment included the following components:

- Decrease pain
- Improve weight distribution on foot

The treatment modality included moist heat on at low back following which the low laser therapy (LLLT) was given at lower back and left ischial tuberosity for 10 sessions at a calculated therapeutic dose of 78 Hz for 3 min with cluster probe (3.4J/cm², EC LASER- wavelength 632.8nm, power output 30mw).

Gradually strengthening exercises were also incorporated as the pain on VAS came to 5/10. Targeted muscle groups included core strengthening for transverse abdominis, Upper lower back extensors, lower limb abductors and intrinsic muscles of the feet. Patient was advised to use MCR foot wares for plantar pressure reduction. Patient was followed after 3, 6, 9 and 12 weeks to assess the recovery.

RESULTS

Re-assessment of pain on VAS suggested a significant reduction of pain on fifth day (5/10), and 10th day (3/10) following LLLT treatment. On palpation no tenderness was found and the plantar pressure distribution also improved with lower peak value as shown in figure2 below.

DISCUSSION

Based on above findings and results it can be interpreted that LLLT was effective in reducing pain and tenderness in FBS case. Our results are suggestive towards using LLLT in cases like these where it could show positive action both at cellular as well as tissue level. Irradiation with LLLT resulted into the stimulation of cellular metabolism which gave the secondary effect on pain reduction. In this case, the root cause of pain was the neural scarring without neurological involvement which responded well to the LLLT. Therefore, our results supports the study done by Jimbo K et al. in 1998 which concluded that application of LLLT to injured nerve caused drop in action potential and prevented excessive scar formation [6]. LLLT is also responsible for improving capillarization through regeneration of injured nerve. Pain reduction due to LLLT irradiation is also because of its analgesic action which is well documented in literature. LLLT inhibits A and C neural fibers by altering axonal flow and inhibiting neural enzyme. The Systematic review done by Marienke van Middelkoop (2011) also supported the role of LLLT for chronic non-specific low back pain. Laser normalizes biological functions at cellular level by stimulating oxidative phosphorylation and enhancing ATP formation [7].

In our results, we also found that there was a significant improvement in the weight distribution pattern. The reduction in peak plantar pressure and even distribution could be attributed to improved blood supply to lower extremity following LLLT therapy and intrinsic foot muscle strengthening exercises. Also, low back pain can itself be a factor for altered weight distribution (Fig.1) and since pain improved with LLLT, the plantar pressure distribution could have demonstrated a better pattern (Fig.2). In pre-intervention we can see the unequal weight distribution because of pain in low back which was radiating to left ischial tuberosity. So,

maximum weight bearing area is right heel with darker color coding (red). Whereas in post intervention we can see that the patient has started weight on left foot also with lighter color coding (blue). However the, improvement in weight distribution cannot be solely because of reduction in pain. Factors like improved blood circulation, plantar tissue mobility, intrinsic muscle strengthening and a sense of well-being with greater neural input could also have influenced these findings. Ultimately all these factors were responsible to improve her quality of life.

CONCLUSION

From the above case findings and results we can conclude that LLLT is effective in improving chronic pain caused due to FBS and it is also responsible for improving weight distribution. Therefore LLLT can be used in such similar cases on scientific basis in clinical practice even though very rare documentation regarding the effectiveness of LLLT on these populations is present.

REFERENCES

- [1] Robert J. Gatchel, ABPP, Brandy Miller, Candidate, and Leland Lou; Failed Back Surgery Syndrome. manuscripts\miller-brandy-rjg-fbss.403\June 22, 2010
- [2] Flávio Freinkel Rodrigues, Diego Cassol Dozza, Claudio Russio de Oliveira, Ricardo Gomes de Castro. *Arq Neuropsiquiatr* 2006; 64 (3-B):757-761
- [3] Hua SE and Levy RM, Benyon HT, Srinivasa G, Borsook D, Malloy RE, and Strichartz G. Spinal cord stimulation for failed back surgery syndrome; *Essentials of Pain Medicine and Regional Anesthesia*. Philadelphia, PA. Churchill Livingstone. 1999, 237-241
- [4] Hashmi J T, Huang YY, osmani BZ, Sharma SK, Naseer MA, Hamblin MR. *PM R* 2010; S292- S305
- [5] Lin F, Josephs SF, Alexandrescu DT, Ramos F, Bogin V, Gammill V, et al. *J Trans Med* 2010; 8:16.
- [6] Jimbo K, Noda K, Suzuki K, Yoda K. *Neurosci Lett* 1998;240: 93–96.
- [7] Baker KG, Robertson VJ, Duck FA. *PhysTher* 2001;81(7):1351–1358
- [8] Marienke van Middelkoop, Sidney M. Rubinstein, Ton Kuijpers, Arianne P. Verhagen, Raymond Ostelo, Bart W, KoesMauritsW, van Tulder. *Eur Spine J* 2011;20:19–39.