

Research Journal of Pharmaceutical, Biological and Chemical Sciences

Multiple Branching Variation of Celiac Trunk with Clinical Importance: A Case Report.

**Naveen Kumar, Ravindra Swamy*, Satheesha Nayak B, Jyothsna Patil, and
Ashwini Aithal P.**

Department of Anatomy, Melaka Manipal Medical College (Manipal Campus), Manipal University, Manipal, Karnataka,
INDIA 576104

ABSTRACT

Aberrant branching pattern of celiac trunk or its branches is not uncommon. Nevertheless, many of its notable variations were found to be clinically significant. We report herein a case of variant branching pattern of celiac trunk giving rise to five branches; two of them are inferior phrenic arteries and a separate branch to the body of pancreas as variant additional pancreatic branch. In addition, the left hepatic artery was arising from the left gastric artery. Aberrant branches supplying the abdominal structures may pose a difficulty for surgeon operating in the region and may lead to iatrogenic vascular accidents.

Keywords: celiac trunk, inferior phrenic artery, pancreatic branch, variation

**Corresponding author*

Case Report

A variant branching pattern of coeliac trunk was observed in a male cadaver of about 60 years of age. Celiac trunk was giving rise to two additional aberrant branches other than normal three branches. One of these unusual branches ascended cranially and supplied the inferior surface of diaphragm on left side, replacing the left inferior phrenic artery. Celiac trunk at its distal end gave rise to another aberrant branch, which descended caudally behind the pancreas and the splenic vein to supply the lower border of body of the pancreas. In addition to this, the left gastric artery gave an aberrant branch which passed from the left side of the caudate lobe of liver and entered the liver near the porta hepatis, thus replacing the left hepatic artery (Figure 1). The same aberrant artery gave origin to small branch which passed cranially and supplied the lower end of esophagus. Common hepatic artery continued as hepatic artery proper which formed the right hepatic artery but failed to give rise to left hepatic artery (Figure 2).

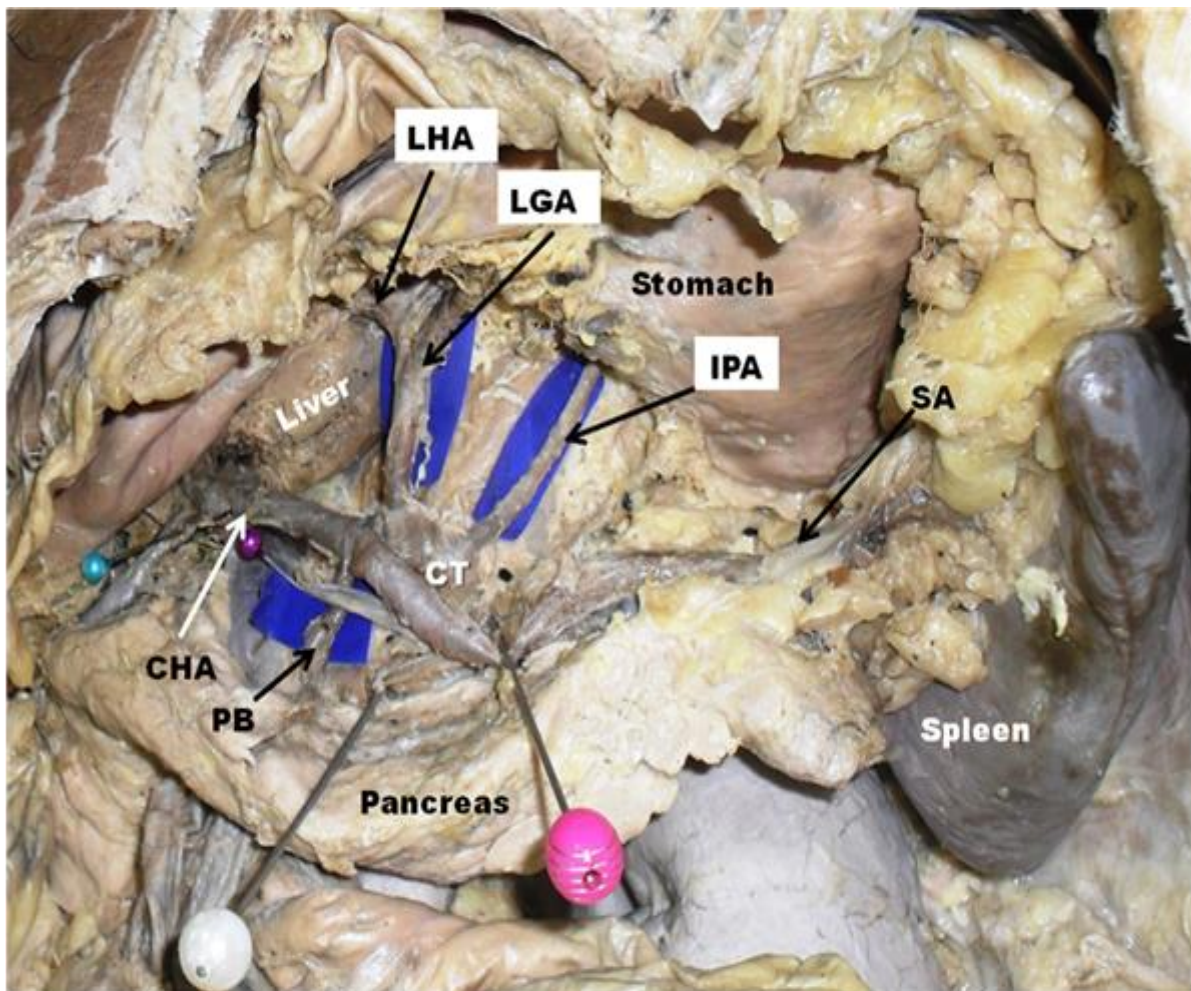


Figure 1: Dissection of abdomen showing the coeliac trunk (CT) with common hepatic artery (CHA), splenic artery (SA) and left gastric artery (LGA). Inferior phrenic artery (IPA) can be seen emerging from the proximal part of the coeliac trunk. PB-Pancreatic branch, LHA-Left hepatic artery.

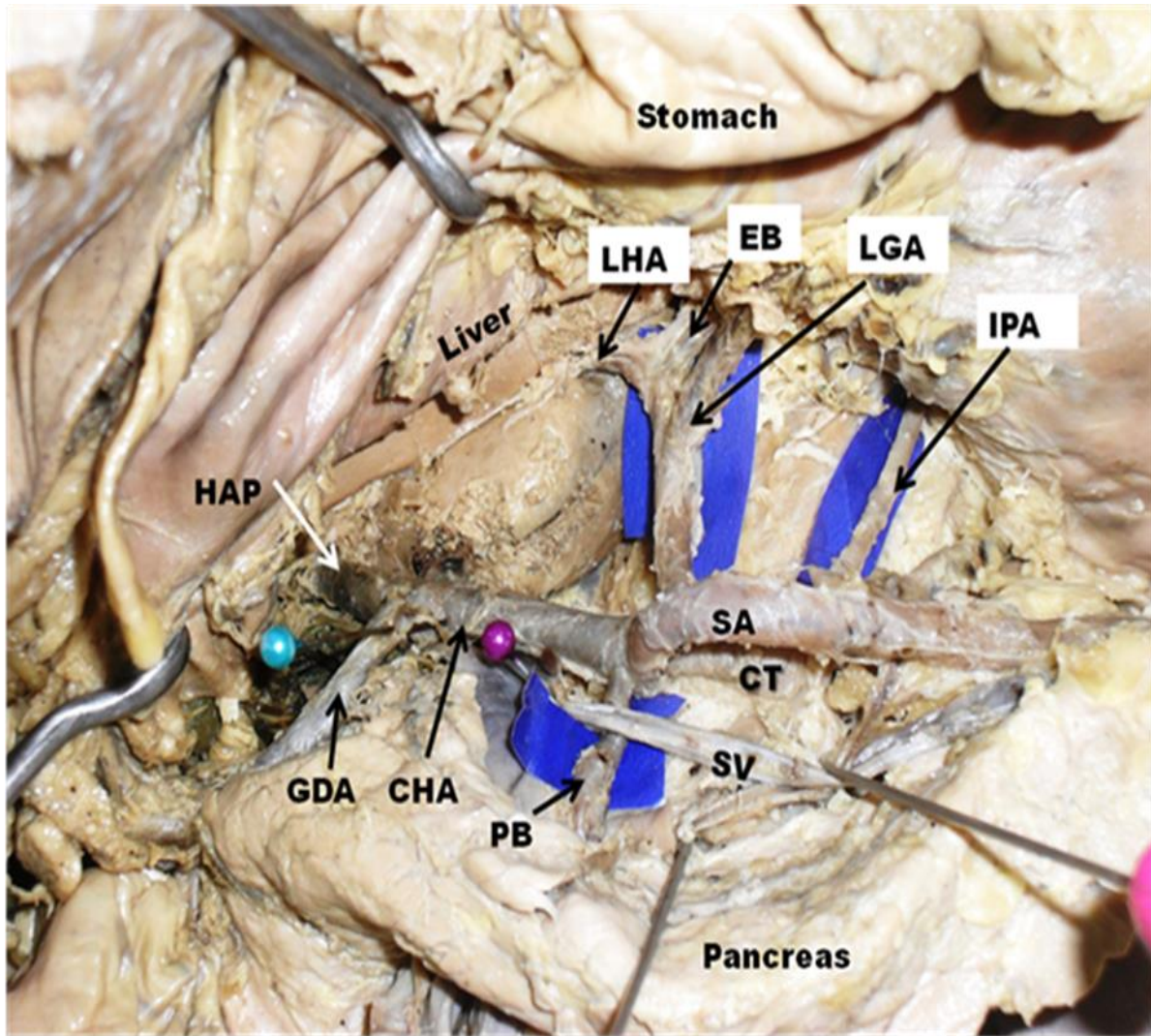


Figure 2: Closer view of anomalous branching pattern of celiac trunk (CT) giving rise to pancreatic branch (PB) passing behind the splenic vein (SV) and supplying the retracted pancreas, Left hepatic artery (LHA) and esophageal branch (EB) arising from left gastric artery (LGA) and undivided hepatic artery proper (HAP) continuing as right hepatic artery. CHA- common hepatic artery, GDA-gastroduodenal artery, IPA-inferior phrenic artery. SA- splenic artery

DISCUSSION

Celiac trunk (CT) is the first major branch of the abdominal aorta, which originates at the level of twelfth thoracic vertebra. It is the artery of foregut, supplying abdominal part of esophagus, stomach, first part of duodenum and proximal half of the second part of the duodenum along with pancreas and spleen through its left gastric, common hepatic and splenic branches (1). Very often, CT is known to show its variant branching pattern hence, it has been reported that the classical trifurcation of CT is seen in 66.6% of cases as evidenced from cadaveric dissection (2) and its prevalence is 89.8% as demonstrated by multi detector – row computed tomography image technique (3).

Celiac trunk variation in its branching pattern may have more than three branches and has been reported several times in earlier case reports and studies (4). The celiac trunk branching patterns may vary from classical trifurcation to aberrant bifurcation, quadrifurcation, pentafurcation and even hexafurcation. Among the additional branches of the celiac trunk, the inferior phrenic artery, gastroduodenal artery, middle colic artery, dorsal pancreatic artery, jejunal or duodenal branches are included (5). According to study done by Mburu, the celiac trunk was trifurcated in 61.7%, bifurcated in 17.9% and gave collaterals in 20.3% of cadavers. Branches from coeliac trunk included dorsal pancreatic artery in 14.8% cases, gastroduodenal in

3.3% cases, inferior phrenic arteries in 4.9% cases respectively (6). While in a study conducted by Ugurel et al., a hepatosplenomesenteric trunk was seen in 1% and a splenomesenteric trunk was present in 1% of patients (7). In another study conducted on 974 cases, a total of 89.8% of cases showed the normal branching pattern of the coeliac trunk, while the variant left and right hepatic arteries were observed in 11.0% and 4.9% of cases, respectively. A variation of both the left and right hepatic arteries was found in 1.5% of cases. Common hepatosplenic trunk and a gastrohepatic trunk were observed in 4.4% and 0.3% of cases, respectively. Common hepatic artery arising from the superior mesenteric artery was present in 3.5% and arising directly from the aorta was present 0.5% cases. A hepatosplenomesenteric trunk and a celiomesenteric trunk were encountered in 0.7% cases (8). A Study by D'Souza et al., on 20 cadavers found two aberrant cases; in first case the coeliac trunk gave an additional branch to the right lobe of the liver and another additional pancreatic branch supplying the body of the pancreas. In second case, an additional hepatic branch from the left gastric artery entered the left lobe of the liver (9).

A case has been reported in which the celiac trunk which bifurcated into splenic and common hepatic arteries, while the left gastric artery arose from the abdominal aorta. In the same case, the right hepatic artery gave origin to gastroduodenal artery (10). In another variation, common hepatic artery (CHA) was formed by the union of a branch arising from hepato-gastric trunk and another branch was arising from hepato-splenic trunk from abdominal aorta (11). Uva et al. reported the origin of common hepatic artery from the left gastric artery (12). Nayak et al in his case report mentioned about aberrant coeliac trunk giving rise to left phrenic artery, left gastric artery, splenic artery, common hepatic artery and gastroduodenal artery (13). Another case mentioned about coeliac trunk giving rise to the left gastric, the common hepatic, the splenic, the left gastro-epiploic, the right and left inferior phrenic arteries (14). Common celiaco-mesenterico-phrenic trunk along with renal vascular variations has been reported before (15). Nayak et al. have reported about the celiac trunk with low origin at the level of L2 vertebra which gave origin to the right and left inferior phrenic arteries and terminated by giving splenic, left gastric and common hepatic arteries (16). The present case is unique as the combination of aberrant branches of coeliac trunk was not mentioned earlier in which the inferior phrenic artery, pancreatic branch and an aberrant left hepatic artery from left gastric artery was present.

The vascular patterns are important for surgeons operating in the upper abdominal area. Knowledge of the variant coeliac trunk and its branching pattern is inevitable during surgical procedures such as liver transplants, vascular ligation and anastomosis. In radiological interventions such as celiacography and the chemoembolization of hepatic tumors, vascular pattern of coeliac trunk should be evaluated in advance (9). Knowledge of the variations of the branches of the coeliac trunk is important during surgery of the stomach, duodenum and pancreas (5). Variations of the coeliac trunk must be studied during surgical anastomosis of the arteries in liver transplant surgeries (5). Arterial steal syndrome was reported during a liver transplant surgery in which aberrant left hepatic artery was discovered (17). In the present case, the left hepatic artery is emerging from the left gastric artery and enters the substance of liver from the left side of the caudate lobe of liver. This unusual wide distance between the right and left hepatic arteries may pose difficulty in case of liver grafting from a donor or in case of liver transplantation to another recipient during arterial grafting procedure. Thus such variations of coeliac trunk should be excluded before liver transplant surgeries to avoid further complications.

CONCLUSION

Though the variations in branching pattern of coeliac trunk is common, its clinical importance in most of the cases cannot be overlooked. Aberrant branches supplying the abdominal structures may pose a difficulty for surgeon operating in the region and may lead to iatrogenic vascular accidents. Knowledge of atypical branching pattern of coeliac trunk is imperative before handling liver transplantation surgery for a proper vascular ligation and anastomosis.

REFERENCES

- [1] Standring S. Gray's anatomy, the anatomical basis of clinical practice. 39th ed. Edinburgh. Elsevier Churchill Livingstone; 2005. Pp1118-1119.
- [2] Nayak SB, Kumar N, Guru A, Shetty SD. Unusual branching pattern of coeliac trunk – a case report. Int J AnatVar 2012; 5: 134-136.

- [3] Okada Y, Nishi N, Matsuo Y, Watadani T, Kimura F. The common hepatic artery arising from the left gastric artery. *SurgRadiol Anat.* 2010; 32: 703–705
- [4] Bergman RA, Thompson SA, Afifi AK, Saadeh FA. *Compendium of Human Anatomic Variations.* Baltimore, Urban & Schwarzenberg. 1988; 65
- [5] Chitra R. Clinically relevant variations of the coeliac trunk. *Singapore Med J.* 2010; 51(3): 216-219.
- [6] Mburu KS, Alexander OJ, Hassan S, Bernard N. Variations in the branching pattern of the celiac trunk in a Kenyan population. *Int J Morphol.* 2010; 28: 199-204.
- [7] Ugurel MS, Battal B, Bozlar U, Nural MS, Tasar M, Ors F, Saglam M, Karademir I. Anatomical variations of hepatic arterial system, coeliac trunk and renal arteries: an analysis with multidetector CT angiography. *Br J Radiol.* 2010; 83: 661-667.
- [8] Chen H, Yano R, Emura S, Shoumura S. Anatomic variation of the celiac trunk with special reference to hepatic artery patterns. *Ann Anat.* 2009; 191: 399-407.
- [9] D'Souza AS, Vijayalakshmi, Hemalatha, Pugazhandhi, Mamatha H. Anatomical Variations in the Branches of the Coeliac Trunk. *Journal of Clinical and Diagnostic Research.* 2012; 6(3): 333-335.
- [10] Badagabettu SN, Sirasanagandla SR, Kumar N, Shetty SD. Hepatosplenic Trunk Associated with Tortuous Course of Right Hepatic Artery Forming Caterpillar Hump. *North Am J Med Sci* 2012; 4: 376-378.
- [11] Hemanth K, Garg S, Yadav TD, Sahni D, Singh R. Hepato-gastro-phrenic trunk and hepato-spleno-mesenteric trunk: a rare anatomic variation. *Trop Gastroenterol.* 2011 ;32(1):56-59.
- [12] Uva P, Arvelakis A, Rodriguez-Laiz G, Lerner S, Emre S, Gondolessi G. Common hepatic artery arising from the left gastric artery: a rare anatomic variation identified on a cadaveric liver donor. *SurgRadiol Anat.* 2007; 29: 93–95.
- [13] Nayak SR, Prabhu LV, Krishnamurthy A, Ganesh Kumar C, Ramanathan LA, Acharya A et al. Additional branches of celiac trunk and its clinical significance. *Rom J MorpholEmbryol.* 2008; 49(2): 247-249.
- [14] Çiçekcibaşı AE, Uysal II, Seker M, Tuncer I, Büyükmumcu M, Salbacak A. A rare variation of the coeliac trunk. *Ann Anat.* 2005; 187(4): 387-391.
- [15] Nayak S. Common celiaco-mesenterico-phrenic trunk and renal vascular variations. *Saudi Med J.* 2006;27(12):1894-1896.
- [16] SB Nayak, J Patil, R Thangarajan, GS Prabhu. Long coeliac trunk and its low origin and unusual branches: a case report. *OA Case Reports* 2013;2(8):77.
- [17] Nishida S, Kadono J, DeFaria W, Levi DM, Moon JI, Tzakis AG, Madariaga JR. Gastroduodenal artery steal syndrome during liver transplantation: intraoperative diagnosis with Doppler ultrasound and management. *Transpl Int.* 2005; 18(3): 350-353.