

Research Journal of Pharmaceutical, Biological and Chemical Sciences

A Case of Asymmetrical Lateral Ventricles with Normal Variant.

Aravindan R*, Noorul Ameen KH, and Manikandan.

Sree Balaji Medical College, Chennai, Tamil Nadu, India.

ABSTRACT

Asymmetrical lateral ventricle is a condition usually presents in all ages. Patients with these condition usually presents with headache, blurring of vision, seizures, vomiting, vertigo, giddiness. Sometimes patients present with no complaints and have abnormal lateral ventricle. CT brain will reveal the abnormalities in lateral ventricle. Asymmetrical lateral ventricle with normal variant is also seen in some condition. In this case a 15 year old male presented with unilateral headache in right sided with blurring of vision. CT brain revealed lateral ventricle asymmetry in right side with mucosal thickening in ethmoidal sinus.

Keywords: Asymmetrical lateral ventricle, mucosal thickening, ethmoidal sinus.

**Corresponding author*

CASE REPORT**History:**

A 15 year old boy presented with unilateral headache for more than six months associated with blurring of vision. Headache was on right sided, pricking type of pain, associated with nausea and vomiting. No history of trauma, LOC, seizures, altered sensorium or bleeding manifestations. No history of seizure disorder, congenital disorders. Headache was present in intermittent nature and no aggravating and relieving factors.

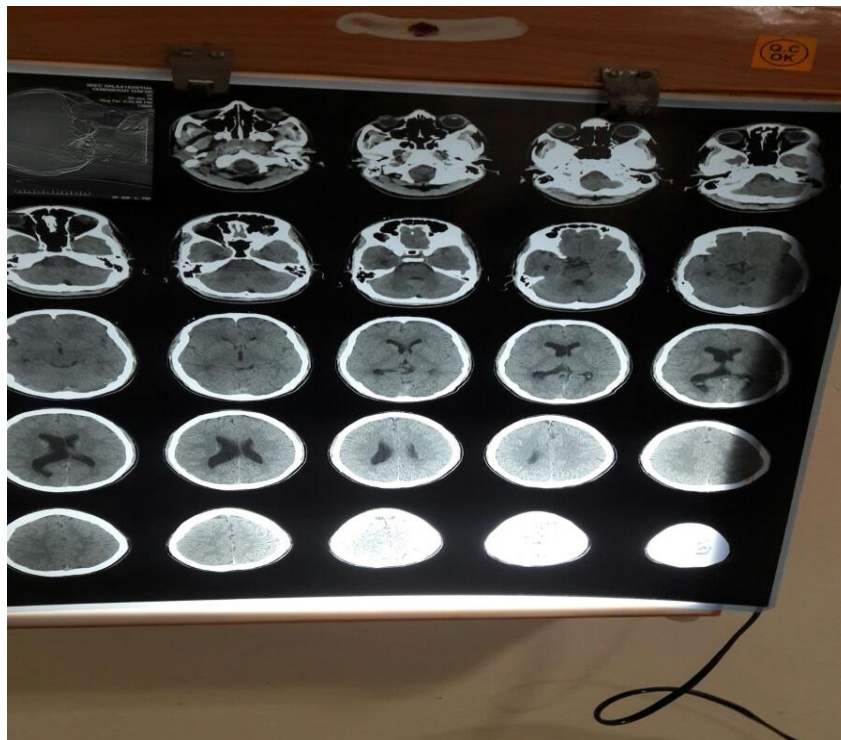
Examination:

He was thin built and well nourished. Vitals were stable. CNS examination was done and found to be normal. Detailed motor and sensory examination done and found to be intact. No cerebellar disorder involved. No signs of meningism.

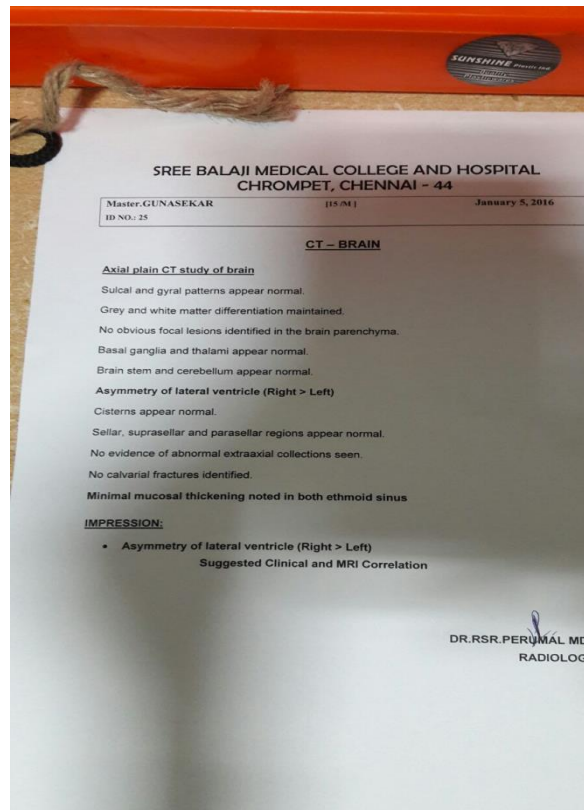
On investigation, haemogram showed normal haemoglobin (12.5 g/dl) with ESR (08mm/hr) and RBC (4.02 million cells/ cu.mm) count and PCV (31.2 %) and urinalysis showed normal. Urea was 15 mg/dl, creatinine was 0.7 mg/dl and blood sugar level was 84 mg%. CSf analysis was normal.

Chest X-Ray PA view was normal.

CT BRAIN done which revealed dilatation of right ventricle with compressed left ventricle. Mucosal thickening of ethmoidal sinus noted. Asymmetrical lateral ventricle was more on right side than left side. (Rt>Lt)



Dilated right ventricles with compressed left ventricle with ethmoidal sinus thickening-Features suggestive of asymmetrical lateral ventricles.



CASE DISCUSSION

15 year old boy presented with headache on right sided associated with blurring of vision and giddiness.[1]Headache was unilateral more on right side compared to left side and was present for chronic time for more than six months. No history of seizures, LOC, bleeding manifestations, vomiting. Systemic examination done and found to be normal. General examination was fair. CNS examination revealed normal. No History of any focal neurological deficit. Detailed examination of sensory and motor examination done. All baseline investigations done and found to be normal. CT brain done and revealed asymmetry of lateral ventricle[2,3] more on right side than left side with no intracerebral hemorrhage. No midline shift. Dilated right ventricle with compressed left ventricle was present[4,5,6].The lateral ventricles are part of the ventricular system of the brain. Both cerebral hemispheres contain a lateral ventricle. The lateral ventricles are the largest of the ventricles.

Each lateral ventricle resembles a C-shaped structure that begins at an inferior horn in the temporal lobe, travels through a body in the parietal lobe and frontal lobe, and ultimately terminates at the interventricular foramina where each lateral ventricle connects to the central third ventricle. Along the path, a posterior horn extends backward into the occipital lobe, and an anterior horn extends farther into the frontal lobe. Asymmetrical lateral ventricle was present with abnormal variant with clinical manifestations.[7]This is a case of Asymmetrical lateral ventricle with normal variant which is a rare one[8,9].All baseline investigations done and follow up was made. Treated in a conservative manner and patient was symptomatically better.

CONCLUSION

Asymmetrical lateral ventricle usually present with abnormalities and clinical manifestations and complications with CT brain findings. This is a rare case of asymmetrical lateral ventricle with normal variant.

REFERENCES

- [1] Habib M, Renicci RL, Vanier M, et al. CT assessment of rightleft asymmetries in the human cerebral cortex. J Comput Assist Tomogr 1984;8:922-927



- [2] Hochberg FH, LeMay M. Arteriographic correlates of handedness. *Neurology* 1975;25:218-222 14. LeMay M, Culebras A. Human brain: morphologic differences in the hemispheres demonstrable by carotid arteriography. *N Engl J Med* 1972;287:168-180
- [3] LeMay M. Morphological cerebral asymmetries of modern man, fossil man and non-human primates. *Ann NY Acad Sci* 1976;280:349-366
- [4] LeMay M. Asymmetries of the skull and handedness; phrenology revisited. *J Neurol Sci* 1977;32:243-253
- [5] LeMay M, Kido DK. Asymmetries of the cerebral hemispheres on computed tomograms. *J Comput Assist Tomogr* 1978;2:471-476
- [6] McRae DL, Branch DL, Milner B. The occipital horns and cerebral dominance. *Neurology* 1968;18:95-98
- [7] Strauss E, Fitz C. Occipital horn asymmetry in children. *Ann Neurol* 1980;8:437-439
- [8] Hadzielimić H, Cus M. The appearance of the internal structures of the brain in relation to the configuration of the human skull. *Acta Anat (Basel)* 1966;63:289-399
- [9] Chang Chui H, Domasio AR. Human cerebral asymmetries evaluated by computed tomography. *J Neurol Neurosurg Psychiatry* 1980;43:873-878
- [10] Weinberger DR, Luchins DJ, Morbisa J, Syatt RJ. Asymmetrical volumes of the right and left frontal and occipital regions of the human brain. *Ann Neurol* 1982;11:97-100