

# Research Journal of Pharmaceutical, Biological and Chemical Sciences

## Amyand`S Hernia: The Clinical and Diagnostic Insight of a Rare Case.

Hayder Assim M Salih<sup>1</sup>, Naghem Farouk Abed<sup>2\*</sup>, Atif AB<sup>2</sup>, Zahri MK<sup>3</sup>, Tarik Ibrahim Ali<sup>4</sup>,  
and Wisam A Yassin<sup>2</sup>.

<sup>1</sup>Al Karama Teaching Hospital, Baghdad - Iraq.

<sup>2</sup>Faculty of Medicine –University Sultan Zainal Abidin, UniSZA, Jalan Sultan Mahmud, 20400, Kuala Terengganu, Terengganu - Malaysia.

<sup>3</sup>Faculty of Health Sciences – University Sultan Zainal Abidin, UniSZA, Kampus Gong Badak, 21300 Kuala Nerus, Terengganu, Malaysia.

<sup>4</sup>Faculty of Medicine & Defence Health - National Defence University Malaysia (UPNM). Kem Sungai Besi, 57000 Kuala Lumpur, Malaysia.

### ABSTRACT

Amyand's hernia is the presence of a normal or an inflamed vermiform appendix within an inguinal hernia. It is a rare incidental finding and constitutes about 1% of an adults` inguinal hernias. This is a report of a rare case an Amyand's hernia in a 20-year-old male patient. Intraoperatively, the appendix was seen accidentally during a standard right inguinal hernia repair. Base first appendectomy was performed because the mesoappendix was adherent to the sac in the distal two-thirds followed by hernia repair using a synthetic mesh with good recovery. This report can be used in future for surgeons in Iraq as one of the baselines complementing the data for Amyand's hernia.

**Keywords:** Amyand's hernia, appendicitis, base first appendectomy, inguinal hernia.

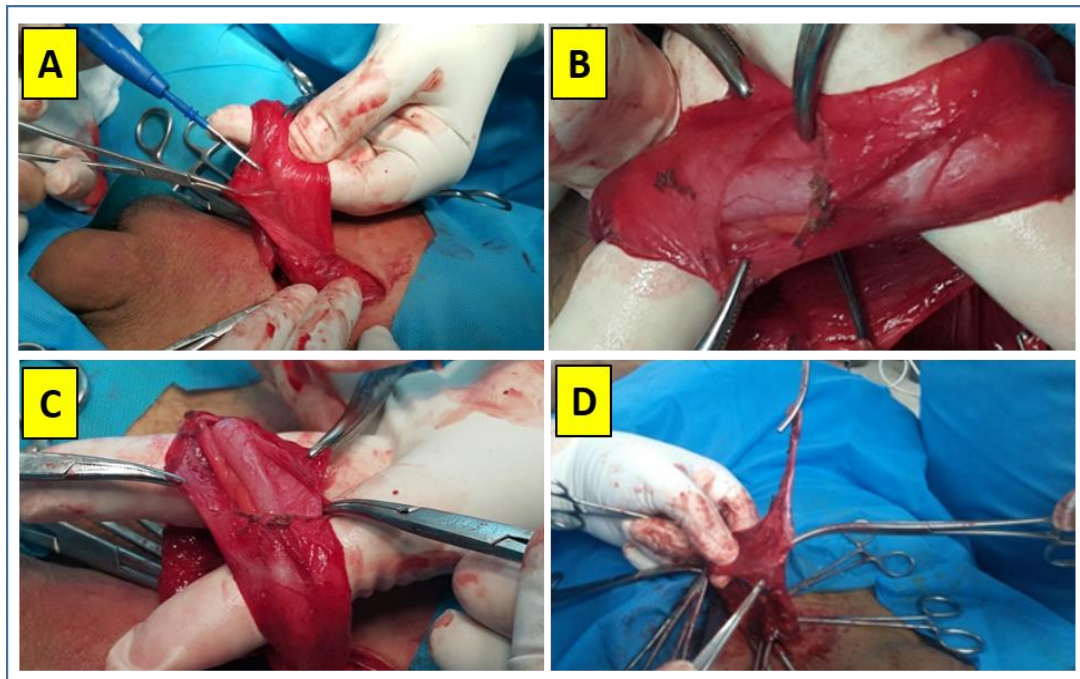
*\*Corresponding author*

## INTRODUCTION

An Inguinal hernia is an implication which is considered as a common surgical problem. Amyand's hernia reported firstly by, Claudius Amyand; 1735 [2] is an inguinal hernia characterized by the positioning of appendix within the hernia sac. [1] In general, inguinal hernia has no specification of occurrence as per sex or age group. Amyand's hernia was reported in a wide range of age; from the neonatal period to 92 years old. [1] Its incidence fluctuates between 0.19 and 1.7%. [1] Regardless of the stage of presentation, 0.07 – 0.13% of these cases have coexisted with appendicitis. [1,3] The aim of this case report is to present our experience of facing a rare case of Amyand's hernia.

## CASE REPORT

A 20-year-old male, was admitted to one of the major teaching hospital in Baghdad, Iraq in May 2016, for elective right indirect inguinal hernia repair. On physical examination, his abdomen was found soft without tenderness or distention. On inguinal examination, an irreducible mass was found in the right-side with mild upper scrotal involvement. Routine investigations were done and found normal (data not shown). An operative consent was obtained from the patient. Under general anaesthesia, the patient was positioned supine and draped with an aseptic technique. The right inguinal canal was explored through a right-sided oblique incision of five cm length parallel to the inguinal ligament. Layer by layer incision was performed, the cord was delivered, hernial sac was dissected, and a tubular structure was found within the sac (Figure 1-A). It raised the suspicion of the presence of an appendix inside the hernial sac. Later, the sac was opened at its distal end, the appendix was seen clearly in the sac (Figure 1-B), with its mesoappendix adherent to the posteromedial part of the sac (Figure 1-C). Its base was free, therefore base first appendectomy was done (Figure 1-D), leaving the distal part of the appendix and its mesoappendix attached to the distal part of the sac and all together have been removed. The proximal part of the sac was managed in the usual manner and completing the repair using a prosthetic mesh.



- A. A tubular structure is seen inside the hernial sac.
- B. Distal part of the hernial sac is opened and the appendix is seen.
- C. The appendix is adherent to the sac.
- D. Base first appendectomy.

Postoperative period passed uneventfully and the patient was discharged well on the same day. Four weeks later, He returned to the clinic without any complaints.

Classification	Description	Management
<b>Type 1</b>	Normal appendix in an inguinal hernia.	Hernia reduction, mesh placement, with or without appendectomy and according to the age, especially in young patients.
<b>Type 2</b>	Acute appendicitis in an inguinal hernia with no abdominal sepsis.	Appendectomy and primary non-prosthetics hernia repair
<b>Type 3</b>	Acute appendicitis in an inguinal hernia with abdominal and abdominal wall sepsis.	Laparotomy, appendectomy, and primary non-prosthetic hernia repair.
<b>Type 4</b>	Acute appendicitis in an inguinal hernia with an abdominal concomitant pathology.	Same as type 3 plus management of a concomitant disease.

Losanoff and Basson classification of Amyand`s Hernia. [7]

### DISCUSSION

Amyand`s hernia has been mostly reported in male and vast majority founded on the right side except in cases of situs inversus or malrotation of the gut.<sup>[1,4]</sup> Besides, in 2009, an interesting case report published an extremely rare left-sided Amyand`s hernia in a 70-year-old man without gut malpositioning and was explained previously to be due to an excessive mobile cecum.<sup>[4]</sup>

As per definition, hernia is a protrusion of a viscus or its part through the walls of its containing cavity. The contents of the Inguinal hernia sac can be sometimes surprising to the surgeon, e.g. urinary bladder (sliding hernia), part of the small bowel (Richter`s hernia), Meckel`s diverticulum (Littre`s hernia), ovary, Fallopian tubes, and the appendix in Amyand`s hernia.<sup>[5]</sup> In the literature, the development of the Amyand`s hernia has been often questionable. One of the possible explanations is that, when the appendix herniates, it becomes vulnerable to micro-traumatization, leading to fibrosis and the appendix gets adherent to the sac. This may proceed uneventfully and without appendicular inflammation. Occasionally, impairment of the appendicular blood supply may develop as a result of recurrent abdominal muscle contractions, which press on the appendix leading to ischemia and subsequent bacterial infection. This can mimic strangulated or incarcerated hernia and this is hardly possible to be diagnosed pre-operatively.<sup>[1,6]</sup> Although CT scan can be helpful in the diagnosis of such condition, it is rarely used in case of an irreducible hernia.<sup>[4]</sup> In 2007, Losanoff and Basson have classified Amyand`s hernia into four types and they recommended accordingly different management <sup>[7]</sup> which can guide the surgeon (Table 1).

### CONCLUSION

Amyand`s hernia is a rare type of inguinal hernia and its successful management depends on the combination of surgeon's experience, clinical scenario, and the knowledge of Losanoff and Basson classification for safest results. The combination may give the safest results. Fortunately, in this case, the appendix was not inflamed, hence, an appendectomy followed by an instant insertion of a prosthetic mesh was performed without complications as it was considered as type 1 according to Losanoff and Basson classification. We have concluded that, firstly, the initial approach should consider imaging studies; like ultrasound or CT scan examination in cases of incarcerated or strangulated inguinal hernia, nevertheless this is yet not routinely done and needed to be more considered. Secondly, the surgeon needs to be aware of all clinical settings and be prepared well and apply the appropriate management if encounter unexpected intraoperative findings such as Amyand`s hernia. Last but not least, the outcomes of the Amyand`s hernia management, according to Losanoff and Basson classification need to be more evaluated. Amyand`s hernia is rarely addressed by surgeons in Iraq and this report will complement as a baseline data for them to encounter Amyand`s hernia in future.

### ACKNOWLEDGEMENT

Authors are much grateful to Dr. Mahmood Jumaa Al Kubaisee, a general surgeon at Al Karama Teaching Hospital, Baghdad – Iraq for his assistance during the surgical operation.



REFERENCES

- [1] Galyna Ivanschuk, Alper Cesmebasi, Edward P. Sorenson, Christa Blaak, Marios Loukas, Shane R. Tubbs. Amyand's hernia: A review. *Med Sci Monit* 2014; 20:140–6.
- [2] Amyand C. (1736) Of an inguinal rupture, with a pin in the appendix caeci incrusted with stone, and some observations on wound in the guts. *Phil Trans R Soc Lond* 39:329–342. Cited in ; Vipul D. Yagnik. Amyand's hernia. *J Indian Assoc Pediatr Surg* 2012;17(2): 88.
- [3] Michalinos A, Moris D, Vernadakis S. Amyand's hernia: a review. *Am J Surg* 2014; 207:989–95.
- [4] Hamed Ghodduji Johari, Shahram Paydar, Sam Zeraatian Nejad Davani, Shima Eskandari, Masumeh Ghodduji Johari. Left-sided Amyand hernia. *Ann Saudi Med* 2009; 29:321–2.
- [5] Osorio JK, Guzmán-Valdivia G. Ipsilateral Amyand's and Richter's hernia, complicated by necrotizing fasciitis. *Hernia* 2006; 10:443-6.
- [6] Tsang WK, Lee KL, Tam KF, Lee SF. Acute appendicitis complicating Amyand's hernia: imaging features and literature review. *Hong Kong Med J* 2014; 20:255-7.
- [7] Losanoff JE, Basson MD. Amyand hernia: a classification to improve management. *Hernia* 2008; 12(3):325-6.