

Research Journal of Pharmaceutical, Biological and Chemical Sciences

Efficacy of Bee Venom or Proplis Treatment on Molecular and Immunological Aspects of Schist Soma Mansoni Infected Mice Liver.

Asmaa E Bayomi^{1*}, Azza H Mohamed¹, Sobhy E Hassab El-Nabi¹, and Mona Goudia².

¹Department of Zoology, Faculty of Science, Menufia University, Shebin El-Kom, Egypt.

²Head of flow cytometry fellow of Bio medical analysis Genetics units, Faculty of Medicine, children hospital, Mansoura University.

ABSTRACT

This study was conducted to assess the effect of bee venom (BV) *Apis mellifera* L delivered either by sting (single sting/week for two weeks) or by subcutaneous injection (one dose "0.1 mg/kg body weight" for two weeks) or proplis (200 mg/kg orally for three consecutive days) on some molecular and immunological marker in *Schist soma mansoni* infected mice. CD34 as marker for angiogenesis illustrated moderate expression in sinusoids of infected treated liver mouse. Flow cytometry analysis of CD4 recorded a significant decrease in mean number of CD4 was recorded in infected mice treated with bee venom or proplis with values 22.48 ± 0.24 , 31.3 ± 0.35 and 34.79 ± 0.26 , respectively when compared to infected group (38.28 ± 0.4). At the level of molecular studies using flow cytometry analysis, *S. mansoni* infected mice treated with bee venom injection or proplis showed significant decrease in mean percentage of apoptosis of liver tissue with values 44.26 ± 0.43 and 40.6 ± 0.4 ; respectively as compared with infected group (61.25 ± 0.63). Electrophoresis pattern of DNA liver tissue indicated significant decrease in maximal optical density of intact DNA of infected mice treated with bee venom as compared with infected group. Infected group treated with proplis illustrated an increase in intact DNA as compared with infected control. In conclusion proplis and bee venom injection can decrease DNA damage caused by infection than bee venom sting.

Keywords: *Schist soma mansoni*, bee venom, proplis, DNA.

**Corresponding author*

INTRODUCTION

Schistosomiasis is endemic in 78 countries and at least 261 million people are estimated to be infected worldwide [1]. Schistosomiasis is the third most devastating tropical disease in the world after malaria and intestinal helminthiasis, being a major source of morbidity and mortality for developing countries in Africa, South America, the Caribbean, the Middle East, and Asia [2]. The formation of granulomatous lesions is a complex dynamic process that leads to the inflammatory destruction or confinement of the inciting agent. This process involves recruitment of blood monocytes among lymphocytes, monocytes and macrophages, epithelioid cells, eosinophils, neutrophils and fibroblasts [3]. Moreover, Mathew and Boros [4] and Anyan [5] illustrated that T helper cells (CD4+ T cells) are instrumental for the formation of granulomas around *S. mansoni* eggs and CD8+ T cells appear to be important for down regulation of granuloma size in chronic infections [6,7]. In the same time, Lundy et al. [8] indicated that schistosomiasis may use host cell apoptosis as survival strategy to establish infection in their host and can influence the development or maintenance of different clinical manifestations.

The mainstay for control of schistosomiasis is chemo-therapy with praziquantel (PZQ) used as the drug of choice [9]. Drug resistance is an imminent threat, particularly in light of large-scale administration of PZQ [10].

Apitherapy, or bee therapy, is the use of products of the common honeybee for therapeutic purposes. Honeybee venom, bee pollen, raw honey, royal jelly and propolis are the products generally considered to have medicinal effects [11]. Bee venom therapy has been used since ancient times and is one of the most frequently used traditional complementary and alternative therapeutic methods. It has long been believed to be effective in the treatment of many diseases, including rheumatic arthritis, rheumatism, bursitis, tendinitis, shingles (herpes zoster), multiple sclerosis, wounds, gout, burns, and infections [12]. Huh et al. [13] indicated the functional specificity of BV as an angiogenesis inhibitor using *IN VITRO* models and *IN VIVO* mouse angiogenesis and lung metastasis models.

Propolis which is a constituent of natural honey displays strong antibacterial, antifungal and antiviral activities and has been used as a chemotherapeutic agent since ancient times. It has also a lot of chemical constituents of pharmacological actions. The prospective use of propolis has a great attention in many studies due to its activity. Several experimental studies have shown that it has an immunostimulant activity by stimulation of non-specific immunity. The activity of propolis was associated with the activation of macrophages, which leads to an increase in their phagocytic activity and an increase in T lymphocytes [14]. Santana et al. [15] reported that Brazilian brown propolis elicits antileishmanial effect against promastigote and amastigote forms of *leishmania amazonensis*.

Apoptosis is organized DNA damage manifested by condensation of nuclear chromatin and fragmentation of the nucleus [16]. DNA fragmentation is a key feature of programmed cell death and also occurs in certain stages of necrosis. Apoptosis is characterized by activation of endogenous endonucleases with subsequent cleavage of chromatin DNA into internucleosomal fragments of 180-200bp and multiples. DNA cleavage during apoptosis occurred at sites between nucleosomes, protein containing structures that occurred in chromatin at 200bp intervals [17, 18].

The aim of this study is to evaluate the curative effect of bee venom (sting or injection) of honeybee workers (*Apis mellifera* L.) or propolis (bee-glue) on *Schistosoma mansoni* infected mice by measuring some molecular and immunological parameters.

MATERIALS AND METHODS

Bee venom sting

Craniolian honeybee workers (*Apis mellifera* L.) were obtained from the Apiary of the Faculty of Agriculture, Menoufia University, Egypt. Mice were sting with live bees by stimulating them to sting in the abdomen over the location of the liver with single sting/week for two weeks.

Bee venom injection

Bee venom powder obtained from Faculty of Agriculture, Menoufia University. Bee venom dissolved in distilled water (0.1 mg/kg body weight) and injection was subcutaneously [13] one dose weekly for two weeks.

Propolis

Propolis sample was supplied from Beekeepers Society, Gharbia Governorate, Egypt in powder form. Propolis administrated to mice as aqueous suspension in 3 doses each of which 200 mg/kg orally for three consecutive days [19].

Experimental animals

Through this study fifty six male Swiss albino mice (CD-1 strain) were obtained from Schist some Biological Supply Program (SBSP) unit at Theodor Bilharz Research Institute (TBRI) Giza, Egypt. Mice were transported to Zoology Department, Faculty of Science, Menufia University and caged separately in groups in an environmentally controlled animal facility operating on a 12h dark/light cycle at 24-26°C and were given access to water and standard rodent food pellets ad libitum. All experiments were done in compliance with the guide lines for the care and use of laboratory animals of Menufiya University guide lines. Mice classified into 8 groups (seven mice in each group) as the following: control (untreated) group; normal mice treated with BV sting (single bee sting weekly for two weeks); normal treated with BV injection (0.1 mg/kg body weight, were dissolved in distilled water) and injection subcutaneous one dose weekly for two weeks; normal mice treated with propolis (200 mg/kg orally for three consecutive days); *S. mansoni* infected group (subcutaneously with 65 ± 5 *S. mansoni* cercariae each mouse) (9 weeks post infection (pi)); infected group (7weeks pi) treated with BV sting (single bee sting weekly for two weeks) ; infected group (7weeks pi) treated with BV injection (0.1 mg/kg body weight, were dissolved in distilled water) and injection subcutaneous one dose weekly for two weeks and infected group (7weeks pi) treated with propolis (200 mg/kg orally for three consecutive days). All mice were sacrificed after two weeks of treatments.

Immuno his to chemical expression of CD34

Specimens of liver were fixed in 10% neutral buffered formalin for 24 hours. Tissues were dehydrated using graded ethyl alcohol and impeded in paraffin wax. Blocks were cut by ordinary microtome to histological paraffin section 5 micron in thickness. Liver sections were deparaffinized and endogenous peroxidase activity was blocked with PBS, 0.3% H₂O₂, and 10% methanol for 10-15 min. The sections were incubated for 5 min in PBS containing Ultra V block (block solution). The sections were then incubated overnight at 4°C with mouse monoclonal CD34 primary antibody (lot: 10322070, Cell Marque, Emerge Europe, and USA). The sections were incubated for 10 min. with biotinylated goat anti-polyvalent IgG secondary antibody (Vector Laboratories). Sections were then incubated with avidin-biotin conjugated peroxidase for 45 min washed and stained with 3, 3-diaminobenzidine tetra hydrochloride (DAB) (Sigma) containing 0.01% H₂O₂ in 0.05M Tris-buffered saline (pH 7.6) for 3-5 min. After the enzyme reaction, the sections were washed in tap water, counterstained with hematoxylin then dehydrated in alcohol, cleared in xylene, and mounted in DPX (Merck, Darmstadt, Germany) [20]. Area of CD34 positive staining was assessed and photographed using microscope (Olympus BX41, model BX 41TF, Japan) provided with digital camera (Olympus Imaging Crop, Model No. E420 DC 7.4 V).

Flow cytometry analysis of CD4 and CD8:

Liver tissue specimens from different groups were prepared according to Tribukait et al. [21]. Briefly, liver specimens were homogenated and suspended in Phosphate Buffer Saline (PBS) then, the cell suspension was centrifuged at 2000 rpm for 10 mins, where upon the supernatant was aspirated. Flow-cytometry analysis was performed on single cell suspensions washed three times with PBS (pH 7.2). After washing with PBS, the cell viability was determined by flow cytometry. The flow cytometer used is FACS calibur flow cytometer (Becton Dickinson, Sunnyvale, CA, USA) equipped with a compact air cooked low power 15 mwatt argon ion laser beam (488 nm). This technique is applicable where the fluorochrome is directly linked to the primary antibody for CD4 clone GK 1.5 is type IgG2 b1k anti mouse (FITC cat. no. 11-0041-81) e-Bioscience and for CD8 clone 53-6.7 IGg2 a1k anti mouse (FITC cat. no. 11-0081-81) e-Bioscience. Cells were prepared as mentioned above. The cell suspension adjusted to a concentration of 1X 10⁶cell/ml with PBS/BSA (Bovine serum albumin) buffer (phosphate

buffered saline and 1% BSA). Hundred μ l of cell suspension was aliquot into as many test tubes as required. Antibody added at the recommended dilution (10 μ l for each sample) mix well and incubated at room temperature for 30 minutes. Cells washed with 2ml of PBS/BSA centrifuge at 1800 rpm for 5 minutes and discard the resulting supernatant. Cells re suspend in 0.2ml of PBS/BSA or with 0.2ml of 0.5% Para formaldehyde in PBS/BSA if required. Data acquired by flow cytometry.

Molecular parameters

Flow cytometry analysis of Apoptosis and cell cycle:

Fresh liver tissues from different groups were prepared according to Tribukait et al. [21]. Briefly, liver specimens were homogenated and suspended in Phosphate Buffer Saline (PBS) then, the cell suspension was centrifuged at 2000 rpm for 10 mins, where upon the supernatant was aspirated. Flow-cytometry analysis was performed on single cell suspensions washed three times with PBS (pH 7.2). After washing with PBS, the cell viability was determined by flow cytometry. The cell viability was determined by flow cytometry and apoptosis was measured by using the sub G1 peak staining with propidium Iodide [22]. The average number of evaluated nuclei per specimen 20,000 and the number of nuclei scanned was 120 per second. DNA histogram derived from flow cytometry was obtained with a computer program according to Dean and Jett mathematical analysis [23]. Data analysis was conducted using DNA analysis program MODFIT (verity software house, Inc. Po Box 247, Topsham, ME 04086 USA, version: 2.0, power Mac with 131072 KB Registration No.: 42000960827-16193213).

DNA fragmentation assay

Detection of apoptosis by DNA fragmentation assay was conducted. DNA extraction and apoptosis detection in tissue (liver) was done according to "salting out extraction method" of Aljanabi and Martinez [24] and modification introduced by Hassab El-Nabi [18], protein was precipitated by saturated solution of NaCl (5M). Ten mg of tissues (0.01 gm) were lysed with 600 microlitre of lysing buffer (50 mM NaCl, 1mM Na₂EDTA, 0.5% SDS, PH 8.3) and gently shaken. The mixture was incubated overnight at 37°C then, 200 microlitre of saturated NaCl was added to the samples, shaken and centrifuged at 12,000 rpm for 10 min. the supernatant was transferred to new eppendorf tubes and then DNA precipitated by 600 microlitre cold Isopropanol. The mix was inverted several times till fine fibers appear, and then centrifuged for 5 min at 12,000 r.p.m. The supernatant is removed and the pellets were washed with 500 microlitre 70% ethyl alcohol centrifuged at 12,000 r.p.m for 5 min. After centrifugation the alcohol was decanted or tipped out and the tubes blotted on Whitman paper to be dry. The pellets were resuspended in 50 microlitres or appropriate volume of TE buffer (10 mM Tris, 1 mM EDTA, pH8) supplemented with 5% glycerol. The re suspended DNA was incubated for 30-60 min with loading mix (RNase + loading buffer) and then loaded into the gel wells for detection of apoptosis. Gel was prepared using 1.8% electrophoretic grade agarose. The agarose was boiled with tris borate EDTA buffer (1 x TBE buffer ; 89 mM tris, 89 mM boric acid, 2 mM EDTA, PH8.3), and then 0.5 microgram/ml ethidium bromide was added to agarose mixture at 40 °C. Gel was poured and allowed to solidify at room temperature for 1 hour before sample were loaded.

Apoptotic bands appeared and located at 200 and its multiplies like 400bp and 600bp ect. The intensity of apoptotic bands were measured by software gel pro program as maximum optical density values comparing by 100bp ladder.

Gel were photographed using digital camera while the DNA was visualized using a 312 nm UV light under a transilluminator.

Statistical analysis:

Data are presented as Mean \pm Standard error (M \pm SER). Comparisons were made between the treated and untreated groups. Data were analyzed using Student's t-test, for normally-distributed data [25]. The significance of differences was calculated between mean values of experimental and control groups in each experiment at a level of significance of P \leq 0.05.

RESULTS

Immuno his to chemical observation:

Angiogenesis in hepatic cellular schistosomiasis evaluated by CD34 immune his to chemistry. Normal control liver tissue showing slight expression of CD34 in sinusoidal spaces. *S. mansoni* infected liver showed high expression of CD34 in sinusoids and around granuloma. Similarly, results illustrated moderate expression of CD34 in sinusoids of *Schist soma mansoni* infected liver mouse treated with bee venom sting or injection. On the other hand, Immuno his to chemical staining of CD34 of *S. mansoni* infected liver mouse treated with proplis showing high expression of CD34 in sinusoid and around granuloma with marked intensity, as showing in plate (1).

CD4 and CD8 T-cell

Flow cytometry analysis of CD4 and CD8 was shown in table (1) and figures (1& 2). Result illustrated a significant decrease ($P \leq 0.05$) in mean percentage of CD4 and CD8 in normal mice treated with bee venom (sting or injection) as compared with normal mice (21.34 ± 0.47 and 19.2 ± 0.29 ; respectively). While, normal mice treated with proplis showed significant increase in mean percentage of CD4 and CD8 with values 29.2 ± 0.43 and 22.34 ± 0.31 , respectively as compared with normal mice.

In the same time, *S. mansoni* infected mice (9 weeks post infection) indicated significantly increase in mean percentage values of CD4 and CD8 (38.28 ± 0.4 and 22.57 ± 0.29 , respectively) comparing with normal control. *S. mansoni* infected mice and treated with bee venom (sting or injection) or proplis illustrated a significant decrease in mean number of CD4 with values 22.48 ± 0.24 , 31.3 ± 0.35 and 34.79 ± 0.26 , respectively when compared to infected group. On contrast, mean percentage of CD8 showed a significant increase in *S. mansoni* infected mice treated with bee venom injection or proplis (34.44 ± 0.3 and 42.6 ± 0.33 , respectively) compared with infected mice.

Molecular parameter

Apoptosis and cell cycle

By using flow cytometer analysis, result indicated a significant increase ($P \leq 0.05$) in mean percentage of apoptosis in normal mice treated with bee venom sting and *S. mansoni* infected mice (9 weeks post infection) (53.39 ± 0.47 and 49.44 ± 0.44 , respectively) compared with normal control (29.23 ± 0.68). On contrast, normal mice treated with bee venom injection or proplis showed significantly decrease in mean percentage with values 26.6 ± 0.37 and 25.12 ± 0.4 , respectively when compared to normal group. *S. mansoni* infected mice treated with bee venom sting illustrated significant increase in mean percentage of apoptosis (61.25 ± 0.63) compared with infected group. But significantly a decrease in mean percentage of infected mice treated with bee venom injection or proplis with values 44.26 ± 0.43 and 40.6 ± 0.4 ; respectively was observed when compared with infected group.

Normal mice treated with bee venom sting showed a significant decrease in mean percentage of G0/1, S and G2/M with values 28.6 ± 0.63 , 9.29 ± 0.5 and 4.35 ± 0.2 ; respectively as compared with normal group (38.59 ± 0.46 , 24.3 ± 0.51 and 4.9 ± 0.45 ; respectively). While, normal mice treated with bee venom injection or proplis indicated significant increase in mean percentage Of G0/1 and G2/M as compared with normal group. *S. mansoni* infected group showed significant decrease in mean percentage of G0/1 (35.5 ± 0.46) and increase in mean percentage of G2/M (5.18 ± 0.36) when compared to normal group. In the same time, mean percentage of G0/1 and G2/M of *S. mansoni* infected mice treated with bee venom sting illustrated significant decrease (12.52 ± 0.37 and 3.27 ± 0.31 , respectively) compared to infected group. But, *S. mansoni* infected mice treated with bee venom injection or proplis indicate significantly increase in mean percentage of S and G2/M as compared with *S. mansoni* infected group, As shown in figure (3).

Detection of apoptosis by gel electrophoresis

As shown in figures (4&5), result recorded a decrease in mean of maximal optical density of intact DNA in normal mice liver treated with bee venom (sting or injection) or proplis as compared with normal mice (165 ± 0.9). While, mean value of intact DNA in hepatic tissue of *S. mansoni* infected mice illustrated a significant decrease with value 151 ± 1 as compared with normal control. On the other hand, mean of maximal

optical density of liver apoptotic bands at 200bp, 400bp and 600bp illustrated a significant increase in bee venom sting treated mice (*S. mansoni* infected and non infected mice) compared to normal and infected control groups. While, *S. mansoni* infected mice treated with propolis showed a significant decrease in mean number of maximal optical density in DNA fragmented at 200bp, 400bp and 600bp in hepatic tissue compared with infected group.

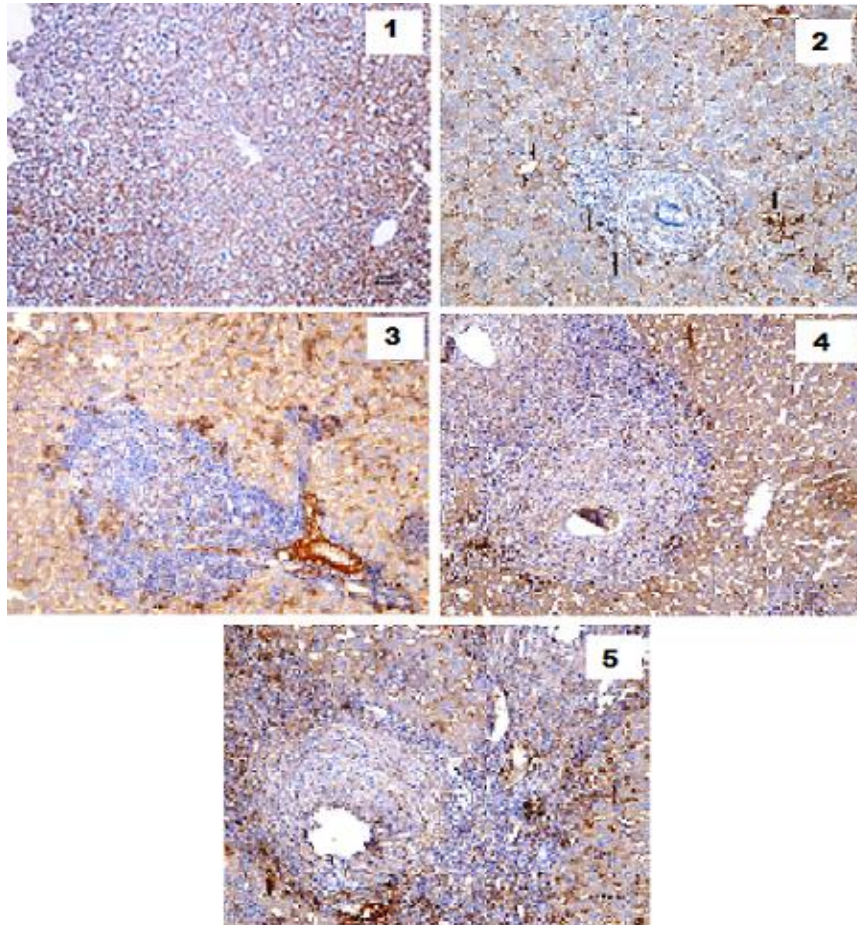


plate (1): Photomicrograph of CD34 Immuno his to chemical expression for assessment of angiogenesis in mouse liver 1) normal liver mouse showed negative expression of CD34, 2) *S. mansoni* infected liver mouse showed brown staining of CD34 in sinusoid and around granuloma, 3) *S. mansoni* infected liver mouse treated with bee venom sting showed moderate expression of CD34 in sinusoid. The portal tract showing marked expression of CD34 in portal vein, 4) *S. mansoni* infected liver mouse treated with bee venom injection showed moderate expression of CD34 in sinusoid 5) *S. mansoni* infected liver mouse treated with propolis showed high expression of CD34 in sinusoids and around granuloma (x 200).

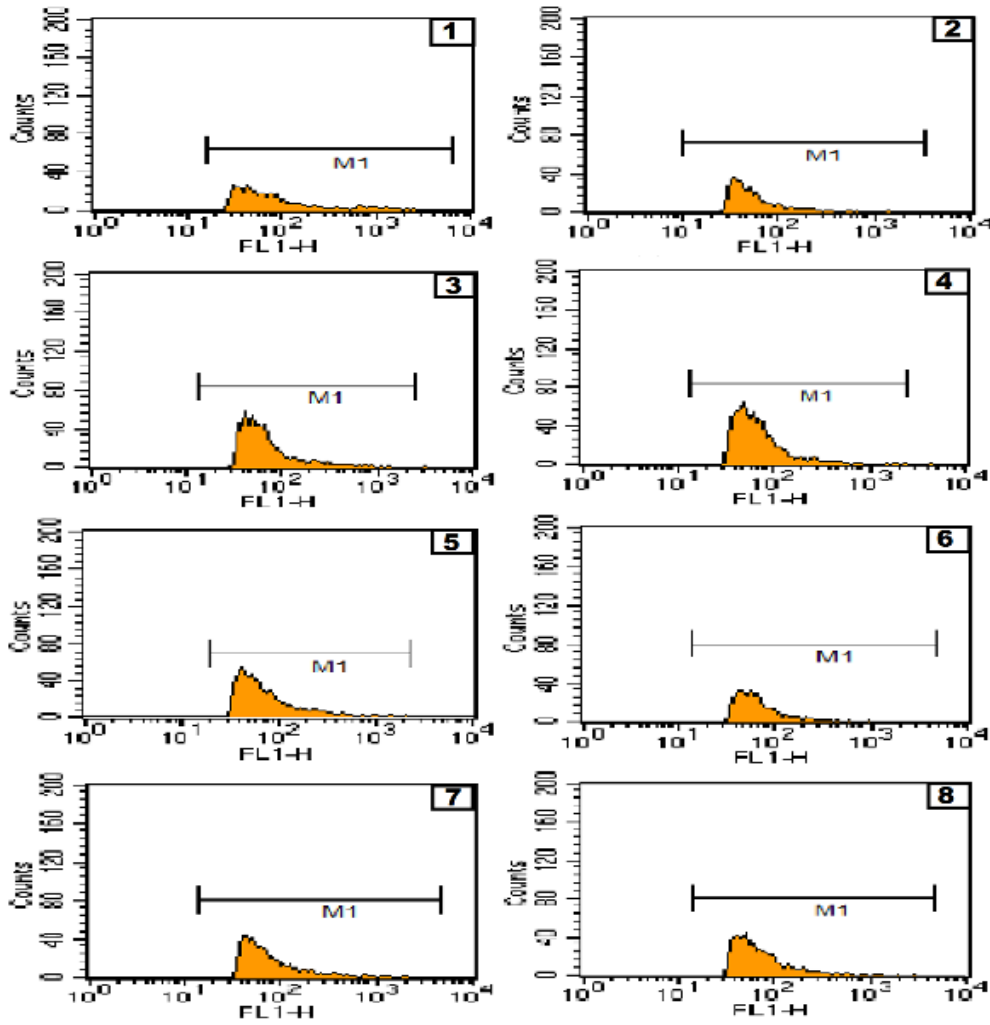


Figure (1): Flow cytometry analysis of CD4 T-cell of *S. mansoni* infected liver mice and treated with bee venom (sting or injection) or proplis. 1) normal control; 2) normal treated with bee venom sting; 3) normal treated with bee venom injection; 4) normal treated with proplis; 5) Infected control; 6) infected and treated with bee venom sting; 7) Infected and treated with bee venom injection; 8) Infected and treated with proplis.

M1= percentage of CD4

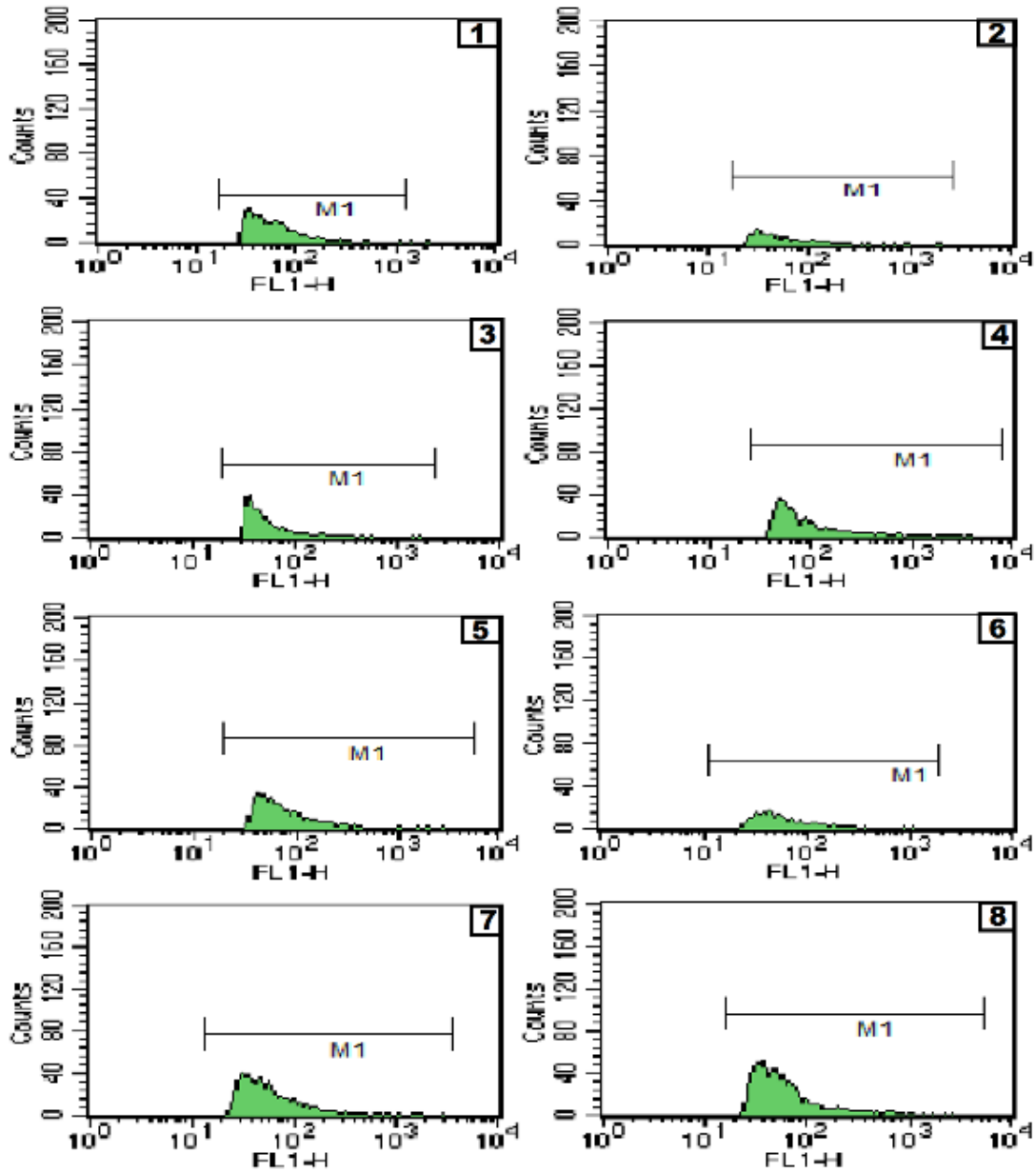


Figure (2): Flow cytometry analysis of CD8 T-cell of *S. mansoni* infected liver mice and treated with bee venom (sting or injection) or proplis. 1) normal control; 2) normal treated with bee venom sting; 3) normal treated with bee venom injection; 4) normal treated with proplis; 5) Infected control; 6) infected and treated with bee venom sting; 7) Infected and treated with bee venom injection; 8) Infected and treated with proplis.

M1= percentage of CD8

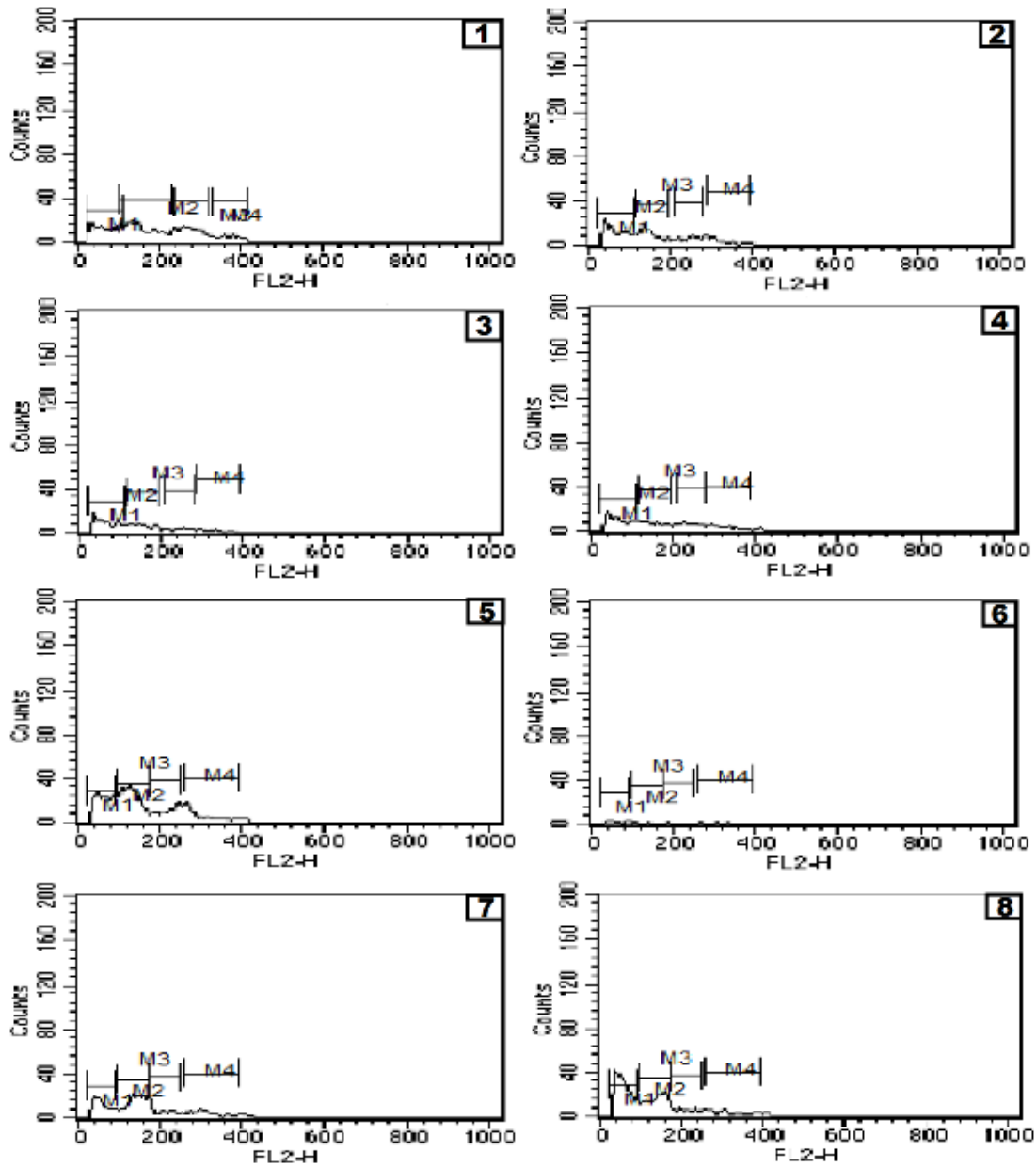


Figure (3): Flow cytometry analysis of apoptosis and cell cycle of liver tissue of *S. mansoni* infected liver mice and treated with bee venom (sting or injection) or propolis. 1) normal control; 2) normal treated with bee venom sting; 3) normal treated with bee venom injection; 4) normal treated with propolis; 5) Infected control; 6) infected and treated with bee venom sting; 7) Infected and treated with bee venom injection; 8) Infected and treated with propolis.

M1= apoptosis, M2= G0/1 phase, M3= S phase, M4= G2/M phase.

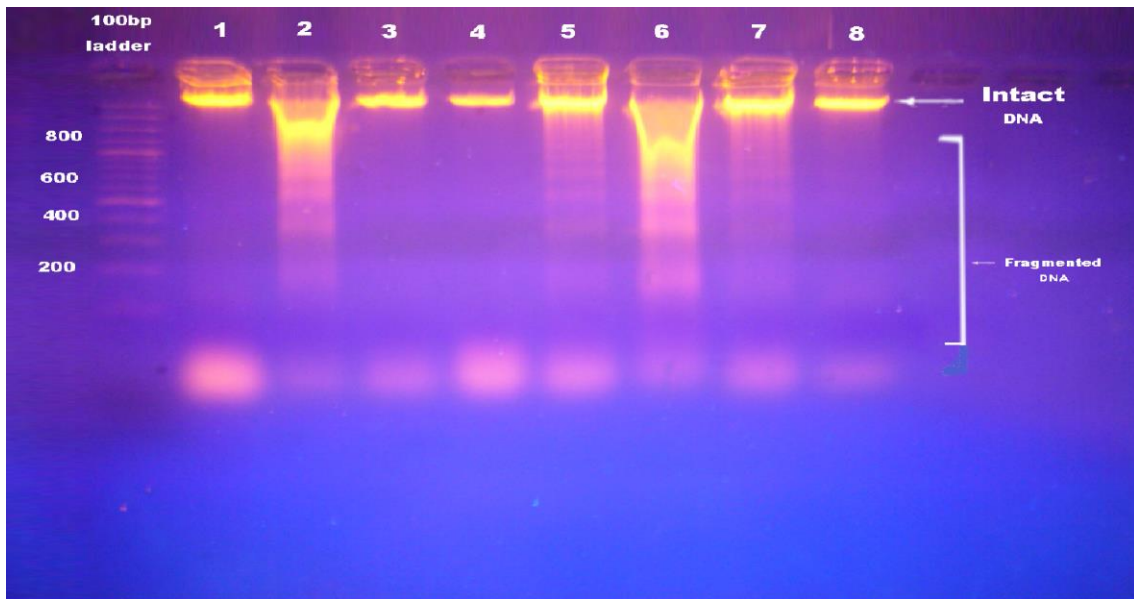


Figure (4): Apoptotic DNA fragmentation in liver of *S. mansoni* infected mice (7 weeks post infection) treated with bee venom or proplis. Lane 1: Normal control; Lane 2: Normal treated with bee venom sting; Lane 3: Normal treated with bee venom injection; Lane 4: Normal treated with proplis; Lane 5: Infected control; Lane 6: Infected treated with bee venom sting; Lane 7: Infected treated with bee venom injection & Lane 8: Infected treated with proplis.

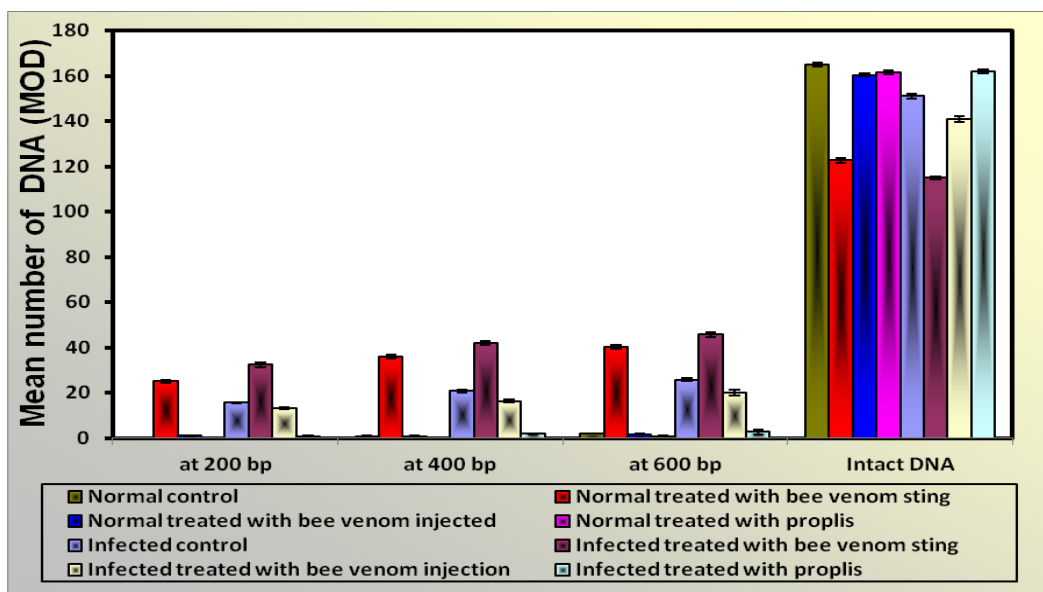


Figure (5): Mean of maximal optical density of apoptotic fragments of DNA in liver of *S. mansoni* infected mice treated with bee venom or proplis.

Table (1): Flow cytometry analysis of CD4 and CD8 of *S. mansoni* infected liver mice and treated with bee venom (sting or injection) or proplis.

Type T cell	CD4 (Mean percentage ± SER)	CD8 (Mean percentage ± SER)
Experimental groups		
Normal control	21.34±0.47	19.2± 0.29

Normal treated with bee venom sting	$^{\$}18.1 \pm 0.43$	$^{\$}6.9 \pm 0.27$
Normal treated with bee venom injection	$^{\$}16.16 \pm 0.27$	$^{\$}15.14 \pm 0.24$
Normal treated with proplis	$^{\$}29.2 \pm 0.43$	$^{\$} 22.34 \pm 0.31$
Infected mice (9 weeks post infection)	$^{\$}38.28 \pm 0.4$	$^{\$}22.57 \pm 0.29$
Infected mice treated with bee venom sting	$^{*}22.48 \pm 0.24$	$^{*}9.9 \pm 0.31$
Infected mice treated with bee venom injection	$^{*}31.3 \pm 0.35$	$^{*}34.44 \pm 0.3$
Infected mice treated with proplis	$^{*}34.79 \pm 0.26$	$^{*}42.6 \pm 0.33$

The number of mice/group = 7. The mice infected with 60 ± 5 *S. mansoni* cercariae/mouse, the treatment started on 7 weeks post infection for 2 weeks: All mice group were sacrificed after 2 weeks of treatment. Data are expressed as Mean percentage \pm SER. * Significant difference compared to infected control group at ($P \leq 0.05$). $^{\$}$ Significant difference compared to normal control.

DISCUSSION

Bee venom has a long tradition of use for the control of pain and inflammation in various chronic diseases. To our knowledge, there was no previous studies have investigated the bee venom treatment on murine hepatic damage with *Schistosoma mansoni*.

By using immune his to chemical CD34 staining, the present study demonstrated the participation of angiogenesis in hepatic schistosomal granulomas of mice in infected and treated infected groups. Hepatic section of infected mouse treated with bee venom or proplis revealed high expression of CD34 compared to infected mice. This result in agreement with Abdel- Fattah and Ahmed [26] who reported the evidence of intra-hepatic vascular proliferation remodeling early after cure in experimental schistosomiasis mansoni and mentioned the beneficial effect of vascular proliferation in the process of healing and restoration of liver tissue functions. Similar observations have also been reported in patients with schistosomiasis following treatment with praziquantel [27]. Folkman [28] mentioned that, angiogenesis is known to occur as an essential part of normal healing of wounds as well as in restoring blood flow to the tissues after injury. Total hepatic blood flow and hepatic function appear to be maintained by neo-vascularization of the periportal fibrotic tissue [29]. On the other hand, Huh et al. [13] found that bee venom inhibits tumor angiogenesis and metastasis by inhibiting tyrosine phosphorylation of vascular endothelial growth factor (VEGFR-2) in LLC-tumor-bearing mice.

Using flow cytometry analysis, the percentage of CD4 and CD8 increased in *S. mansoni* infected mice (9 weeks post infection) comparing with normal control. Where, CD4 T helper cells (Th) and CD8 T suppressor cells (Ts) are two types of T cells were defined within the granulomas [30]. The granulomatous process is dependent on CD4 T helper lymphocytes and requires the recruitment and migration of inflammatory cells into the site of inflammation [31]. *Schistosoma* eggs secrete molecules that are hepatotoxic. CD4 T helper cells responses are essential as immune protective mechanism to prevent hepatocytes damage during *S. mansoni* infection [32].

On contrast, normal mice treated with bee venom (sting or injection) showed decrease in mean percentage values of CD4 and CD8 compared with normal control. In the same time, *S. mansoni* infected group treated with bee venom sting indicated decrease in mean percentage values of CD4 and CD8 compared with infected mice. The same observations were reported by Kim et al. [33] who suggest that bee venom inhibits cytokine expression through the signaling pathway of inflammatory mediators. Moreover, bee venom treatment suppressed the production of Th1, Th2 and Th17- related cytokines in an in vitro culture system [34]. Also, Park et al. [35] indicate that melittin provided protection against galactosamine (GalN)/lip polysaccharide (LPS)-induced acute hepatic failure through the inhibition of inflammatory cytokines and apoptosis.

While percentage of CD4 and CD8 illustrated an increase in normal mice treated with propolis as compared with normal mice. Also, infected group treated with propolis led to significantly increase in percentage values of CD8 compared with infected group. These data are in agreement with the results of Kawakita et al. [36] whose reports indicate that several types of flavonols stimulate human peripheral blood leukocyte proliferation. They significantly increase the activity of helper T cells, cytokines, interleukin 2, γ -interferon and macrophages and are thereby useful in the treatment of several diseases caused by immune dysfunction.

At the level of molecular studies, electrophoretic pattern of nucleic acid of liver tissue illustrated that bee venom sting treated group induced DNA fragmentation in the form of apoptosis. Also, *S. mansoni* infection induced DNA damage. While, propolis treated groups showed a decrease in DNA liver damage. These findings run in parallel with the results of Ip et al. [37] who found that bee venom-induced cell morphological changes and decreased cell viability through the induction of apoptosis in TSGH-8301 cell. Where, bee venom treatment induces both caspase-dependent and caspase independent apoptotic death through intracellular Ca^{2+} -modulated intrinsic death pathway in TSGH-8301 cells. In addition, Jo et al. [38] suggest that bee venom and melittin induce apoptotic cell death in ovarian cancer cells through enhancement of death receptor 3, death receptor 4, and death receptor 6 expressions and inhibition of Signal transducers and activators of transcription 3 pathway. Moreover, Li et al. [39] indicated that melittin induce apoptosis in hepatic tissue. In the same time, Gjertsen et al. [40] indicated that Propolis not only decreased apoptosis but also increased the metabolic activity and proliferation of periodontal ligament cells.

CONCLUSION

In conclusion, bee venom injection reduced DNA damage caused by *S. mansoni* infection more than bee venom sting. Propolis caused progressive improvement of hepatic tissue on molecular level with repair the damage of DNA result from infection. Also, propolis treatment plays a good role during early cure of schistosomiasis by increasing angiogenesis in liver fibrosis.

REFERENCES

- [1] WHO .World Health Organization Schistosomiasis.2015 <http://who.int/mediacentre/factsheets/fs115/en/>
- [2] WHO "Weekly epidemiological record"2010; 18(85):157–164.
- [3] Takahashi K, Takeya M, Miyakawa K. The multiple roles of macrophages in hepatic granuloma formation in mice. In: Tanikawa, K., Ueno, T. (Eds.), *Liver Diseases and Hepatic Sinusoidal Cells*. SpringerVerlag, Tokyo.1999 pp. 128-140.
- [4] Mathew RC, Boros DL. *Infect Immun* 1986; 54: 820-826.
ANYAN WK SEKI T KUMAGAI T OBATA-NINOMIYA K FURUSHIMA-SHIMOGAWARA R
KWANSA-BENTUM B AKAO N BOSOMPEM KM BOAKYE DA WILSON MD KARASUYAMA
H OHTA N PARASITOL INT
- [6] Chensue SW, Boros DL. *J Immunol* 1979; 123:1409-1414.
- [7] Henderson GS, Lu X, McCurley TL, Colley DG. *J Immunol* 1992; 147: 2261-2269.
- [8] Lundy SK, Lerman SP, Boros DL. *Infect Immun* 2001; 69: 271-280.
- [9] WHO "Prevention and control of schistosomiasis and soil transmitted helminthiasis" WHO Technical Report Series 912: 2002 pp. 1–57.
- [10] Botros SS, Bennett JL. *Expert Opin Drug Discov* 2007; 2: 35–40.
- [11] Gomase VS, Phadnis AC, Ghatak AA. *Int J Drug Disc* 2009; 1: 14-17.
- [12] Chen J, Lariviere WR. *Prog Neurobiol* 2010; 92: 151–183.
- [13] Huh JE, Baek YH, Lee MH, Choi DY, Park DS, Lee JD. *Cancer Lett* 2010; 292: 98-110.
- [14] Hegazi AG, Abd El-Hady FK. *J Immunology* 1994; 1: 92-97.
- [15] Santana LC, Carneiro SM, Calando-Neto LB, Arcanjo DD, Moita-Neto JM, Cito AM, Carvalho FA. *Nat Prod Res* 2013; 28(5): 340-343.
- [16] Hassab EL-Nabi SE. *J Union Arab Biol* 2000; 14: 371-388.
- [17] Otsuki Y, Li Z, Shibala MA. *Prog Histochem cytochem* 2003; 38:275-339.
- [18] Hassab El-Nabi SE. *J Egypt Ger Soc Zool* 2004; 43C: 171-196.
- [19] Orsatti CL, Missima F, Pagliarone AC, Bachiega TF, Bufalo MC, Araujo Jr JP, Sforcin JM. *Phytother*

- Res 2010; 24: 1141-1146.
- [20] Schlingemann RO, Rietveld FJR, Dewaal RMW, Bradley NJ, Skene AI, Davies AJS, Greaves MF, Denekamp J, Ruiters DJ. *Lab Invest* 1990; 62(6):690-696.
- [21] Tribukait B, Moberger G, Zetterberg A. Methodological aspects for rapid flow cytofluorometry for DNA analysis of human urinary bladder cells. In: Haenen, C.; Hillen, H. and Wessels, S. eds. *Pluse cytophotometry*. European press Medicon. Ghent.1975; 1:55-60.
- [22] Cohen JJ, Al-Rubeai M. *Trends Biotechnol* 1995; 13: 281-283.
- [23] Dean PN, Jett JH. *J Cell Biol* 1974; 60: 523-527.
- [24] Aljanabi SM, Martinez I. *Nucleic acids Res* 1997; 25: 4692-4693.
- [25] Mc-Clave JT, Dietrich FH. *Statistics*. 4th Edition, Dellien Publishing Company, a division of Macillan publishing company. New York 1991.
- [26] Abdel Fattah NS, Ahmed NS. *Exp parasitol* 2012; 130: 58-62.
- [27] Vennervald BJ, Dunne DW. *Curr Opin Infec Dis* 2004; 17: 439-447.
- [28] Folkman J. *EXS* 1997; 79: 1-8.
- [29] Kanse SM, Liang O, Schubert U, Haas H, Preissner KT, Doenhoff MJ, Dennis RD. *Mol Biochem Parasitol* 2005; 144 (1): 76-85.
- [30] Roberts LS, Janovy JR. *Trematoda: form, function and classification of digeneans*. In: Gerald, D.; Schmidt, P. and Roberts, L. S. (eds). *Foundation of parasitology*. (7thEd). McGraw-Hill, Inc., 1221. A venue Americas, New York, N4 10020, 2005 P. 217.
- [31] Cheever AW, Hoffman KK, Wynn TA. *Immunol Today* 2000; 21: 465-466.
- [32] Rutitzky LI, Mirkin GA, Stactecker M J. *J Immunol* 2003; 171: 1859-1867.
- [33] Kim KH, Kum YS, Park YS, Park JH, Kim SJ, Lee WR, Lee KG, Han SM, Park KK. *Basic Clin Pharmacol Toxicol* 2010; 107: 619-624.
- [34] Choi MS, Park S, Choi T, Lee G, Haam KK, Hong M, Min B, Bae H. *Cytokine* 2013; 61: 256-265.
- [35] Park JH, Kim KH, Lee WR, Han SM, Park KK. *Apoptosis* 2012; 17: 61-69.
- [36] Kawakita SW, Giedlin HS, Nomoto K. *J Nat Med* 2005; 46: 34-38.
- [37] Ip SW, Chu YL, Yu CS, Chen PY, Ho HC, Yang JS, Huang HY, Chueh FS, Lai TY, Chung JG. *Int J Urol* 2012; 19: 61-70.
- [38] Jo M, Park MH, Kollipara PS, An BJ, Song HS, Han SB, Kim JH, Song MJ, Hong JT. *Toxicol Appl Pharmacol* 2012; 253: 72-81.
- [39] Li B, Gu W, Zhang C, Huang XQ, Han KQ, Ling CQ. *Oncol Res and Treat* 2006; 29: 367-371.
- [40] Gjertsen AW, Stothz KA, Neiva KG, Pileggi R. *Oral Surg Oral Med Oral Pathol Oral Radiol* 2011; 112: 843-848.