

Research Journal of Pharmaceutical, Biological and Chemical Sciences

Trends in The Sequential Approaches For Management Of Panfacial Fracture: A Systematic Review.

**Padmasree B Patowary*, Santhosh Kumar SN, Sanyukta S Raut, Kalyani Bhate,
Priyanjit P Saha, and Vaibhav Raut.**

Department of Oral and Maxillofacial Surgery, Dr. D.Y Patil Vidyapeeth's Dr. D. Y. Patil Dental College and Hospital, Pimpri,
Pune- 411018, Maharashtra, India.

ABSTRACT

The patterns of panfacial fracture are complicated and may vary from patient to patient. This makes the management of these fractures extremely challenging. In literature there are various surgical approaches mentioned. There are number of approaches for the management of panfacial fracture, such as, conservative and surgical approaches. The aim for any sequential approaches for management of panfacial fracture is to improve and maintain the patients' functional and aesthetic life style. Ultimately any approach should also aim to reduce confusion and improve patient's quality of life. To evaluate the various sequential surgical approaches for management of panfacial fracture. Authors searched data by the following methods: Electronic searches, Hand searching, Eligibility criteria, Inclusion criteria, 1. Articles with full text available in English, 2. In-vivo studies, retrospective and comparative studies, 3. Studies published between 1st January 1985 and 31st December 2015, 4. Study population should be above 18years. Exclusion criteria i. Age group below 18years. ii. Articles in other languages. iii. Review article, case report, letters to editors, editorials, and in-vitro studies are excluded. The electronic search identified a total of 120 publications (records identified through database searching 107 and additional records identified through other sources 13) of which 6 remained after removing duplicates. 6 articles were reviewed by three authors independently and were screened for eligibility. Then 6 full articles were selected for this review. There is a lack of evidence to support or refute the effects of the sequential surgical approaches of management of panfacial fracture. The most preferred approach is "bottom-up and outside-in" when the mandible is involved. When midface and upper face is involved, then "outside to inside" approach is employed. However, the sequential approach to be used for panfacial fractures is completely depended on the surgeon's knowledge and preference. There is clearly a need for comparative studies to investigate the effectiveness of sequential surgical approaches for management of panfacial fracture.

Keywords: Bottom-up approach, Inside-out approach, Maxillo-mandibular fracture, Maxillary Fracture, Mandibular fracture, Outside-in approach, Panfacial fracture, Panfacial fracture, Surgical sequential approach, Top-down approach.

**Corresponding author*

INTRODUCTION

Maxillofacial injuries are devastating to the mankind because of vital structures present near the area. The facial skeleton is divided into three divisions, namely: upper, middle and lower. Midfacial skeleton acts as a cushion, and is analogous to a 'matchbox' situated anterior and inferior to the cranium and superior to the rigid projection of the mandible.[1] This safety matchbox phenomenon prevents progression of forces to the cranium, making midface and lower face more prone injuries. These injuries may lead to soft tissue injuries and/or fracture of the facial skeleton. These maxillofacial fractures are divided region wise such as maxillary, mandibular, zygomatico-maxillary, naso-orbital-ethmoidal, frontal bone and frontal sinus fracture. When the injuries involved more than two regions they are collectively termed as panfacial fracture.[2]

The etiological factors for any maxillofacial injuries, including panfacial, are – road traffic accident (car accident, motorcycle accident, run over), inter-personal violence, fall, work accident, gunshot and ballistic injuries.[3]

Description of the condition-

Pan facial fracture is defined as fracture involving lower, middle and/or upper third of the face, where in mandible; maxilla and ZMC are frequently affected and accompanied by naso-orbitalethmoidal and/or frontal bone. [4,5]

Description of the intervention –

There are number of approaches for the management of panfacial fracture such as, conservative and surgical approaches.

Conservative Approach –

Historically, panfacial fracture were treated conservatively, by using various frames such as 'halo-frame', 'box-frame', 'Levant-frame' which were held in position using plaster of Paris splint.[1] Eventhough minimally invasive conservative management of panfacial fractures post gross drawbacks. Drawbacks of the approach like significant postoperative problems, crippling malocclusion, significant increase in facial width and decreased facial projection.[5] To overcome these drawbacks surgical approach has been described.

Surgical Approach –

Surgical approach involved open reduction and internal fixation in a sequential manner.[1]

Association for study of internal fixation guidelines (AO guidelines) describe two sequences bottom up and top down. However literature also suggest several other sequences for the management of panfacial fracture as mentioned below-

1. 'Bottom-up' approach
2. 'Outside-to-inside' approach
3. 'Top-to-bottom' approach
4. 'Immobile-mobile' approach
5. 'Simple-complicated' approach
6. 'Known to unknown' approach

How the intervention might work

The aim for any intervention for management of panfacial fracture is to improve and maintain the patient's functional and esthetic life style.

Why it is important to do this review

Panfacial fractures usually refer to simultaneous facial fractures, which affect the upper, middle, and lower thirds of the face. The management of panfacial fracture is complex because of the lack of reliable landmarks. Literature has shown many approaches for management of panfacial fractures. Every segment of bone has a precise function in the repair. Therefore, the “bottom-up and outside-in” sequence is the most widely used approach in the management of panfacial fractures. These facial fractures present remarkable challenges for both experienced and inexperienced surgeons.

This systematic review is an attempt to provide the practitioners as well as the patients proper guidelines regarding the trends of sequential approaches for management of panfacial fracture.

Focused question

What are the trends in treatment sequences of panfacial fracture?

Objective: To evaluate the trends in sequential approaches for management of panfacial fracture.

Eligibility criteria**Types of studies**

All retrospective and comparative studies, published between 1st January 1985 and 31st December 2015, were included and describing the sequential approaches for the management of panfacial trauma were selected in this systematic review.

Types of participants

Those studies in which patients were above 18 years old were included in this systematic review, requiring surgical intervention using various sequential approaches for the management of panfacial trauma.

Types of interventions

Studies describing the intervention regarding sequential approach in the management of panfacial trauma were included in this systematic review. For the purpose of analysis, the articles describing the following intervention were included such as, “bottom to top,” “top to bottom,” “inside-out,” “outside-in,” “bottom-top and outside-in”, “top-down and inside-out” “immobile-mobile and simple-complicated” and “known to unknown”.

Outcomes

These various approaches were aimed to restore both the aesthetic and functional outcomes.

Functional outcomes - Occlusion, mouth opening, stability of the fracture fragments, nerve function.

Aesthetic outcomes - Facial height, width and projection.

Information sources

Search methods for identification of studies Detailed search strategies were developed for each database searched. The articles language was restricted to English and studies published between 1st January 1985 and 31st December 2015. A systematic literature search on PubMed with multiple search terms was performed. The search terms and the number of articles found by employing these search strategies are shown in table no-1 and 2 respectively.

Table 1: Table showing key words used in this systematic review

Pan- facial trauma	Maxillo-mandibular trauma or maxillary trauma or mandibular trauma
Management	Bottom up approach or top to bottom approach or bottom up and outside in or inside out
Outcome	Esthetic outcome or functional outcome

Table 2: Table representing number of articles established using search strategy

Sr. No.	Search strategy	Number of articles	Number of selected articles	After duplicate removal
1	Pan-facial trauma and management	11	1	1
2	Pan-facial fracture and Management	7	1	0
3	Pan-facial trauma and topdown-outside in	1	1	1
4	Pan-facial trauma and bottom up and outside in	1	1	0
6	Panfacial fracture	87	5	1
7	Other findings	13	9	3
	Total	120	18	12

Electronic searches

Searched the following electronic databases:

- Pubmed
- EMBASE
- Google scholar
- Cross references
- Handsearching

The following journals were identified as being important to be hand searched for this review

- ✓ British journal of oral and maxillofacial surgery
- ✓ International journal of oral and maxillofacial surgery
- ✓ Clinical studies of maxillofacial surgery
- ✓ Plastic reconstruction surgery
- ✓ Journal of oral and maxillofacial surgery
- ✓ Institutional library data were also utilized in hand searching.

Data collection-

Review authors scanned independently the titles and abstracts of all studies which were found though the selected keywords. For studies, that appeared to meet the inclusion criteria or for which there was insufficient information in the title or abstracts to make a clear decision, the full report was obtained. Some studies were rejected because of not fulfilling the eligibility criteria.

Data extraction and management-

Review authors reviewed all article, then data extraction done. Tables made for explaining each article was discussed in detail for clarifying the study characteristics with outcomes and complications.

RESULTS

The electronic search identified a total of 120 publications (records identified through PubMed database searching 107 and additional 13 records identified through other sources). Of these 120 publications, 18 articles were selected. Then 12 articles were selected after removing duplicates. These 12 articles were screened by two review authors to remove 6 articles those were not relevant to this systematic review. The details of this exclusion are presented in table no-3. The remaining 6 articles were screened independently by three review authors to check the relevance of titles and abstracts (where available) for eligibility (Figure no – 1). Then 6 full articles were selected for this review. Finally those 6 articles were considered potentially eligible and full text copies were obtained. The details of these articles are shown in table no-4.

Table 3: Characteristics of excluded studies

	Study	Reason for exclusion
1.	Mauro pau et al. 2013	Described only the significance of starting the treatment from mandibular symphysis onwards. They did not mention any sequential surgical approaches for the management of panfacial fracture.
2.	Guyen e. Et al 2010	They did not mention any sequential surgical approaches for the management of panfacial fracture. This article was mainly concerned about incisions in the management of panfacial fracture.
3.	He d. Et al 2007	This retrospective study analyzed characteristics of delayed panfacial fractures and evaluated their treatment results.
4.	De malo et al 2013	Case reports are in exclusion criteria
5.	Sharma s et al. 2014	Case reports are in exclusion criteria
6.	Mall bb. Et al. 2014	Case reports are in exclusion criteria

Figure 1: Prisma 2009 Flow Diagram

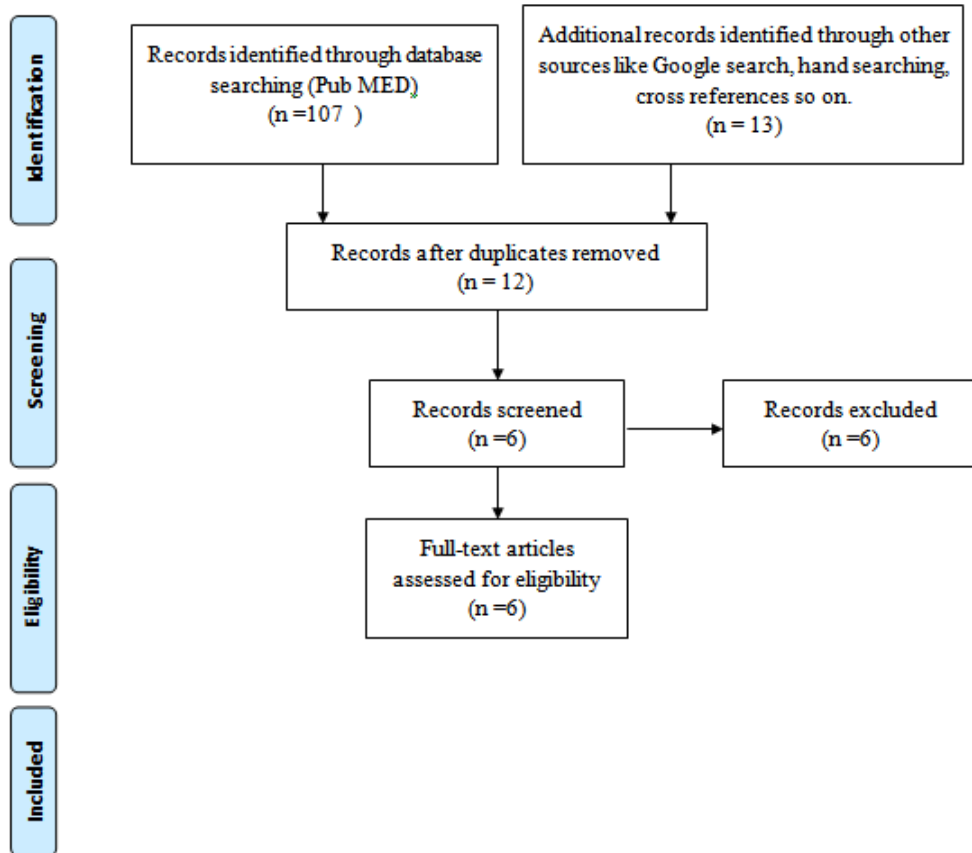


Table 4: Characteristics of included studies

Study id 1- tang et al.¹ (2009)

Methods	Retrospective study
Participants	A total of 68 patients with panfacial fracture were participants. They divided the patients in five groups: <ul style="list-style-type: none"> i. Zygomaticomaxillary complex (zmc) and mandible fractures (36), ii. Zmc and nasoethmoidal (noe) fracture (11), iii. Zmc, noe and mandible (9), iv. Frontal bone and/or frontal sinus and zmc (7) v. Frontal bone and/or frontal sinus and zmc and mandible (5).
Approach	In those entire group where mandible was fractured, they followed “bottom –up” approach. In rest of the groups “outside-in” approach was employed.
Outcomes	This study revealed that restoration of both form and function should confirm to principles of sequential surgical treatment for panfacial fractures. They also stated that reconstruction can be simplified by a highly organized treatment sequence.
Complications	These were few complications seen post operatively craniocerebral injury, cerebrospinal fluid leakage, diplopia, blindness or blurred vision, oculomotor paralysis, hypophysis
Notes	This study revealed that restoration of both form and function should confirm to principles of sequential surgical treatment for panfacial fractures. They also stated that reconstruction can be simplified by a highly organized treatment sequence. But it has no clear view, which approach is good.

Study id 2- yang et al¹⁴ (2012)

Methods	Retrospective study
Participants	A total of 107 patients with panfacial fracture were participants where 96 male and 11 female. They separated the panfacial fractures into 63 simple fractures (isolated linear fractures) and 44 complex fracture(3 regions fractures means zmc, maxilla and noe with liner fracture).
Approach	They underwent surgical management of panfacial fractures employing “bottom-up” and “outside-in” sequence
Outcomes	In 63 simple fracture outcome was excellent=43, good=14 fair =4, poor=2. In 44 complex fracture outcome was excellent =15, good=14, fair =12, poor=3. Evidenced of the validity of the bottom -up and outside-in approach.
Complications	Certain deficiencies are noticed post operatively like in the facial deformity(18), malocclusion(7), reduce mouth opening(28) and local deformity(23).
Notes	They clearly stated that, most panfacial fractures treated with the “bottom-up and outside-in” approach achieved good results. However, this sequence is not suitable for all pffs, including pffs with comminuted mandibular fractures concurring with obvious bone defects.

Study id 3 - degala s.et al.¹⁰(2015)

Methods	Comparative prospective study
Participants	11 male patients were participants in panfacial fractures. They compared two different treatment sequences.

Approach	5 participants bottom up–inside out 6 participants top-down–outside in
Outcomes	In both the approaches participants outcomes means stability and functions were satisfactory.
Complications	Various complications were seen like in one participant infection, parasthesia, oronasal fistula is seen and facial asymmetry was seen in 2 participants.
Notes	In bottom up approach these were reduced first, plating was done anteriorly. One in each group developed oronasal fistulas, which were surgically corrected later. In top-down approach palatal fractures were reduced after reducing zmc fractures. Within the limitation of low sample size they found that both bottom-up inside-out and top-down outside-in approaches have similar clinical outcomes but it is much appropriated study for this systematic review.

Table 4: giacomo et al. ²⁷ (2012)

Methods	Retrospective study
Participants	A total of 10 patients with panfacial fracture were participants with an extracapsular condylar fracture I. Unilateral condylar in 4 patients II. Bilateral condylar in 6 patients. Condylar fracture associated with 3 symphiseal, 7 parasymphiseal, 1 mandibular angle, 6 lefort ii , 3 orbitomaxillary and 5 zygomatic arch fracture.
Approach	All patients were operated by ‘bottom to top/ outside in sequence’.
Outcomes	A satisfactory reconstruction of the facial skeleton was achieved in all patients with a symmetry registered in both clinical and radiological assessments. There were no cases of malocclusion and a normal articular function with full range of temporomandibular joint were achieved(maximum interincisal opening greater then 35mm, no deviation on opening, lateral excursion greater then 6 mm).
Complications	No post operative complication seen. In one case needing a secondary scar revision.
Notes	According to the surgical sequence outside in and bottom to top, which they preferred the treatment of condylar fractures representing the starting point in the treatment planning if panfacial fracture. The treatment of extracapsular condylar fractures represents an essential aspect in the treatment of panfacial fractures. It frequently represents the first landmark that is restored, upon which the restoration of all the other fractures depends on.

Methods	Retrospective study
Participants	A total of 9 patients with panfacial fracture were participants with an extracapsular condylar fracture I. Unilateral condylar in 6 patients II. Bilateral condylar in 3 patients.
Approach	All patients were operated by ‘bottom to top/ outside in sequence’.
Outcomes	A satisfactory reconstruction of the facial skeleton was achieved. There was no evidence of malocclusion, articular dysfunction, open bite or other skeletal or dental anomalies. All patients were able to open the mouth from 31 to 40 mm, with minimal deviation or pain , during follow up.
Complications	There were no infections and radiographic examination.
Notes	According to them the correct re-establishment of the condyles

	<p>together with the restoration of posterior height and width of the face. Then maxillomandibular fixation done for achieve proper occlusion. It is then possible to define the anterior height of the midface by aligning the vertical buttresses of the maxilla.</p>
--	---

Table 5: Tullio Et Al ¹¹ (2000)

Study id 6- ramanujam I et al.²⁸ (2013)

Methods	Retrospective study
Participants	<p>A total of 15 patients with panfacial fracture were participants. The criteria for inclusion in the study were patients who had fractures of at least three of the four axial segments of the facial skeleton: Frontal, upper midface, lower midface and mandible. All patients (100%) had fractures of the mid face in different combinations. A total of 16 lefort ii fractures, in 9 patients were recorded; 7 patients had bilateral and 2 had unilateral fractures. Five lefort i fractures were recorded in 3 patients; 2 patients had bilateral and 1 had unilateral fractures. Four palatal splits were recorded in patients. Five lefort iii fractures were recorded in 3 patients; 2 patients had bilateral and 1 had unilateral fractures. Six unilateral zmc fractures were recorded in 6 patients. Four fractures of the noe complex were recorded in 4 patients. Two bilateral nasal bone fractures were seen in 2 patients. Fourteen patients had 20 fractures involving the mandible. 10 parasymphysis fractures were recorded in 9 patients; 1 patient had bilateral and 8 had unilateral fractures. Two symphysis fractures were seen in 2 patients. A total of 6 condylar fractures were recorded in 4 patients; 2 patients each had unilateral and bilateral fractures. Two angle fractures were recorded; 1 patient had bilateral fracture.</p>
Approach	Following exposure, the facial bone fractures are dis impacted and fixed in a sequential manner. The approach to reduce the facial fractures is “bottom up, inside out” and to fix them is “bottom up, outside in”.
Outcomes	No intra-operative complications were noted in any patient. Postoperatively, occlusion was found to be satisfactory in all patients over a period of time. Mouth opening and mandibular movements were adequate.
Complications	None
Notes	At author’s center, all facial bone fractures were disimpacted first and then fixed in a sequential manner. Their approach to reduce the facial bone fractures was “bottom up, inside out” and to fix them was “bottom up, outside in”. The mandible was reconstructed to establish a stable base. Next, the maxilla was guided into occlusion using the intact mandible as reference and mmf was done. After simultaneously visualizing all fracture sites, the “inside out” principle was employed to reduce the midface fractures in the following order: maxilla (lefort i level), noe, infra-orbital rims and zmc. Accurate anatomic reduction was achieved and according to the “outside in” principle, the fractures were fixed in a sequential manner. The zmc unit was fixed first and the zygomatic arch was lifted into position, if indicated. Next, osteosynthesis of the lefort I level fractures was performed and the palatal split, if present was fixed by either plating the fracture segments at the pyriform rim or in the palate. Then, the infra-orbital rims were reconstructed and finally, the noe unit was plated to the frontal bone and the maxillary buttresses.

DISCUSSION

Summary of main result

The face is aesthetically crucial, as it is the most visible area in human body and it controls important functions.⁵ It is made up of thicker bone with vertical and horizontal buttresses. In facial structures midface is a dependent structure, because of its thin bone and not particularly conducive to stability.[7]

The management of panfacial fracture should fulfill following two goals. To restore the 3D facial structure. To achieve the function. Although numerous approaches are enumerated in the English medical literature such as, 'bottom-up', 'top-down', 'outside-in' and 'inside-out', there was only one article describing the comparative sequential clinical study.[5-7,9] Also, five retrospective studies were eligible for this review. "Bottom-up" and "Outside-in" approaches have been reported as beneficial in some circumstances for the improvement of functional and esthetic outcome of the patient. However, such approaches have yet to be fully evaluated in comparative studies with large sample and at present, no firm conclusions can be drawn as to whether any of these methods provide better beneficial results. There is also a lack of trials directly comparing these surgical approaches.

LIMITATIONS

The overall quality of the evidence was not good, a judgment based on limitations such as –

- i. Lack of evidence- only few articles available comparing or describing this sequential surgical approach for management of panfacial fracture.
- ii. Number of sample size is less.
- iii. Heterogenous data.
- iv. Majority of the articles did not reveal post operative outcomes.

In future, more comparative studies are required with greater sample size, proper study design and evaluation of the outcome, which in turn improves the patient's quality of life.

CONCLUSION

Implications for practice

There is a lack of evidence to support or refute the effects of the sequential surgical approaches of management of panfacial fracture. In spite of, various surgical approaches, the most preferred approach is "bottom-up and outside in" when the mandible is involved. In mandible, specific sequence has to be employed. Majority of the authors suggest treating the condyle first followed by symphysis/ parasymphysis and angle. However few other authors have suggested managing symphysis first followed by parasymphysis, angle and condyle. Each of these approaches has their own advantages and disadvantages. Nevertheless, the recent studies suggest that in mandibular fractures starting from symphysis and going towards condyle is more advantageous as this follows "known to unknown" approach. If only midface and upper face is involved, then "outside-in" approach is employed. If there is remarkable comminuting fracture of mandible, sequencing should start from cranially to caudally (top-down approach). When there is fracture only to the midface than 'inside-out' approach is in used.

However, the sequential approach to be used for panfacial fractures is completely depended on the surgeon's knowledge and preference.

Implications for research

There is a need for comparative clinical trials with larger sample size to investigate the effectiveness of sequential surgical approaches for management of panfacial fracture. These trials should be conducted in specialist centers seeing large numbers of patients presenting with panfacial fracture.

REFERENCES

- [1] Banks P, Brown A. Fractures of the facial skeleton. Philadelphia, USA:Elsevier.1Ed,2001.
- [2] Tang W, Feng F, Long J, et al: Sequential surgical treatment for panfacial fractures and significance of biological osteosynthesis. Dent Traumatol. 2009;25:1386-1392.
- [3] Wulkan M, Parreira Jr, José G, Botter. Epidemiology of facial trauma. Rev Assoc Med Bras. 2005;51:290-295.
- [4] He D, Zhang Yi, Ellis E Panfacial fractures: Analysis of 33 cases treated late. [J Oral Maxillofac Surg.](#) 2007;65:2459-2465.
- [5] Curtis W, Horswell BB. Panfacial fractures: An approach to management. Oral Maxillofac Surg Clin N Am. 2013;25:649–660.
- [6] Cornelius C.P, Gellrich N, Hillerup S, Kusumoto K, Schubert W., AO guideline, 2009
- [7] Manson PN, Clark N. Subunit principles in midface fractures: The importance of sagittal buttresses, soft-tissue reductions, and sequencing treatment of segmental fractures. Plast Reconstr Surg. 1991;103:1287–1307.
- [8] Manson, P N Clark, N Robertson, B Crawley, W A Comprehensive management of panfacial fractures. J Cranio Maxillofac Trauma. 1995;1:43-56.
- [9] Gruss, J S Mackinnon, S E. Complex maxillary fractures: Role of buttress reconstruction and immediate bone grafts. Plast Reconstr Surg.1986;78:878-889.
- [10] Degala S., Sundar SS. Mamata, KS. A comparative prospective study of two different treatment sequences i.e. bottom up–inside out and topdown–outside in, in the treatment of panfacial fractures. J Maxillofac Oral Surg. 2015 ;14:986-994.
- [11] Tullio A, Sesenna E Role of surgical reduction of condylar fractures in the management of pan facial fractures. Br J Oral Maxillofac Surg 2000;38:472–476.
- [12] Gruss JS Bubak PJ, Egbert MA. Craniofacial fractures: An algorithm to optimize results. Clin Plast Surg 1992;19:195–206.
- [13] Yang R, Zhang C, Liu Y. Why should we start from mandibular fractures in the treatment of panfacial fractures? J Oral Maxillofac Surg. 2012;70(6):1386-1392.
- [14] Markowitz, B L. Manson P N. Panfacial fractures: Organization of treatment. Clin Plast Surg. 1989;16:105-114.
- [15] de Melo, Sonoda, Shinohara, Garcia. Using the "bottom-up and outside-in" sequence for panfacial fracture management: Does it provide a clinical significance? J Craniofac Surg. 2013;24:e479-481.
- [16] Wenig BL: Management of panfacial fractures. Otolaryngol Clin North Am. 1991; 24:93-101.
- [17] Gruss JS, Van Wyck L, Phillips JH, Antonyshyn O. The importance of the zygomatic arch in complex midfacial fracture repair and correction of posttraumatic orbitozygomatic deformities. Plast Reconstr Surg 1990;85:878–890.
- [18] Honig JF, Merten HA, Wiltfang J. Avoidance of implicit hazards: The realignment of maxillary and mandibular arches in comminuted and facial fractures. J Craniofac Surg 1998;9:514–521
- [19] Motamedi MH. An assessment of maxillofacial fractures: A 5-year study of 237 patients. J Oral Maxillofac Surg 2003;61: 61–64.
- [20] Jensen J, Sindet-Pedersen S, Christensen L. Rigid fixation in reconstruction of craniofacial fractures. J Oral Maxillofac Surg 1992;50:550–554.
- [21] Phillips JH, Forrest CR, Gruss JS. Current concepts in the use of bone grafts in facial fractures. Basic science considerations. Clin Plast Surg 1992;19:41–58.
- [22] Ellis E III, Moos KF, el-Attar A: Ten years of mandibular fractures: An analysis of 2,137 cases. Oral Surg Oral Med Oral Pathol 1985;59:120-129.
- [23] Erdmann D, Follmar KE, Debruijn M, et al: A retrospective analysis of facial fracture etiologies. Ann Plast Surg 2008;60:398-403.
- [24] Sawhney CP, Ahuja RB: Faciomaxillary fractures in North India: A statistical analysis and review of management. Br J Oral Maxillofac Surg 1988;26:430-444.
- [25] Ellis E 3rd, Tharanon W. Facial width problems associated with rigid fixation of mandibular fractures: Case reports. J Oral Maxillofac Surg 1992;50:87-94.
- [26] Rohner D, Tay A, Meng CS, et al. The sphenozygomatic suture as a key site for osteosynthesis of the orbitozygomatic complex in panfacial fractures: A biomechanical study in human cadavers based on clinical practice. Plast Reconstr Surg 2002;110:1463-71.
- [27] Rabbiosi D, Bardazzi A, Valassina D, Marelli S, Colletti G. Surgical access to condylar fractures in panfacial traumas. Minerva Stomatol. 2012 Oct;61(10):431-41.



- [28] Ramanujam L, Sehgal S, Krishnappa R, Prasad K. Panfacial fractures—A retrospective analysis at M.S. Ramaiah Group of Hospitals, Bangalore. *Journal of Oral and Maxillofac. Surg. Med. and Patho.* 2013; 25: 333–40.`