

Research Journal of Pharmaceutical, Biological and Chemical Sciences

Dynamics Of The Structural Organization Of Rachitic “Beads” At Pigs.

SM Suleymanov^{1*}, OB Pavlenko², PA Parshin³, VS Slobodyanik⁴, and AV Grebenshchikov⁵.

¹Doctor of Veterinary Sciences (Advanced Doctor), Professor of Dept. of Anatomy and Surgery, Voronezh State Agrarian University named after Emperor Peter the Great, Voronezh, the Russian Federation

²Doctor of Biological Sciences (Advanced Doctor), Professor of Dept. of Anatomy and Surgery, Voronezh State Agrarian University named after Emperor Peter the Great, Voronezh, the Russian Federation

³Doctor of Veterinary Sciences (Advanced Doctor), Professor, Chief Research Officer of the Department of Pharmacology of the All-Russian Research Veterinary Institute of Pathology, Pharmacology and Therapy of Russian Academy of Agricultural Sciences, Voronezh, Russian Federation

⁴Doctor of Biological Sciences (Advanced Doctor), Professor of Department of Technology of Production of an Animal Origin, Voronezh State University of Engineering Technologies (VSUET), Voronezh, the Russian Federation

⁵Candidate of Veterinary Sciences (Ph.D.), Associate Professor at Department of Technology of Production of an Animal Origin, Voronezh State University of Engineering Technologies (VSUET), Voronezh, the Russian Federation

ABSTRACT

In this article the dynamics of the structural organization of rachitic beads at rickets at pigs in groups of 0-2, 2-4 and 4-6 months is considered on spontaneous and experimental material. Rickets was reproduced by keeping of sows throughout all gestation and the young growth which was born subsequently on a rachitogenic diet, scarce on mineral substances and vitamins in autumn-winter period with those, to test subjects sows and piglets were deprived of ultraviolet radiation. It is established that at spontaneous rickets at pigs clinical symptoms of a disease were characterized by existence of lameness, the general slackness, a delay in growth and backbone curvatures and also a thickening in the form of rachitic beads at the end of the ribs. At the same time the limbs of patients with curved "X" or "O" shaped. Identical clinical symptoms of a disease of pigs of rickets have been found also at its experimental reproduction. In both cases, hypoglycemia and hypocalcemia with increased activity of alkaline phosphatase and content of parathyroid hormone were noted in the blood of piglets. In the structural organization of trailer departments of edges at pigs in age aspect the characteristic changes peculiar to this pathology – to rickets are revealed. The imbalance between bone formation and bone destruction was revealed, which was the initial cause of morphological restructuring of bone tissue and the development of the rachitic changes. The enchondral ossification of a bone tissue of edges was broken: it is superfluous cartilaginous and osteoid tissue expanded the zone of proliferation of a cartilage extended. As a result, typical pin-shaped rachitic rosary beads were developed on the terminal rib parts, consisting of huge fields of proliferating immature cells of cartilage tissue. At experimental rickets at pigs of change in trailer departments of edges were the same. Outside rachitic "beads" were covered with a wide layer of the periosteum, which consisted of 3 layers of dense connective tissue fibers, passing into a layer of cambial cells. There was an insufficient enchondral ossification to excess formation of cartilaginous tissue.

Keywords: Rickets, pigs, edges, cartilaginous tissue.

**Corresponding author*

INTRODUCTION

In the conditions of pig-breeding complexes, the presence of stress factors (hypodynamia and insufficient insolation, weaning processes, rearrangements, movements, vaccinations, inadequate feeding, etc.) causes the appearance of “technological” pathologies, the primary cause of which is metabolic disorders, reduced weight gain and increased incidence of piglets. In this case, the predominant pathology is rickets, caused primarily by a disorder of vitamin D metabolism, as well as calcium and phosphorus, as a consequence of dysfunction of osteogenesis [1, 2, 4, 8]. The history of the study of rickets, its wide distribution do not allow stating the sufficiency of the study of some etiological, diagnostic, therapeutic and preventive issues of this pathology. Modern data do not reveal all the variety of problems associated with the pathology of metabolism and histomorphogenesis of rickets. In addition, at the present stage of development of veterinary medicine little information is provided about postnatal development of newborns in the first months of life, as well as the limitless state of the body between health and disease [3,5,7, 9].

Thus, the development of methods for diagnosis of subclinical rickets is relevant, and also during the period of the violation of osteogenesis that is associated with the development of the rachitic “beads” in the area of joint of the rib and costal cartilage.

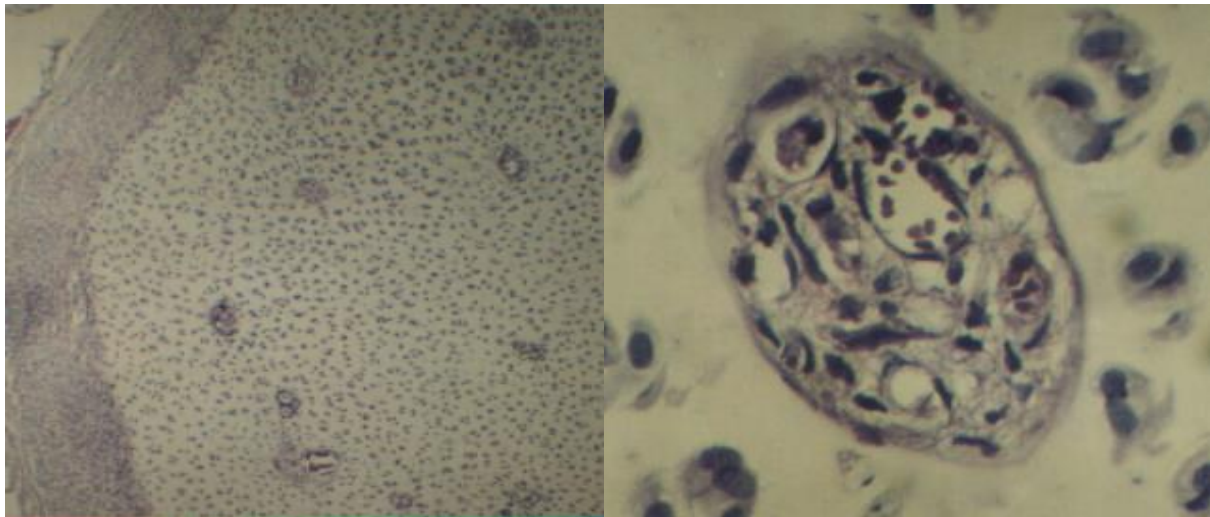
MATERIAL AND METHOD

Bone and cartilage tissue of ribs from clinically healthy and spontaneously ill of rickets piglets aged 0-2, 2-4 and 4-6 months was used for the study. Diagnosis of rickets was carried out comprehensively, using anamnestic, epizootic, clinical and pathomorphological data. Experimental reproduction of rickets in young pigs was carried out with the content of pregnant sows during pregnancy and young animals on feed, deficient in a number of minerals and vitamins during the autumn-winter unkeep period of natural insolation exclusion. For the implementation of clinical, biochemical and pathological monitoring 10-, 15-, 30-, 45- and 60 days of age (3 animal of each group) piglets suffering from rickets were killed. Bone tissue samples were fixed with 10% neutral formalin solution, compacted in a special Histomix environment; final sections were stained with hematoxylin-eosin [6].

RESULTS

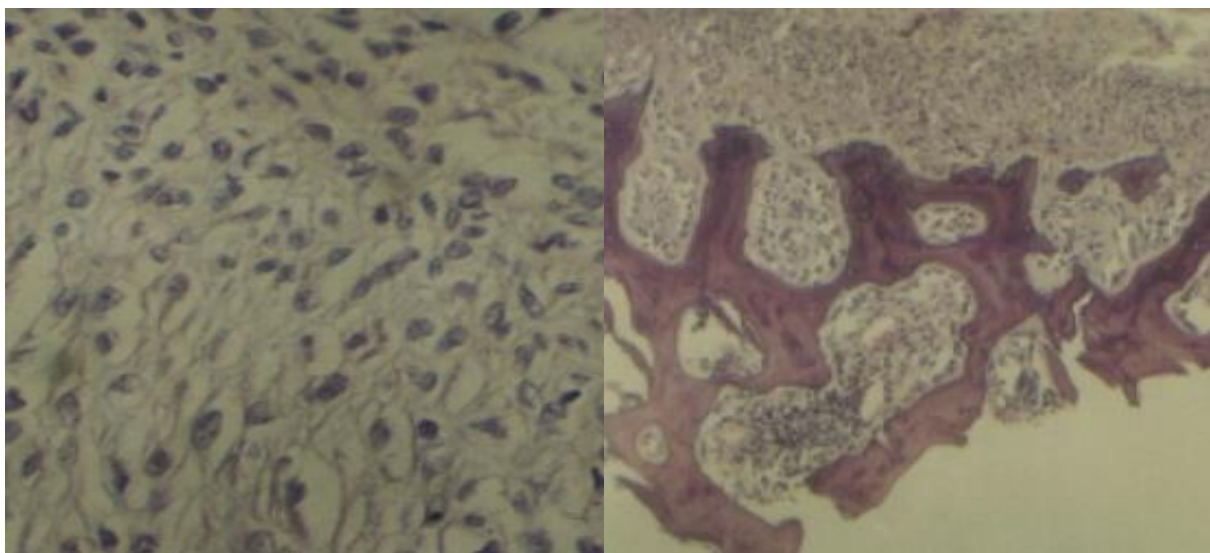
It was found that the clinical signs of rickets in piglets, both in spontaneous and experimental disease, were characterized by lameness, apathy, growth retardation, and spinal curvature. Also changes in the joints were noted, which were expressed by an increase, swelling and pain, the bones of the limbs of animals with rickets were formed “X” or “O” shape. In the area of rib-cartilaginous joints of the ribs of the sick young stock, rickets beads were noted. Hypoglycemia was detected in the blood serum of the sick animals, while the calcium content was reduced to 0.83 ± 0.05 mol/l (compared to normal 1.50 ± 0.06 mmol/l). At the same time, the amount of total calcium in the blood serum was within the physiological norm, also a significant increase in the activity of alkaline phosphatase to $12,60 \pm 3,70$ mmol (compared to normal $2,03 \pm 0,02$ mmol) was noted, and the content of the parathyroid hormone to $13,20 \pm 1,80$ mmol/l (against normal $6,8 \pm 0,50$ mmol/l). The level of calcitonin was within the physiological norm. This clinical picture is typical for young stock with rickets.

Dynamic change of rickets beads at the microstructure level corresponded to the age of piglets. At the same time, in 10-15-day-old young stock cartilage tissue was significantly expanded, in addition, it contained separate blood vessels (figure 1a, b), the microstructure of the periosteum of the ribs was characterized by the presence of powerful layers of connective tissue, as well as a small number of elongated cambial cells (figure 1c). Epiphyseal elements of the bone marrow cavity of the rib were characterized by expansion. Also an increase in individual fragments of the parallel plates of bone edges of the islets of bone marrow hematopoietic periosteal layering was revealed. Hematopoietic bone marrow foci were characterized by normal functional activity. In 30-day-old young pigs focal proliferation of rib cartilage was revealed. In the area of hypertrophied costal cartilage, a distinct thinning of compact bone tissue was revealed, characterized by an oriented bone marrow cavity (figure 1d). In the areas of resorption of the external insert plates of bone tissue, focal extension of the periosteum with proliferating cambial cells was observed, and oppression of myeloid hematopoiesis was also noted.



a)

b)



c)

d)

Fig 1: The microstructure of the costal cartilage of 15-30-days-old young pigs:a) Increase in the cartilage tissue area with blood capillaries; b) Endothelium of the blood capillary – a fragment of the picture" a";c) Proliferating cambial cells of the periosteum of the rib;d) Destructive changes in the bone plates of the rib.

The progression of rachitic changes of the endsections of the ribs was noted in 45-60 day young stock. Mace-like extensions of the ribs were observed due to active proliferation of the rib cartilage. Rib cartilage was characterized by the integration of single blood capillaries of myeloid hematopoiesis; which were followed by the reticulo-endothelial cells located at the periphery of the formed elements of blood. Vessels of the microcirculatory bed of the rib cartilage were also noted in the area of the periosteum. The transition region of the bone tissue of the rib in cartilage was characterized by an increase in the thickness of the chondroblast proliferation zone. At the same time, in the bone marrow cavities of the ribs, myeloid cells differed in dystrophy of different degrees (figure 2a, b). The process of osteogenesis in the rickets ill young stock was characterized by the penetration of the cartilage capsules and the deposition of osteoid taking place in the border area of the bone marrow cavity of the ribs with the epiphyseal cartilage and at different depths of the tissue. It was noted the lack of clear delineation of the cartilage and marrow cavity. In the bone tissue of some ribs, isolated areas of focal calcification were observed. Deformation of bone plates and bone marrow cavities of ribs was revealed. In some areas, bone tissue penetrated into the area of periosteum fragments and provoked a dentate fusion of bone tissue with the periosteum (figure 2c, d). Hematopoietic tissue was

characterized by a hypofunctional state, which contributed to the oppression of bone marrow and myeloid hematopoiesis (figure 2a). Largesing le forming mega caryocytes were also observed.

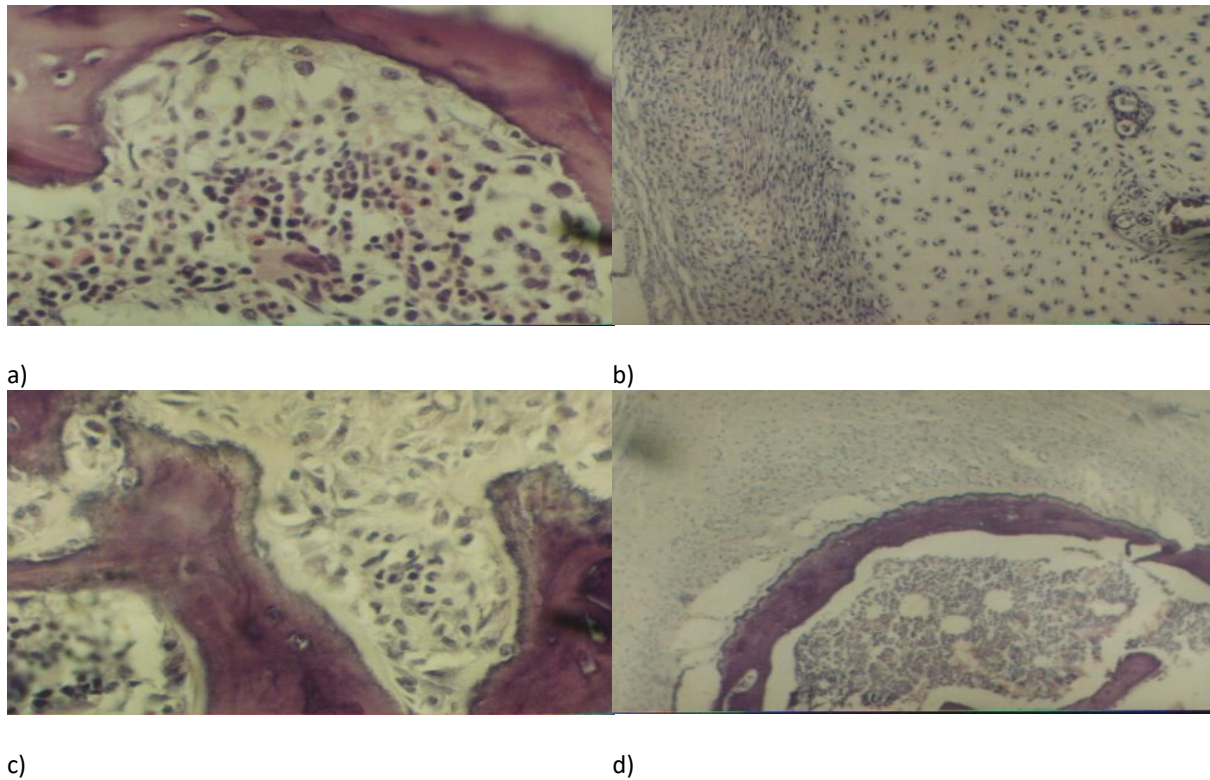


Fig 2: Microstructural organization of the ribs of 45-60 days old piglets:a) Hypofunctional state of the hematopoiesis system; b) A fragment of the structure of rachitic bead;c) Bone dystrophy of the rib; d) Thinning of rib bone plates.

Such a structural organization of the end of the rib in young pigs is usually characteristic of rickets. In addition, there was an imbalance between osteogenesis and osteodysplasia, which was the trigger of morphogenesis of rickets. There was a violation of the enchondral ossification of the bone tissue of the ribs, which was accompanied by hypertrophy of the cartilage and bone tissue, which led to the development of typical rickets beads. Such structural changes are significant symptoms in the diagnosis of rickets in piglets.

Changes in the end sections of the ribs during reproduction of rickets in young pigs are characteristic of rickets and have diagnostic value. These are the clavate rickets beads observed at the end of the ribs. Clavate thickening of the costal cartilage of the joints in rachitic beads are in the majority of cases, proliferating immature cells of the cartilage tissue (figure 3).Also in the end parts of the ribs there are single blood capillaries in the cartilage tissue. A wide layer of periosteum consisting of 3 longitudinal, circular and longitudinal layers of dense connective tissue was revealed along the periphery of the rickets beads. Then the periosteum passed into a layer of cambial cells, consisting of 2-3 rows of cells and is the border with cartilage tissue, which was actively proliferated.Chondroblasts, as a rule, at the time of proliferation had oval nuclei, consisting of 2-3 fragments. Proliferating chondroblasts in the rachitic beads of the ribs increased quantitatively and qualitatively. They had an oval nucleus, multiply, and then create parallel rows and stripes of differentiated chondrocytes with transverse plane core. Around them cytoplasmic vacuoles were formed, towards the brain layer of bone tissue increased and reached the border with bone tissue (figure 3).

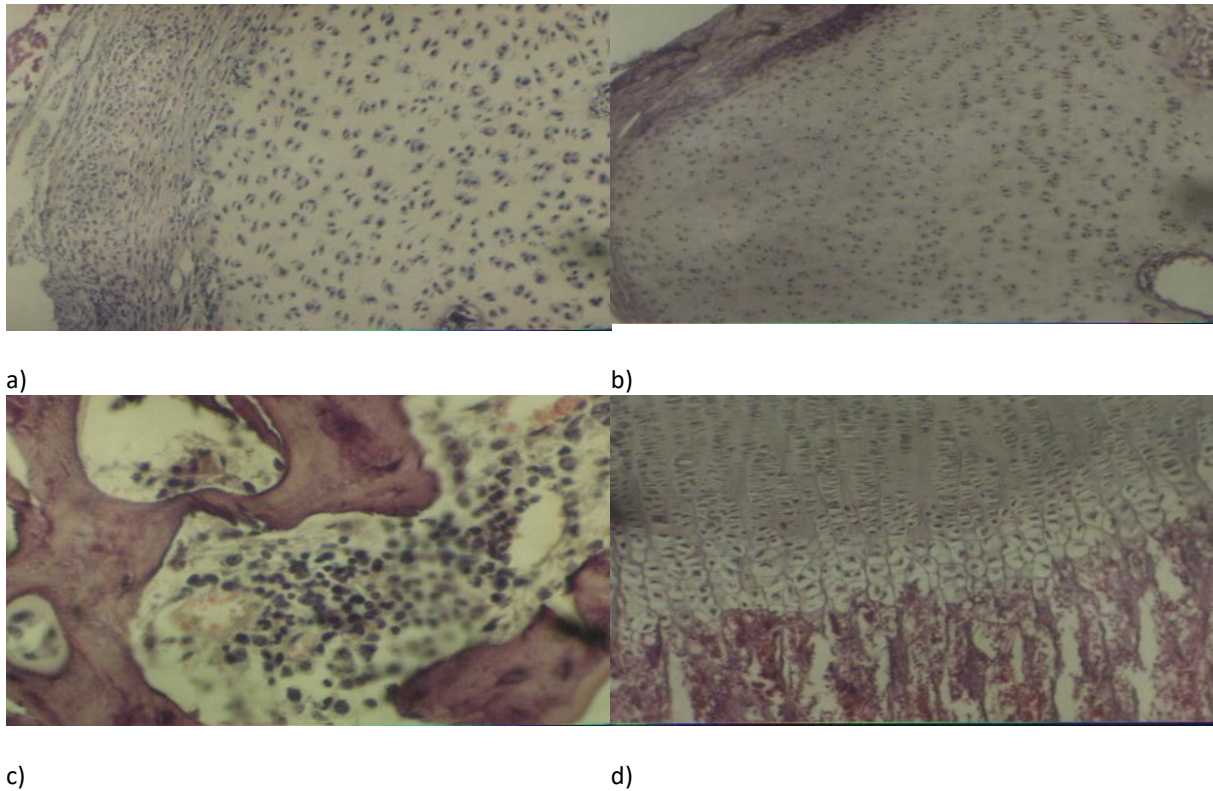


Fig 3: Microstructural organization of ribs in young pigs at experimental reproduction of rickets: a) Hypertrophy of the periosteum and cartilage tissue in the rickets bead; b) Fragment of the structure of the rickets bead; c) Prolonged transition of chondroblasts in osteoid cells; d) Hypofunction of hematopoietic tissue.

CONCLUSIONS

Thus, in the pathogenesis of rickets there was an uneven increase in ribs, one of the primary causes of which was hypertrophy of periosteal layers. The result was thinning of compact bone tissue, a layer of chondroblasts on the border of cartilage and bone tissue significantly exceeded the similar layer in healthy animals. Enchondral ossification occurred in the form of excessive proliferation of cartilage rib. Also extensive bone formation from the endo- and the periosteum was observed. In addition, bone tissue was characterized by insufficient deposition of calcium salts. Migration of cartilage capsules and the formation of osteoid were carried out not only in the epiphyseal cartilage, but also at different depths of the tissue. There was no marked border between the bone marrow cavity and cartilage. In 1.5-2.0-month-old piglets, cartilage cells sometimes were found in the bone marrow cavity. At the same time, the calcified tissue was a jagged, discontinuous line in the form of islets, which was sometimes invisible.

REFERENCES

- [1] Derezhina T.N. Rickets in pigs: dis. ...Doc. of Veter.Sciences: 16.00.01 / T.N. Derezhina. p. Persianovsky, 2005. 268 p. [Derezhina T.N. Rickets at pigs: yew.... dock. veterinarian. sciences: 16.00.01 / T.N. Derezhina. item Persianovsky, 2005. 268 p.]
- [2] Karput I.M. Immunology and immunopathology of young animals diseases//Minsk: Uradzhaj, 1993.P. 98-104 [Karput' I.M Immunology and immunopathology of young diseases // Minsk:Uradzhaj, 1993. P. 98-104].
- [3] Prudnikov S.I. Immunostimulants in the prevention of piglet diseases // Veterinary. 1996. issue. 11. P. 13-17 [Prudnikov S.I.Immunostimulants in the prevention of diseases of piglets // Veterinariya. 1996. № 11. P. 13-17].
- [4] Samokhin V.T. Prevention of violations of trace elements metabolism in animals // Voronezh, 2003. 136 p.[Samohin V.T. Prevention of metabolic disorders of microelements in animals // Voronezh, 2003. 136 p.].

- [5] Suleymanov S.M., Derezhina T.N., Parshin P.A. Microstructural organization of internal organs of piglets at rickets // Voronezh: Voronezh SAU, 2016. 97 p. [Sulejmanov S.M., Derezhina T.N., Parshin P.A. Microstructural organization of the internal organs of piglets in rickets // Voronezh: FGBOU VO Voronezhskij GAU, 2016. 97 p.].
- [6] Suleymanov S.M., Parshin P.A., Zharova Yu.P. Methods of morphological studies // Voronezh, 2000. 64 p. [Sulejmanov S.M., Parshin P.A., ZHarova YU.P. Methods of morphological studies // Voronezh, 2000. 64 p.].
- [7] Suleymanov S.M., Slobodyanik V.S. Structural and functional mechanisms of occurrence and development of pathology in young farm animals // Reports of RAAS. 2001. issue. 2. P. 39-42 [Sulejmanov S.M., Slobodyanik V.S. Structural and functional mechanisms of the origin and development of pathology in young animals of farm animals // Doklady RASKHN. 2001. №. 2. P. 39-42].
- [8] Van Saun R.I. Vitamin D – responsive rickets in neonatal lambs // Canad veter. J. 2004. Vol 45. N 10. P. 841-844.
- [9] Polyanskikh S.V. Ilyina N.M., Grebenshchikov A.V., Danyliv M.M., Klyuchnikova D.V., Dolmatova O.I., Bogdanova E.V. Products of animal origin with vegetable components // Indian journal of science and technology. 2016. Vol. 9. №39 P. 103431