

# Research Journal of Pharmaceutical, Biological and Chemical Sciences

## Protective Effect Of Resveratrol Against Hepatotoxicity Of Nicotine In Male Rat: Antioxidant And Histopathological Approaches.

Reham Z Hamza<sup>1,2\*</sup>, and Aisha A.Al-Rofaidi<sup>3</sup>.

<sup>1</sup> Zoology Department, Faculty of Science, Zagazig University, Zagazig, Egypt.

<sup>2</sup> Biology Department, Faculty of Science, Taif University, Taif 888, Saudi Arabia

<sup>3</sup> Biology Department, Faculty of Science, King Abdel Aziz University, Jeddah, Saudi Arabia.

### ABSTRACT

The most important dangerous effects of smoking and using of cigarette are the hazardous risk factor that resulted in mortality and incidence of hepatic diseases. Nicotine (NC) can freely transport via different body organs cell membranes. Resveratrol (Rs) is considered as polyphenols which is secondary plant metabolites and has the ability to scavenge free radicals. The study was designed to evaluate the capacities of Resveratrol (Rs) on Nicotine (NC) that induced hepatotoxicity, by assessment of some histopathological and biochemical alterations. 40 Male albino rats divided into 4 groups: The 1<sup>st</sup> group was control group, 2<sup>nd</sup> group was treated with NC (2.5 mg/kg), 3<sup>rd</sup> group was given Rs (20 mg/Kg), 4<sup>th</sup> group was treated with NC in combination with Rs. The results indicated that NC increased the liver enzymes (AST and ALT), ALP,  $\gamma$ -GT while reducing total protein level, NC induced elevation in MDA level while declining the other antioxidant enzymes (SOD, CAT and GPx) levels. A serious haemorrhage related to the liver was noticed in NC group and the role of Rs in alleviating the histopathological changes and hepatic oxidative damage. It is obvious that Rs has the ability to minimize the hepatotoxicity of NC.

**Keywords:** Nicotine, Resveratrol, Liver, Oxidative stress, Histopathology.

*\*Corresponding author*

## INTRODUCTION

Nicotine is an alkaloids which is found in tobacco, it is absorbed rapidly in the circulatory system and this inhalation is metabolized in the liver (*El-Sokkary et al.,2007*).

Nicotine also enhances the release of the free fatty acids from the liver (*Mulligan et al., 1983*). *Yuen and coworkers (1995)* demonstrated that specific concentration of nicotine may be as cigarette smoking was hepatotoxic.

Nicotine induces oxidative damage by increasing of free radical levels and elicited oxidative damage in different tissues treated with nicotine (*Wetscher et al., 1995*).

World Health Organization (WHO) reported that about more than 6 million death worldwide in 2013, was due to cigarette smoking. Cigarette smoke mainly contains nicotine (*Borgerding et al.,2012*). Cigarette smoking was essentially associated with abnormal lipid metabolism (*Bakhru and Erlinger.,2005*).

Smokers have showed high levels of C-reactive protein which is considered as an inflammatory factor and white blood cells, whereas they have declined albumin and total protein levels as compared to nonsmokers (*Bakhru and Erlinger.,2005*).

Resveratrol has resulted in vasodilation due to its potency for enhancing NO production, So resveratrol could result in lowering the blood pressure (*Abdu and Al-Bogami.,2019*).

Additionally, resveratrol can elicit production of different antioxidant enzymes in cardiac and vascular cells that lead to a decline in the oxidative damage markers (*Ungvari et al., 2010*). Resveratrol has antiaging activity and it is useful in the treatment of the neurodegenerative disorders .

Resveratrol is a polyphenolic compound, which exists in peanuts and grapes. It has antioxidant capacities, anti-inflammation , hepatoprotection and lipid metabolism modulation (*Baur and Sinclair, 2006*).

Several researchers have studied the protective effects of resveratrol against a oxidative damage (*Rubiolo et al., 2008*).

In animal or human, resveratrol provided the hepatoprotection against hepatotoxicity induced by many toxicants as carbon tetrachloride (*Elagamy, 2010*).

Most activation of toxicants occurs in the liver and thus cause hepatic damage. So, the current study was attended to evaluate the possible alleviation capacities of resveratrol against the nicotine hepatotoxicity . And this could be achieved through the biochemical , histological levels and antioxidant analysis of the hepatic tissues.

## MATERIALS AND METHODS

### Chemicals

Nicotine hydrogen bitartrate was purchased from Sigma Aldrich. Trans-Resveratrol was obtained from Cayman Company.

### Animals:

40 Male albino Wistar rats , weighing about 160–170 g, were obtained from the King Fahad center at King Abdulaziz University , Jeddah , Saudi Arabia. Animals were adapted for two weeks before the experimentation and provided with food and water.

**Experimental design:**

The NC and Rs doses were estimated according to *Kalpna and Menon (2004)* and *Oktem et al (2012)*. Rats were divided into four groups (n=10). Treatment with the tested compounds intraperitoneally (i.p) for 4 weeks as follows: 1<sup>st</sup> group served as control group and was administrated a normal physiological saline, 2<sup>nd</sup> group treated with NC (2.5 mg/kg), 3<sup>rd</sup> group treated with Rs with a dose of (20 mg/Kg). Finally , 4<sup>th</sup> group was treated with NC plus Rs.

**Blood collection**

Blood samples were harvested from the retro-orbital plexus *Boussarie.,(1999)*. Then, serum was used for biochemical analyses.

**Biomarkers of hepatic functions**

Serum lactic dehydrogenase (LDH) activity was determined by commercial kits. Activities of ALT and AST were determined by *Reitman and Frankel (1957)*. (ALP) and (γ-GT) activities were estimated according to *Young et al.(1999)* and *Orlowski and Meister (1965)*. Albumin and the total protein levels were evaluated by *Bowers and Wong (1980)* and *Bradford (1976)*, respectively.

Total cholesterol and triglycerides levels were determined as by *Carr et al. (1993)* . HDL-c and LDL-c were obtained by the method of *Warnick et al. (1983)*. However, VLDL-c levels were determined according to *Friedewald (1972)*.

**Tissue preparation**

Liver tissue (~0.35 g) was used for the analysis of oxidative stress parameters.

Tissues were immersed and homogenized with a 50 mM (Ice cold phosphate buffer) (pH 7.4). The resulting supernatant was used for assessment of antioxidant enzymes.

**Determination of antioxidant markers**

Lipid peroxidation was estimated by *Esterbauer and Cheeseman (1990)*. Superoxide dismutase (SOD) activity was measured by *Marklund and Marklund (1974)*. Catalase (CAT) activity was evaluated according to *Aebi (1986)*. Glutathione peroxidase (GPx) was determined by *Hafeman et al (1974)*. Total antioxidant capacity was determined according to *Prieto et al (1999)* .

**Histological evaluation**

A part of the liver tissues was fixed in 10% neutral buffered formalin and other processing as described by *Gabe (1968)*.

**RESULTS**

**Table 1: Effect of Nicotine and/or Resveratrol on some liver functions in male rats.**

Parameters	ALT (U/L)	AST (U/L)	ALP (U/L)	LDH (U/L)	γ-GT (U/L)	Total Protein (g/dl)
1- Control group	13.66±0.78 <sup>c</sup>	15.41±2.01 <sup>c</sup>	9.44±1.14 <sup>c</sup>	125.25±2.02 <sub>c</sub>	3.41±0.45 <sup>c</sup>	7.59±0.48 <sup>b</sup>
2- NC group	162.81±2.41 <sub>a</sub>	122.36±3.54 <sub>a</sub>	47.56±2.55 <sup>a</sup>	721.36±4.25 <sub>a</sub>	8.25±1.25 <sup>a</sup>	3.58±0.69 <sup>d</sup>
3- Rs group	13.23±1.54 <sup>c</sup>	13.58±1.02 <sup>c</sup>	8.58±1.02 <sup>c</sup>	120.25±3.05 <sub>c</sub>	3.21±0.47 <sup>c</sup>	8.14±1.25 <sup>a</sup>

4- NC +Rs group	93.58±2.14 <sup>b</sup>	73.32±2.25 <sup>b</sup>	17.36±1.59 <sup>b</sup>	201±3.25 <sup>b</sup>	5.01±0.58 <sup>b</sup>	6.28±1.69 <sup>c</sup>
-----------------	-------------------------	-------------------------	-------------------------	-----------------------	------------------------	------------------------

Means within the same column in each category (mean ± SE and n = 10) carrying different letters are significant at P ≤ 0.05 using Duncan’s multiple range test, where the highest mean value has the symbol (a) and decreasing in value were assigned alphabetically

NC: Nicotine; Rs: Resveratrol; ALT: Alanine aminotransferase ; AST :Aspartate aminotransferase; ALP: Alkaline phosphatase ; LDH: Lactate dehydrogenase ; γ-GT : Gamma glutamyl transferase.

The significant difference is arranged alphabetically from higher to lower. As shown in table (1) ALT, AST, ALP, LDH and γ-GT were markedly elevated in NC group with significant decrease in total protein levels. Treating with Rs afforded non-significant alterations in ALT, AST, ALP, LDH, γ-GT and total protein levels compared to the control group. All liver parameters had decreased significantly in the hepatic tissues of NC/Rs group as compared to NC group 42.59, 40.07, 63.49, 72.22, 39.27, 75.41% in ALT, AST, LDH, ALP and γ-GT respectively.

**Table 2: Effect of Nicotine and/ or Resveratrol on some antioxidant /oxidative stress parameters in liver of male rats.**

Parameters	SOD (U g <sup>-1</sup> )	CAT (U g <sup>-1</sup> )	GPx (U g <sup>-1</sup> )	MDA (U g <sup>-1</sup> )	TCA %
Control group	15.36±1.57 <sup>a</sup>	10.25±1.58 <sup>a</sup>	18.25±1.69 <sup>a</sup>	7.02±1.01 <sup>c</sup>	97.8% <sup>a</sup>
NC group	4.36±0.89 <sup>c</sup>	2.01±0.58 <sup>c</sup>	8.25±1.69 <sup>c</sup>	95.48±2.41 <sup>a</sup>	67% <sup>c</sup>
Rs group	15.35±1.47 <sup>a</sup>	10.32±1.24 <sup>a</sup>	18.35±1.69 <sup>a</sup>	7.00±0.89 <sup>c</sup>	98% <sup>a</sup>
NC+Rs group	12.03±1.41 <sup>b</sup>	7.36±0.78 <sup>b</sup>	14.03±1.69 <sup>b</sup>	23.54±2.14 <sup>b</sup>	85% <sup>b</sup>

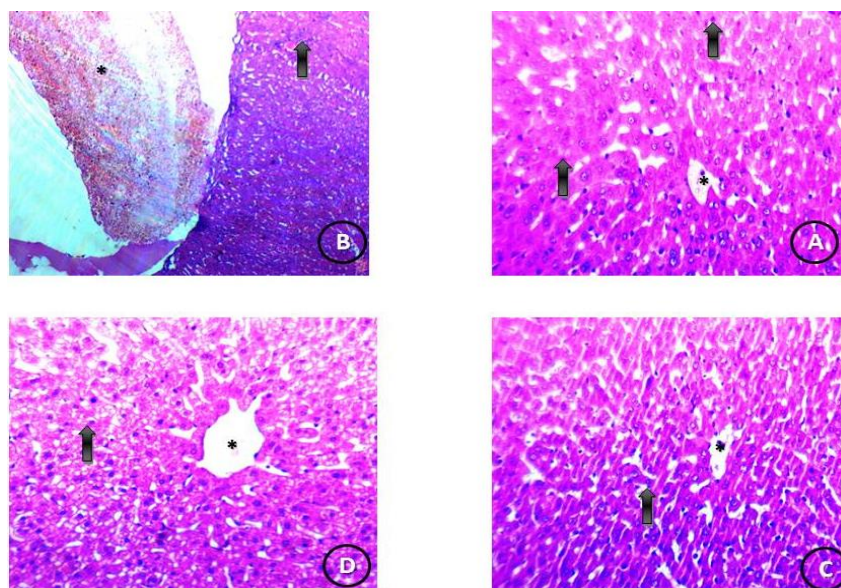
Means within the same column in each category (mean ± SE and n = 10) carrying different letters are significant at P ≤ 0.05 using Duncan’s multiple range test, where the highest mean value has the symbol (a) and decreasing in value were assigned alphabetically

NC: Nicotine; Rs: Resveratrol; SOD: superoxide dismutase; CAT: catalase; GPx: Glutathione peroxidase ;MDA: malondialdehyde; TAC: total antioxidant capacity.

The antioxidant enzymes (SOD, GPx and CAT) were decreased significantly after NC treatment (Table 2). Administration of Rs to the NC-group had restored these antioxidant enzymes significantly when compared to NC group alone. NC treated group decreased SOD activity that has been elevated when NC group was treated with Rs. The CAT activity had been declined markedly in the hepatic tissues of NC group as compared to the control group table (2).

The same finding has been obtained in the GPx activity that decreased by NC group and elevated by the Rs treatment after NC.

Regarding the oxidative damage in the hepatic tissues, Table 2 represents the MDA levels (end product marker of the lipid peroxidation). MDA levels were elevated greatly in NC group compared to the control group. The values of TAC were 97.8 %, 67%, 98% and 85 % for control, NC, Rs and NC and Rs respectively table (2).



Histopathological finding

Fig (1): Effect of Resveratrol and Nicotine on hepatic tissues. (A) Control group: Photomicrograph of normal hepatic tissues showing central vein (\*) surrounded by rows and trabeculae of normal liver cells (H&E x 400); (B) Nicotine group: Photomicrograph of hepatic tissues treated with nicotine showing a dilated congested central vein (\*) surrounded by degenerated liver cells (H&E x 400). (C) Resveratrol group: Photomicrograph of liver tissues treated with resveratrol showing central vein (\*) surrounded by normal cords of liver cells (H&E x 400). (D) Nicotine + Resveratrol group: Photomicrograph of hepatic tissues treated with Nic + Res showing improvement in the central vein (\*) but accompanied by fatty change of the liver cells (H&E x 400).

Table (3): Histopathological findings in liver of rats treated with Nicotine and Resveratrol

Findings	Groups			
	Control	Nicotine	Resveratrol	Nicotine + Resveratrol
Normal hepatic tissues	++++	-----	++++	+++-
Normal central vein	++++	+---	++++	+++-
Dilated congested central vein	----	++++	----	+++-
Degenerated liver cells	-----	++++	-----	+++-
Fatty change of liver cells	-----	++++	-----	+++-
Symbol	Meaning			
-----	Absence of the change.			
++++	A change which was often found.			
+++-	A change which was observed in almost group.			
++-	A change so often not observed in all group.			
—+	A change that was rare in the group			

DISCUSSION

Nicotine is a substance that is found in the tobacco and considered as a toxic compound. This includes cigarettes (*National Toxicology Program of the U.S. Department of Health and Human Services, 2002*). Most of the treatment trials weren't effective for smokers (*Ebbert et al., 2003*).

Hepatotoxicity is one of the most common diseases worldwide. Therefore, a lot of efforts were done for the treatment of liver diseases. Nicotine afforded several liver pathological alterations in male rats. The current study was aimed to estimate the level of resveratrol protection against the hepatotoxicity afforded by nicotine.

Cigarette smoking is a very common habit. Nicotine is considered as an essential component of cigarette smoke which is considered as a toxic compound (*Hoffmann et al., 1996*). *Shaw et al. (2000)* reported that "life is shortened by one cigarette by 11 min". Nicotine has an important effect on the cardiovascular diseases (*Sastry et al., 1995*).

Nicotine induced multi-alterations in cytochrome P-450 (*Anandatheerthavarada et al., 1993*), produces free radicals in a lot of tissues and induces oxidative tissue damage (*Guan et al., 2003*).

The liver is a major organ for metabolism and is affected greatly by the oxidative events that is associated with the nicotine toxicity.

Regarding this, administration of nicotine significantly increased the levels of free radical in the hepatic tissues as compared to the control group.

Also, GPx and SOD were declined significantly in the hepatic tissues of nicotine treated group. SOD was declined in the liver tissues. Our results are in agreement with Jenkins and *Goldfrab (1993)*, who reported that declined SOD activity is a reflection of incidence of oxidative stress. However, *Husain et al. (2001)* reported that chronic administration of nicotine declined liver GSH content and this in agreement with our obtained results in case of evaluation of GPx enzyme levels.

Oxidative stress is considered the main cause of various disorders (*Vendemiale et al., 1999*). Nicotine affords oxidative stress and play a vital role in most diseases in smokers. Various mechanisms explained that nicotine stimulates the free radicals production. Nicotine alters the respiratory chains (*Loft et al., 1994*).

Flushing and hepatotoxicity are important adverse effects of nicotinic acid (*Ralph., 2007*) and this is confirmed by the histological section that were obtained from nicotine treated group. Resveratrol in the current study induced decrease hepatic antioxidant enzymes due to nicotine treatment. Resveratrol oral administration was able to restore the normal histological structure.

Resveratrol administration significantly adjusted the nicotine induced biomarkers alterations of the hepatocellular injury as AST, ALT and ALP which are markers of hepatic damage (*Wegwu et al., 2005*) and their serum elevation revealed loss of the cell membrane functional integrity (*Rajesh and Latha, 2004*).

The hepatic enzymes AST, ALT and ALP were declined after the administration of resveratrol and this proved the hepatocytes improvement. AST is a marker of necrosis. ALT is an enzyme when increased, it increases in case of cases associated with the cell death (*Rosen and Keeffe, 2000*). ALP is an enzyme that arises mainly from the bile duct (*Muriel and Escobar, 2003*).

ALP is a cholestasis indicator (*Giannini et al., 2001*). The obstruction causes fats to be accumulated in the blood instead of being alleviated normally. Resveratrol decreased the AST, ALT and ALP levels, suggesting that resveratrol can be a good hepatoprotective agent (*Fan et al., 2009*).

Additionally, the declined total protein levels in nicotine group suggesting a decline in the protein synthesis. On the other hand, protein level was increased in resveratrol groups suggesting the hepatic cells amelioration.

Oxidative stress results in the breakdown of the phospholipids of the cell membrane and then leads to the formation of oxidation end products of oxidation such as malondialdehyde (*El-Shenawy et al., 2014*).

Free radicals which are generated during the nicotine metabolism, have a potent effect to interact with triglycerides of the hepatic cell membranes and could produce lipid peroxides.

The lipid peroxidation is a phenomena that is common in toxic mechanisms. It occurs under normal physiological conditions (*Chávez et al., 2008*).

The obtained results on hepatic tissues of nicotine-group showed a marked elevation in MDA levels as a significant decline in GPx levels. MDA is an oxidative stress marker. The significant decline of MDA levels and increment of glutathione enzyme in resveratrol treated animals may reflect a decline in the lipid peroxidation and increment of the tissue antioxidant defense enzymes. This indicates that resveratrol could reduce the free radicals generation and thus reduce the oxidative stress.

Resveratrol has proven previously against lipid peroxidation (*Rivera et al., 2008*). Rats treated with resveratrol only showed a normal physiological status which prove the safe using of resveratrol. Resveratrol induced a restoration effects on hepatic tissues (*Hong et al., 2010*).

The histological parameters for the evaluation of the liver cells damage. The necrosis in the nicotine group indicated the death of different cells of the liver. Fatty change of liver noticed in nicotine group reflects an imbalance of metabolism of lipids by the liver cells. The histopathological alterations in the liver of nicotine group suggested the presence of specific pathogenic pathway.

### CONCLUSION

Resveratrol have an improvement effect on the hepatic tissues. The obtained results indicate that the decline in the antioxidant status is contributing to the nicotine toxicity especially on the hepatic tissues. The observed significant increase in the reactive oxygen species in the hepatic tissues confirmed the occurrence of oxidative stress due to nicotine exposure, thus the hepatic tissues are subjected to high level of oxidative stress. Histological ameiorlation was observed after the administration of resveratrol to nicotine treated group. Resveratrol treatment remove the generated free radicals induced by nicotine.

### REFERENCES

- [1] M.F. Borgerding, J.A. Bodnar, G.M. Curtin, J.E. Swauger, Regul. Toxicol. Pharmacol. 64 (2012) 367–387.
- [2] A. Bakhru, T.P. Erlinger, PLoS Med. 2 (2005) e160.
- [3] C.S. Brischetto, W.E. Connor, S.L. Connor, J.D. Matarazzo, Am. J. Cardiol. 52 (1983) 675–680.
- [4] F.S. Facchini, C.B. Hollenbeck, J. Jeppesen, Y.D. Chen, G.M. Reaven, Lancet 339 (1992) 1128–1130.
- [5] B. Eliasson, N. Mero, M.R. Taskinen, U. Smith, Atherosclerosis 129 (1997) 79–88.
- [6] Gamal H. El-Sokkary, Salvatore Cuzzocrea, Russel J. Reiter. 2007. Effect of chronic nicotine administration on the rat lung and liver: Beneficial role of melatonin. Toxicology 239 (2007) 60–67.
- [7] Mulligan, J., Cluette, J.E., Kew, R.R., Stack, D.J., Hojnacki, J.L., 1983. Cigarette smoking impairs hepatic uptake of high density lipoproteins. Biochem. Biophys. Res. Commun. 112, 843–850.
- [8] Yuen, S.T., Gogo Jr., A.R., Luck, I.C., Cho, C.H., Ho, J.C.I., Loh, T.T., 1995. The effect of nicotine and its interaction with carbon tetrachloride in the rat liver. Pharmacol. Toxicol. 77, 225–230.
- [9] Wetscher, G.J., Bagchi, M., Bagchi, D., Perdakis, G., Hinder, P.R., Glaser, K., Hinder, R.A., 1995. Free radical production in nicotine treated pancreatic tissue. Free Radical Biol. Med. 18, 877–882.
- [10] Abdu, S.B., Al-Bogami, F.M. 2019. Influence of resveratrol on liver fibrosis induced by dimethylnitrosamine in male rats. Saudi Journal of Biological Sciences 26 (2019) 201–209.
- [11] Ungvari, Z., Bagi, Z., Feher, A., Recchia, F.A., Sonntag, W.E., Pearson, K., De Cabo, R., Csizsar, A., 2010. Resveratrol confers endothelial protection via activation of the antioxidant transcription factor Nrf2. Am. J. Physiol. Circ. Physiol. 299, H18–H24.
- [12] National Toxicology Program of the U.S. Department of Health and Human Services, 2002. 10th Report on Carcinogens. Available from: <http://ehp.niehs.nih.gov/roc/toc10.html>. Accessed November 12, 2004. Retrieved September 10, 2004.
- [13] Ebbert, J.O., Rowland, L.C., Montori, V.M., Vickers, K.S., Erwin, P.J., Dale, L.C., 2003. Treatments for spit tobacco use: a quantitative systematic review. Addiction 98, 569–583.
- [14] Hoffmann, D., Rivenson, A., Hecht, S.S., 1996. The biological significance of tobacco-specific N-nitrosamines: smoking and adenocarcinoma of the lung. Crit. Rev. Toxicol. 26, 199–211.
- [15] Sastry, B.V., Chance, M.B., Singh, G., Horn, J.L., Janson, V.E., 1995. Distribution and retention of nicotine and its metabolite, cotinine, in the rat as a function of time. Pharmacology 50, 128–136.

- [16] Shaw, M., Mitchell, R., Dorling, D., 2000. Time for a smoke? One cigarette reduces your life by 11 min. *BMJ* 320, 53.
- [17] Anandatheerthavarada, H.K., Williams, J.F., Wecker, L., 1993. The chronic administration of nicotine induces cytochrome P-450 in rat brain. *J. Neurochem.* 60, 1941–1944.
- [18] Guan, Z.Z., Yu, W.F., Nordberg, A., 2003. Dual effects of nicotine on oxidative stress and neuroprotection in PC12 cells. *Neurochem. Int.* 43, 243–249.
- [19] Goldfrab, A., Jenkins, R.R., 1993. Introduction: oxidant stress, aging and exercise. *Med. Sci. Sports Exerc.* 25, 210–212.
- [20] Loft, S., Astrup, A., Buemann, B., Poulsen, H.E., 1994. Oxidative DNA damage correlates with oxygen consumption in humans. *FASEB J.* 8, 534–537.
- [21] Vendemiale, G., Grattagliano, I., Altomare, E., 1999. An update on the role of free radicals and antioxidant defense in human disease. *Int. J. Clin. Lab. Res.* 29, 40–55.
- [22] Husain, K., Scott, B.R., Reddy, S.K., Somani, S.M., 2001. Chronic ethanol and nicotine interaction on rat tissue antioxidant defense system. *Alcohol* 25, 89–97.
- [23] Ralph H. Stern, The role of nicotinic acid metabolites in flushing and Hepatotoxicity. *Journal of Clinical Lipidology* (2007) 1, 191–193.
- [24] Bhat, K.P.L., Kosmeder 2nd, J.W., Pezzuto, J.M., 2001. Biological effects of resveratrol. *Antioxid. Redox Signal.* 3, 1041–1064.
- [25] Rubiolo, J.A., Mithieux, G., Vega, F.V., 2008. Resveratrol protects primary rat hepatocytes against oxidative stress damage: activation of the Nrf2 transcription factor and augmented activities of antioxidant enzymes. *Eur. J. Pharmacol.* 591, 66–72.
- [26] Elagamy, D.S., 2010. Comparative effects of curcumin and resveratrol on aflatoxin B1- induced liver injury in rats. *Arch. Toxicol.* 84, 389–396.
- [27] Kalpana C, Menon VP: Protective effect of curcumin on circulatory lipid peroxidation and antioxidant status during nicotine-induced toxicity. *Toxicol Mech Methods* 2004;14:339–43.
- [28] Oktem G, Uysal A, Oral O, Sezer ED, Olukman M, Erol A: Resveratrol attenuates doxorubicin-induced cellular damage by modulating nitric oxide and apoptosis. *Exp Toxicol Pathol* 2012; 64:471–9.
- [29] Boussarie D: Hématologie des rongeurs et lagomorphes de compagnie- *Bull. Acad. Vét. De France* 1999;72: 209-216.
- [30] Marklund S, Marklund G: Involvement of the superoxide anion radical in the autoxidation of pyrogallol and a convenient assay for superoxide dismutase". *Europ. J. Biochem* 1974; 47: 469–474.
- [31] Reitman S., Frankel S.A. (1957) colorimetric method for the determination of serum glutamic oxalacetic and glutamic pyruvic transaminases. *Amer J Clin Pathol.* 28, 56-63.
- [32] Young D.C., Koon H.R., Hyung K.C. (1999). In vitro and in vivo experimental effect of Korean red ginseng on erection. *J. Urol.* 162, 1508-1511.
- [33] Orłowski M., Meister A. (1965) Isolation of gamma-glutamyl transpeptidase from hog kidney. *J Biol Chem.* 240, 338-347.
- [34] Bowers L.D., Wong, E.T. (1980) Kinetic serum creatinine assays. II. A critical valuation and review. *Clin Chem.* 26(5), 555-61.
- [35] Bradford M.M. (1976) A Rapid and Sensitive Method for the Quantitation of Microgram Quantities of Protein Utilizing the Principle of Protein-Dye Binding. *Anal. Biochem.* 72, 248-254.
- [36] Carr T., Andressen C.J., Rudel L.L. (1993) Enzymatic determination of triglyceride, free cholesterol and total cholesterol in tissue lipid extracts. *Clin Chem.* 26, 39–42.
- [37] Warnick G.R., Benderson J., Albers J.J (1983) Selected methods of clinical chemistry. *Amer Assoc. Clin. Chem.* 10, 91–9.
- [38] Friedewald W.T. (1972) Estimation of concentration of low-density lipoprotein cholesterol in plasma without use of the preparative ultracentrifuge. *Clin. Chem.* 18, 499–502.
- [39] Esterbauer H, Cheeseman KH: Determination of aldehydic lipid peroxidation products: malonaldehyde and 4-hydroxynonenal. *Methods Enzymol* 1990;186: 407–421.
- [40] Aebi DJ: Glucose-6-phosphate dehydrogenase. In: Bergmeyer HU, editor. *Methods of enzymatic analysis.* 2nd ed. Weinheim: VCH Verlagsgesellschaft mbH 1986;190–6.
- [41] Hafeman D, Sunde G and Hoekstra WG: "Effect of dietary selenium on erythrocyte and liver glutathione peroxidase in the rat". *J. Nutr* 1974; 104:580-587.
- [42] Prieto P, Pineda M, Aguilar M: "Spectrophotometric quantitation of antioxidant capacity through the formation of a Phosphomolybdenum complex specific application to the determination of vitamin E". *Anal. Biochem* 1999; 269:337–341.
- [43] Gabe M: *Techniques histologiques [Histological Techniques]*. Paris: Masson Publisher 1968.



- [44] Wegwu, M.O., Ayalogu, E.O., Sule, O.J., 2005. Anti-oxidant protective effects of Cassia alata in rats exposed to carbon tetrachloride. *J. Appl. Sci. Environ. Manage.* 9, 77–80.
- [45] Rajesh, M.G., Latha, M.S., 2004. Preliminary evaluation of the antihepatotoxic activity of Kamilar, a polyherbal formulation. *J. Ethnopharmacol.* 91, 99–104.
- [46] Rosen, D.R., Siddique, T., Patterson, D., Figlewicz, D.A., Sapp, P., Hentati, A., Donaldson, D., Goto, J., O'Regan, J.P., Deng, H.-X., others, 1993. Mutations in Cu/Zn superoxide dismutase gene are associated with familial amyotrophic lateral sclerosis. *Nature* 362, 59–62.
- [47] Muriel, P., Escobar, Y., 2003. Kupffer cells are responsible for liver cirrhosis induced by carbon tetrachloride. *J. Appl. Toxicol.* 23, 103–108.
- [48] Giannini, E., Botta, F., Fasoli, A., Romagnoli, P., Mastracci, L., Ceppa, P., Comino, I., Pasini, A., Risso, D., Testa, R., 2001. Increased levels of cGT suggest the presence of bile duct lesions in patients with chronic hepatitis C. *Dig. Dis. Sci.* 46, 524–529.
- [49] Fan, G., Tang, J.J., Bhadauria, M., Nirala, S.K., Dai, F., Zhou, B., Li, Y., Liu, Z.L., 2009. Resveratrol ameliorates carbon tetrachloride-induced acute liver injury in mice. *Environ. Toxicol. Pharmacol.* 28, 350–356.
- [50] El-Shenawy NS, AL-Harbi MS, Hamza RZ: Effect of vitamin E and selenium separately and in combination on biochemical, immunological and histological changes induced by sodium azide in male mice. *Experimental and Toxicologic Pathology* 2014; 67: 65–76.
- [51] Chávez, E., Reyes-Gordillo, K., Segovia, J., Shibayama, M., Tsutsumi, V., Vergara, P., Moreno, M.G., Muriel, P., 2008. Resveratrol prevents fibrosis, NF- $\kappa$ B activation and TGF- $\beta$  increases induced by chronic CCl<sub>4</sub> treatment in rats. *J. Appl. Toxicol.* 28, 35–43.
- [52] Hong, S.-W., Jung, K.H., Zheng, H.-M., Lee, H.-S., Suh, J.-K., Park, I.-S., Lee, D.-H., Hong, S.-S., 2010. The protective effect of resveratrol on dimethylnitrosamine-induced liver fibrosis in rats. *Arch. Pharm. Res.* 33, 601–609.
- [53] Rivera, H., Shibayama, M., Tsutsumi, V., Perez-Alvarez, V., Muriel, P., 2008. Resveratrol and trimethylated resveratrol protect from acute liver damage induced by CCl<sub>4</sub> in the rat. *J. Appl. Toxicol.* 28, 147–155.