

# Research Journal of Pharmaceutical, Biological and Chemical Sciences

## Mast cell variation in some commonly encountered lesions of salivary glands

Seema V<sup>a\*</sup>, VL Pattankar<sup>b</sup>

<sup>a</sup>Dr.SeemaV, Dept. of Pathology, Kasturba Medical College, Manipal University, Manipal.

<sup>b</sup>Dr.V.L.Pattankar, Dept. of pathology, M.R. Medical College, Gulbarga.

### ABSTRACT

Mast cells with a battery of crucial chemical mediators in their typical metachromatic granules are known to play a role in health and various disease states in man. This study was undertaken to evaluate the mast cell profile in some commonly encountered salivary gland lesions. The present study was carried out in the Department of Pathology, M.R. Medical College, Gulbarga after the institutional ethical clearance. The study included a total of 50 cases in each group. Sections were stained with H&E and 1% aqueous toluidine blue (pH=4) for mast cells. The mast cell count was performed per 10 HPF, tabulated, analyzed for statistical significance using students' t' test. A significant ( $p < 0.001$ ) increase of mast cell was observed in commonly encountered lesions of salivary gland when compared with that of control group. Mast cell count was significantly increased in Pleomorphic adenoma as compared to basal cell adenoma and oncocytoma. The present study documents striking alteration in mast cell in some common salivary gland lesions. Mast cell profile may be used as an additional diagnostic or supportive parameter to differentiate between various benign lesions of salivary gland in addition to other diagnostic parameters.

**Key Words:** Mast cells; Salivary gland lesions; Pleomorphic adenoma.

*\*Corresponding author*

## INTRODUCTION

Mast cell remains an enigmatic, fascinating and highly engineered cell more than 100 years after its discovery by Paul Ehrlich at the turn of the 18<sup>th</sup> century. The mast cells with a battery of crucial chemical mediators and substances in their typical metachromatic granules are known to play a role in health and various disease states in man [1]. Human mast cells are heterogeneous groups of tissue dwelling cells with multifunctional roles in conditions as diverse as allergy, parasitic infestation, inflammation and various neoplastic disorders [2].

Mast cells are distributed throughout the human organism and in whole occupy roughly the volume of spleen. Mast cells are ubiquitous though they are being found in varying numbers in practically all tissues their proportion is increased within mucosal membranes lining the respiratory, digestive, urogenital systems, throughout the dermis and vicinity of surrounding blood vessels [3]. Many theories have been proposed for the origin of mast cells. Currently it is believed that mast cell originates from the pluripotent haemopoietic progenitor cell in bone marrow [4]. Mast cells settle in connective tissue and usually do not circulate in the blood stream. They contain special cytoplasmic granules which store mediators of inflammation. Degranulation may be induced by physical destruction, chemical substances and immune mechanisms which may be IgE dependent or IgE independent [5].

Mast cells play a vital role in various inflammatory and immunopathologic reactions often linking the humoral and cell mediated phases of the process. The cross-linking of high affinity binding sites of mast cells with IgE occurs after exposure to neuropeptides such as substance P after mechanical or thermal stimuli, which causes degranulation of mast cells. Degranulation of mast cells generally occur within minutes of exposure to stimuli and usually entire granules are extruded. Concomitant with their release into the extracellular space, the granules release their preformed and stored mediators which may contribute to allergic, inflammatory and chronic inflammatory responses.

A careful search of the literature reveals that marked paucity of knowledge regarding the variation of mast cells in various salivary gland lesions. With this stimulus of lacunae in the knowledge of mast cells in various salivary gland lesions, an attempt was made to evaluate the mast cell profile in some commonly encountered salivary gland lesions.

## MATERIALS AND METHODS

The present study was carried out in the Department of Pathology, M.R. Medical College, Gulbarga after the institutional ethical clearance. Specimens were collected from the Basaveshwar Teaching & General Hospital, Government General Hospital and other hospitals and private laboratories in and around Gulbarga and also from Peripheral Cancer Centre.

The study included cases from 3 years retrospective study (August 2003 to August 2006) and 2 years prospective study (September 2006 to August 2008). About 50 cases common of salivary gland lesions and 50 individuals with normal salivary gland were used in the study.

Histopathological diagnosis of the common salivary gland lesions made from the histopathological features was included in the study. Patients with malignant neoplasms, Skin and adnexal tumors, Soft tissue tumors, Metastatic tumors were excluded from the study.

### **Processing and Staining**

The tissues for the histopathological study were fixed in 10% buffered formalin, processed in different strengths of alcohol, cleared in xylene and were embedded in paraffin wax. The sections were cut at 4-5 microns thickness and staining was done with H&E as routinely and also with 1% aqueous toluidine blue for mast cells. The one stained with H&E was observed for the confirmation of the lesion. Other sections stained with 1% toluidine blue were used to study mast cells. The study comprised of common salivary gland lesions, which included: Chronic non-specific sialadenitis, benign tumors like Pleomorphic adenoma, Basal cell adenoma, Warthin's tumor, Oncocytoma.

Mast cell alteration in different lesions of salivary gland was compared without emphasizing on their variants or grades of neoplasm. Mast cells in the control salivary gland specimens were counted and compared with mast cells in various groups. Control samples were chosen from normal salivary gland tissues from cadavers of anatomy department.

Diagnostic Histomorphological Criteria [6] included chronic non specific Sialadenitis, pleomorphic adenoma, Warthin's Tumor (Papillary Cystadenoma), Oncocytoma, basal cell adenoma etc.

### **Processing and Staining Techniques**

**Mast cell staining and counting:** To identify the mast cells with typical metachromatic granules, special stain 1% aqueous toluidine blue (at pH= 4) was used.

Toluidine blue staining method [7]:

1. Preparation of staining solution: One gm of toluidine blue powder is dissolved in 100 ml of distilled water and the pH is adjusted to 4. The solution is filtered before use.
2. Staining procedure:
  - a) The sections were taken on albuminized slides and kept at 60° for half an hour.
  - b) The slides were kept in xylene for deparaffinization for 15 minutes.

Then, the slides were brought to water in descending grades of alcohol i.e., 100%, 90%, 70%, 50% alcohol and then water wash. The slides were then placed in 1% toluidine blue solution (pH=4) for 1 minute. Then, the slides were rinsed in water, dehydrated in absolute alcohol, cleared in xylene and mounted in DPX. Mast Cell Granules stains purple and Background tissue stains blue.

**Mast Cell Counting and Observations:**

Toluidine blue stained sections were examined under high power magnification. The number of mast cells present in ten consecutive high power fields was counted in all the sections. Findings were tabulated and were statistically evaluated.

On the basis of observations, an attempt was made to study mast cell profile in the common lesions of salivary gland. A possible explanation for the significant mast cell alteration if any was attempted.

**Statistical Analysis:** The data's were analyzed for the statistical significance using students 't' test. P< 0.05 was the level of significance.

**RESULTS**

In the present study, an attempt was made to study the distribution of mast cells in some common salivary gland lesions. The study included about 50 cases of each commonly encountered salivary gland lesions and 50 individuals with normal salivary gland were used in the study.

**Table-1: Distribution of mast cells in chronic non-specific sialadenitis, Pleomorphic adenoma, Basal cell adenoma, Warthin's tumor, Oncocytoma and their comparison with control group. Values are expressed as Mean±S.D. n=50 in each group.**

Cases	Mast cells per 10 HPF	P value
Control group	3.8±0.12	-----
Chronic non-specific sialadenitis	19.3±1.02	p<0.001
Pleomorphic adenoma	16.9±1.30	p<0.001
Basal cell adenoma	9.67±0.17	p<0.001
Warthin tumor	13.0±1.43	p<0.001
Oncocytoma	10.83±1.12	p<0.001

P value is less than 0.001 in all the groups as compared to control group.

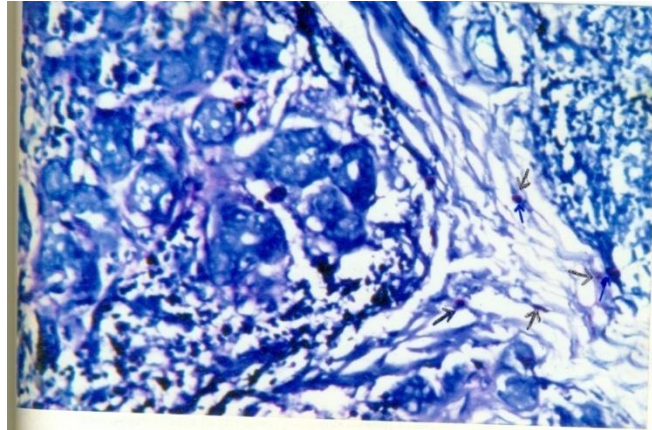
Histologically, under H&E staining, classical histological features were observed in each group. In the present study, toluidine blue staining for the demonstration of mast cell was used as it is simple, easy, and reliable method to exhibit metachromatic granules. However, histochemical demonstration of chloroacetate esterase activity in mast cell has been considered as superior method for mast cell identification.

**Mast cell distribution in normal salivary gland**

On toluidine blue staining, the mast cell distribution in normal salivary gland ranged between 2-8 mast cells/ 10 HPF with a mean of 3.8 mast cells.

**Mast cell distribution in chronic non-specific sialadenitis**

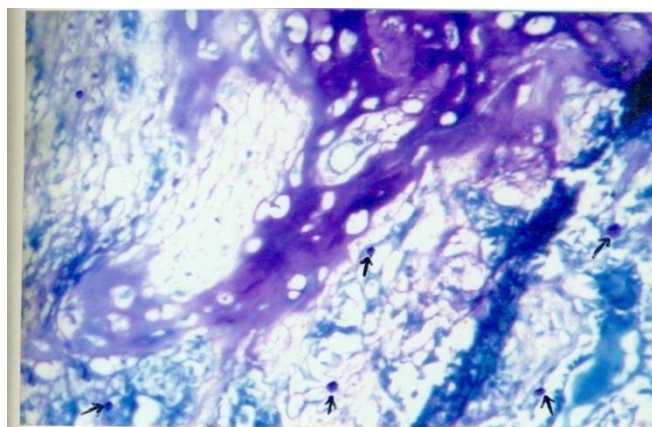
H&E section from chronic non-specific sialadenitis cases revealed increased lymphoid aggregation in the interstitium, at places loss of secretory tissues and extensive areas of fibrosis. On toluidine blue staining, the mast cell distribution were more in the fibrotic areas.



**Figure-1: Microphotograph showing chronic nonspecific sialadenitis: Loose myxoid tissue and epithelial cells (Toluidine blue, 400x).**

#### **Mast cell distribution in Pleomorphic Adenoma**

H&E stained sections from pleomorphic adenoma revealed epithelial elements resembling ductal cells and myoepithelial cells dispersed within a background of loose myxoid tissue containing islands of chondroid tissue. On toluidine blue staining mast cells were chiefly distributed in the connective tissue stroma and also focal connective tissues metachromasia was noted.



**Figure-2: Microphotograph showing pleomorphic adenoma: Loose myxoid tissue and epithelial cells (Toluidine blue, 400x).**



### Mast cell distribution in Basal Cell Adenoma

H&E stained section from the cases of basal cell adenoma revealed small round basaloid cells, uniform, basophilic nucleus and scant cytoplasm. Some ductal structures lined by cells with a greater amount of eosinophilic cytoplasm seen amidst the basaloid cells. On toluidine blue staining, mast cells were chiefly distributed in capsular connective tissue. It is to be noted that the connective tissue stroma is very scant in basal cell adenoma.

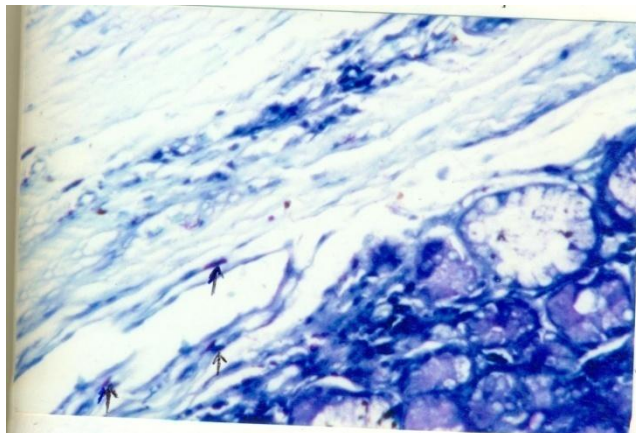


Figure-3: Microphotograph showing basal cell adenoma: Small round uniform cells and scant eosinophilic cytoplasm (Toluidine blue, 400X)

### Mast cell distribution in Warthin's Tumor (Papillary Cystadenoma)

H&E stained sections from the cases of warthin tumor revealed irregular cystic structures with the lining epithelium consisting of 2 layers of luminal layer of oncocytic columnar cells supported by a layer of oncocytic cells. The distinct layer of basement membrane separating the cyst lining from lymphoid stroma and consists of small lymphocytes and some plasma cells, histiocytes and mast cells. On toluidine blue staining, Mast cells were seen in the lymphoid stroma and also around the periacinar region.

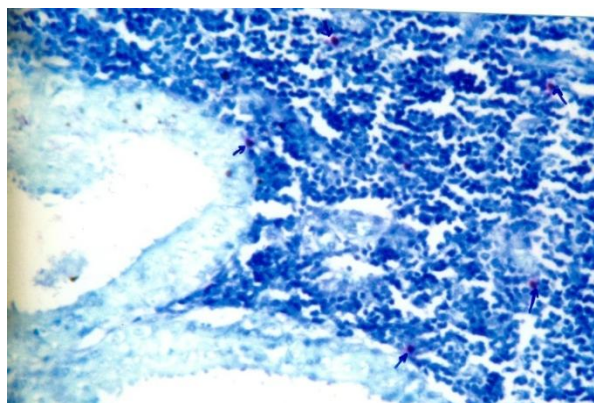
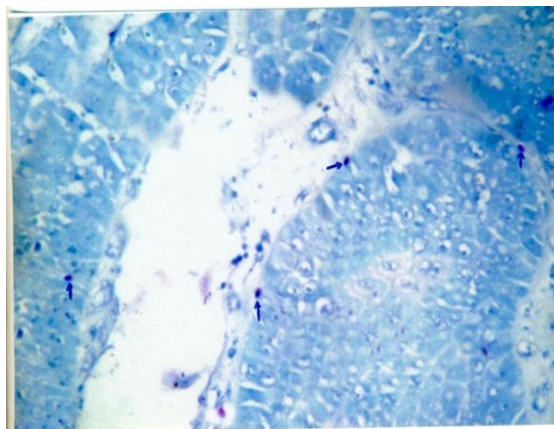


Figure-4: Microphotograph showing Warthin's tumor: Double layered epithelial cells resting on lymphoid aggregates (Toluidine blue, 400x).

### **Mast cell distribution in Oncocytoma:**

H&E stained section from oncocytoma cases revealed tumor cells arranged in diffuse sheets. Oncocytes are large polygonal to cuboidal with abundant eosinophilic granular cytoplasm, central round nuclei and with distinct nucleoli. On toluidine blue staining, mast cells were distributed mainly in the stroma.



**Figure-5: Microphotograph showing oncocytoma: Oncocytes in sheets large polygonal cells with abundant eosinophilic granular cytoplasm (Toluidine blue 400x).**

### **DISCUSSION**

Mast cells are highly engineered cells with multiple critical biological functions. When activated by IgE dependent or IgE independent mechanisms, mast cells produce and release a diverse array of mediators, which include histamine, heparin, protease, lipid mediators, prostaglandins, leukotrienes, and cytokines and play important role in health and disease states of human beings. Mast cells play a vital role in various inflammatory and immunopathologic reactions. Mast cells contain high affinity immunoglobulin E receptors and express the stem cell factor (SCF) receptor and CD 117 (C-kit). Stem cell factor and interleukin 6 (IL-6) in combination appear to be the major growth and differentiation factors for human mast cell. SCF also stimulates directional mast cell motility and its activity is potentiated by addition of IL-3<sup>8</sup>. Mast cells phagocytes, process antigen, produce cytokines and release vasoactive substances. They exhibit an array of adhesion molecules, immune response receptors and other surface molecules that empower the mast cells with an advanced capability to react to multiple non-specific and specific stimuli. Mast cells activation causes the release of preformed granules associated mediators; also there is denovo synthesis of lipid derived substances. Of particular importance are the cyclo-oxygenase metabolites of arachidonic acid and hence these products possess potent inflammatory activity. The association of mast cells with the tumors of man has been documented as early as 1879. Research literatures are available regarding the presence of mast cell alterations in various tumors of man and in various benign versus malignant neoplasms. Mast cell distribution has been shown to be altered in various fibro proliferative disorders like pterygium, wound healing and rhinoscleroma. Prominent increase in mast cells was observed in lesions of breast, like

mammary dysplasia, fibroadenoma and scirrhoucarcinoma of breast. The present study of mast cell profile in some common salivary gland lesions is a preliminary effort to probe into the mast cell distribution in some inflammatory lesions and benign tumors of salivary gland. Although the number of cases in the present study is not very large, it appears to be adequate to draw certain logical conclusions.

In the present study, the mast cell count in normal salivary gland (control group) ranged from 2-8 mast cells/ 10 HPF with a mean of 3.8 mast cells. In cases of chronic non-specific sialadenitis mast cell count ranged from 16-22 mast cells/ 10 HPF with a mean of 19.3 mast cells. The mast cells were significantly increased ( $p < 0.001$ ) when compared with that of control group. Mast cells were more in fibrotic areas. The present study is similar to that of Diao GX et.al, [9] who did a quantitative analysis of mast cells in chronic sialadenitis and showed that mast cells were increased in chronic sialadenitis. Immunohistochemical study done by Epivanos et.al, [10] documented that there was increase in mast cells in chronic sialadenitis particularly in glands with widespread fibrosis. There was a significant ( $p < 0.05$ ) increase in number of mast cells in chronic non-specific sialadenitis on comparison with pleomorphic adenoma. There was a statistically significant ( $p < 0.001$ ) difference with increase in mast cells in chronic non-specific sialadenitis on comparison with basal cell adenoma and oncocytoma. The possible explanation regarding increased number of mast cells in these cases of chronic non-specific sialadenitis might be an array of mediators secreted by mast cells that could stimulate fibroblast proliferation through the ability of these mediators to induce the secondary production of autocrine growth factors (e.g., platelet derived growth factors) by fibroblasts or through the mediators that overtly induce fibroblast cell cycling.

Mast cells exhibit a complex bidirectional relationship with fibroblast [11]. Fibroblasts represent a source of both membranes bound and soluble forms of C-kit ligand, stem cell factors and either form of stem cell factor can promote mast cell development. Mast cell can have direct effect on fibroblast responses.

There was statistically significant ( $p < 0.001$ ) difference with increase in mast cell number in pleomorphic adenoma on comparison with basal cell adenoma and oncocytoma. Katapodi and Kavantzus M [12] have shown that connective tissue stroma in Pleomorphic adenomas definitely influences the actual concentration of mast cells. Pleomorphic adenomas expressed TGF- $\beta_2$ , which may be associated with differentiation of inner ductal cells.

Bruni and Olivi et.al, [13] showed diffuse connective tissue metachromasia presumably owing to degranulation of mast cells.

Holmgren [14] studies indicated that metachromatic ground substance in connective tissue was particularly prominent at places where growth of the adjacent epithelial structures was more intense. In the stroma of tumors and regenerating epithelium there was diffuse metachromasia throughout the ground substance of connective tissue. This has been assumed to depend upon the presence of heparin, derived from mast cells. Also diffuse metachromatic staining is especially widest in various types of rapidly growing tissues. Paff et.al, [15] showed



that the antimitotic effect of heparin is attributed to interference by heparin with the metabolism of nucleoproteins and this process may have a prognostic significance in tumor exhibiting connective tissue metachromasia.

### CONCLUSION

The present study of mast cell profile in some common salivary gland lesions included a total of 50 cases each with chronic non-specific sialadenitis, Pleomorphic adenoma, basal cell adenoma, Warthin's tumor and oncocytoma. The present study of mast cell spectrum in some common salivary gland lesions highlights that Mast cell numerical changes do occur in the lesions of salivary gland. A significant increase of mast cells was noted in chronic non-specific sialadenitis, Pleomorphic adenoma, basal cell adenoma, Warthin's, and oncocytoma as compared with the control group. Hence, Mast cell profile may be considered as an additional differential diagnostic /supportive parameter in the categorization of these lesions. This study may stimulate and encourage further research in mast cell profile in commonly encountered inflammatory and benign lesions of salivary gland and may offer new vistas in therapeutic approaches in salivary gland lesions.

### REFERENCES

1. Metcalfe Dean D, Dana Basam and Joseph A Mekol. *Physiol Rev* 1997; 1033-1079.
2. Crivellato E, Beltrami CA et al. *Histol Histopathol* 2004; 19(1): 259-70.
3. Sorter NA and Austen KF. *Mast cells in Dermatology in General Medicine*. 3<sup>rd</sup> Ed., Fitzpatrick TB, Eisen AZ, Wolff K, Freedberg IM, Austen KF (eds.) McGraw Hill Book Co., New York. 426-243.
4. Rimmer EF and Horton MA. *Clin Exp Immunol* 1987; 68: 712-718.
5. Prussin, Calman, Metcalffe Dean D. *J Allergy & Clinical Immunology*. 2003; 11 (2 part-3): 5486-5454.
6. Fletcher Christopher DM. *Diagnostic histopathology of humans*. 3<sup>rd</sup>Edn., Vol. 1, Churchill Livingstone, Harcourt Publishers: 2000.
7. Claydon EE. *Toluidine blue staining method – Practical section cutting and staining*. 4<sup>th</sup>edn., London, Churchill TA, UK. 1962; 105.
8. Meininger CJ, Yano H, Rottapel R et al. *Blood* 1992; 79(4): 958-963.
9. DiaoGx. *Zhonghua Kou.Quang Yi, XauZaZhi* 1993; 28(2): 93-4.
10. Epivatianos A, Tzaraboukas, A Pouloupoulon, Harrison J. *Oral Diseases* 2008; 14(3): 259-263.
11. Choi KL, Claman HN. *Immunol Res* 1987; 6(3): 145-52.
12. Katopodi AI, Kavantzias AI, Paulopoulos AI et al. *J Pathology* 2004; 36(3): 256-61.
13. Bruni and Olivi M. *Ist Unit Perugia*. 1951; 10: 73. (quoted from: *The Mast Cells*, Seyle H. Washington DC. Butterworths. USA: 1965).
14. Homgren H. *Anat Anzg*. 1939; 88: 246.
15. Paff, Sugiura HT, Boucher CA and Roth JS. *Anat Rec*. 1952; 114: 499 (quoted from: *The Mast Cells*, Seyle H. Washington DC. Butterworths. USA: 1965).