

Research Journal of Pharmaceutical, Biological and Chemical Sciences

Management of a Fungal Perinephric Abscess (PNA): Dilemma Revisited

Pandey PK*, Shukla S, Bera MK, Kundu AK, Das S

Department Of Urology, IPGME&R, Kolkata-700020, India.

ABSTRACT

Candida species can cause a wide variety of clinical syndromes, especially in immunocompromised and diabetic patients. Primary perirenal candidial abscess has been a rare reported entity. Here we report a rare case of primary PNA due to Candida species in an immunocompetent patient with diabetes mellitus and its minimal invasive management. Retrospective and prospective analysis of clinical, laboratory and radiological records along with continued follow up of patient was done. This patient was 48-year-old man, admitted with burning in micturition, right flank discomfort and low grade fever since 1 year. Abdominal ultrasound and computerized tomography were suggestive of a PNA of the right kidney. Candida species was isolated from sample obtained by C.T. guided needle aspiration. Culture of aspirate showed sensitivity to azoles. Systemic antifungal therapy based on culture report was started in form of oral drug. The patient responded well leading to resolution of lump and the fever. Appropriate timely treatment appears to be having a promising role in definitive therapy for renal and PNA due to Candida even in immunocompetent host with predisposing factors such as diabetes mellitus. This case highlights the fact that fungal infections should be included in the differential diagnosis of PNA in such patients.

Key words: Peri-nephric abscess, *Candida* spp, voriconazole

***Corresponding author**

Email: drpandeypraveen@gmail.com

October – December 2011

RJPBCS

Volume 2 Issue 4

Page No. 62

INTRODUCTION

Candida is one of the most frequent etiologic agents in fungal infections. It causes opportunistic infections ranging from simple mucocutaneous to invasive infections in patients with immunosuppression. Infections of the skin and the mucous membranes due to *Candida* species may occur either in immunocompromised or normal population. This is in contrast to systemic candidiasis (e.g. candidemia) which is only seen in severely immunocompromised patients. Blood stream infections caused by *Candida* species are increasingly recognized in critical ill adult and pediatric individuals, with significant associated morbidity and mortality. Renal and perirenal abscess by *Candida* is an infrequent entity. Diseases such as diabetes mellitus, renal failure, organ transplantation, and neutropenia are the main predisposing factors for *Candida* infections. Treatment of infections caused by this species should be with antifungal agents such as amphotericin B, azoles, or echinocandin.

CASE REPORT

A 48 year-old male weighing 62 kilograms presented with complaints of burning in micturition and low grade fever (off and on) since 1 year along with right flank pain since 3 months. A tender ballotable lump was palpable on right side of abdomen. Total leukocyte count was 9100/cu mm and serum creatinine was 3.62 mg/dL. During evaluation, glycemic status of the patient was found to be deranged. USG abdomen was suggestive of a small abscess cavity in posterior aspect of right kidney with a thin rim of collection around lower pole. The other kidney was found to be small and contracted. CT abdomen (Fig.1) was suggestive of a localized collection in medial aspect of right kidney with extension in perinephric space superiorly & laterally.

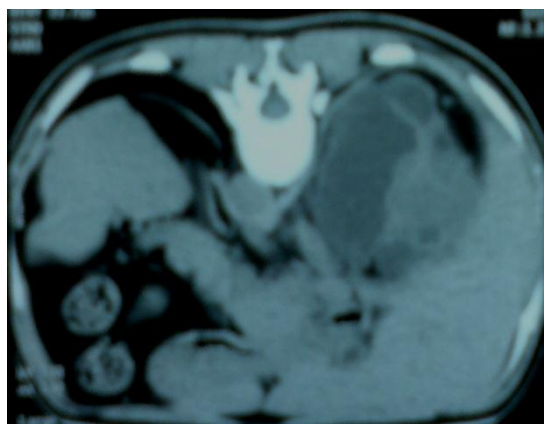

Fig 1: CT- Abdomen showing left perinephric abscess

CT guided fine needle aspirate microscopy revealed plenty of budding yeast cells with numerous pseudohyphae along with plenty of pus cells suggestive of Candidiasis (Fig 2). Fungal culture confirmed growth of *Candida* species sensitive to azoles. Viral markers were negative.

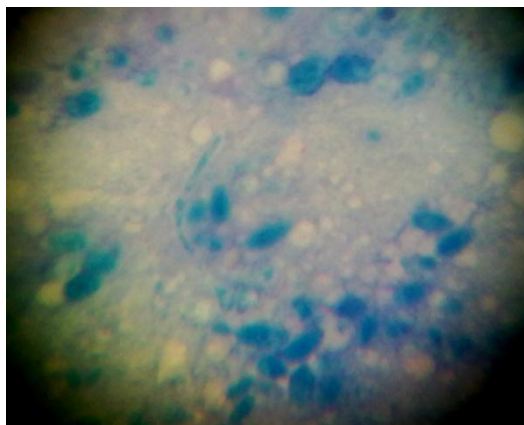


Fig 2: Peri renal aspirate microscopy revealed plenty of budding yeast cell with psuedohyphae

Patient was started on oral voriconazole with loading dose of 400 mg twice on day 1, followed by 200 mg twice daily for 2 weeks with strict glycemic control. Fever along with flank pain subsided. CT scan one month later revealed complete resolution of abscess. At the time of writing this case report, more than 6 months later, the patient is in complete remission with no clinical evidence of perinephric collection.

DISCUSSION

Renal cortical abscess are three times more common in male over females, whereas suppurative infections of the kidney and perinephric space affect both sexes equally. These infections may cause significant morbidity and mortality [1, 2].

Most prominent risk factors associated with fungal renal abscess are diabetes mellitus, use of long term broad spectrum antibiotics, immunosuppression and urinary tract obstruction [3-5]. Systemic candidial infection may also lead to renal involvement but the symptomatology in these patients may itself be quite suggestive of the etiology.

Though fungal PNA in itself is a rare entity, the route of infection is the same as that of the bacterial etiology [6].

Usually in bacterial etiology ascending urinary tract infection is a major source of PNA [7] although a significant number of cases (30%) may be due to hematogenous dissemination from distant sites of infection. Ascending infections are usually caused by gram-negative organisms whereas hematogenous bacterial seeding is commonly associated with gram-positive organisms such as *S. aureus* [7].

With development of advanced diagnostic modalities, highly effective antibiotics and newer nonsurgical interventions, the rate of recovery from renal and perirenal abscesses without surgery has increased, and reduced mortality has been described [8-11]. However

percutaneous drainage in particular may lead to pyopneumothorax, bacteremia, phlegmon and gastrointestinal tract fistulas [12, 13].

The management of PNA is still a controversy depending upon the etiology, predisposing factors and radiologic findings. The treatment may further be confounded by a fungal etiology.

Our patient had one predisposing factor for fungal infection as he was diagnosed to be diabetic. The patient was immunocompetent and had never undergone treatment for any surgical or major medical illness. As the renal parameters of the patient were already deranged, an advocated and conservative approach of percutaneous drainage along with systemic antifungal treatment, [14-16] was followed. There were no findings suggestive of re-infection or superimposed infection on follow up.

REFERENCES

- [1] Dembry LM. Infectious Diseases 2002; 4: 21-30.
- [2] Meng MV, Mario LA, Mc Ainch JW. J Urol 2002; 168: 1337-40
- [3] Prakash C, Chugh TD, GUPTA SP. et al. J Assoc Physicians India 1970;18:497-502
- [4] Miraglia GJ, Renz KJ. Antimicrob Agents Chemother 1973;3:474-7
- [5] Dreetz DJ, Fetchick R. Fungal infections of the kidney and urinary tract. In: Schrier RW. Gottschalk CW. Eds. Diseases of the kidney. Boston; Little Brown 1988.1015-47
- [6] High KP, Quagliarello VJ. Clin Infect Dis. 1992; 15(1):128-33.
- [7] Rinder MR. Md Med J 1996: 45: 839-43
- [8] Hoverman IV, Gentry LO, Jones DW, Guerriero WG. Intrarenal abscess: report of 14 cases. Arch Intern Med 1980; 140:914–916.
- [9] Finn DJ, Palestrant AM, Dewolf WC. J Urol 1982;127:425–426
- [10] Lyons RW, Long JM, Lytton B, Andriole VT. J Urol 1972; 107:524–526.
- [11] Wright FW. Br J Urol 1977; 49:22.
- [12] Lang EK, Springer RM, Glorioso LW III, Cammarata CA. Radiology 1986; 159:329-36.
- [13] VanSonnenberg E, Mueller PR, Ferrucci JT Jr. Radiology 1984;151:337-41,343-7
- [14] Elyaderani MK, Moneman J. South Med J 1985;78;685-9
- [15] Lang EK. Radiology 1990; 174:109-113.
- [16] Sacks D, Banner MP, Meranze SG, Burke DR, Robinson M, McLean GK. Radiology 1988;167;447-51