

Research Journal of Pharmaceutical, Biological and Chemical Sciences

Evaluation of Hepatoprotective Activity of Combination of *Phyllanthus Niruri* and *Curcuma Longa* Extracts in Wistar Rats

Adiga S, Vinay BS*, Shobha Kamath, Bhaskar Gaonkar, Amit Panda, Mohandas Rao KG, K L
Bairy.

Department of Pharmacology, Kasturba Medical College, Manipal, Karnataka, India
Department of biochemistry, Kasturba Medical College, Manipal, Karnataka, India
Department of Anatomy, Melaka Manipal Medical College, Maniapl, Karnataka, India.

ABSTRACT

Hepatoprotective activity of combination of *Phyllanthus niruri*(PN) and *Curcuma longa*(CL) extract was evaluated against carbon tetrachloride(CCl₄) induced liver damage. Combination of PN+CL extract at a dose of 400mg/kg, orally was coadministered with CCl₄ (0.5 mg/kg i.p) to rats for 7 days. On 8th day serum enzyme levels such as AST, ALT, ALP, TB were determined. Thiopentone induced sleeping time is estimated as an indirect index of functionality of liver. Liver tissue was used to estimate antioxidants such as MDA, GST levels and for histopathological assessment. There was a significant increase in serum enzyme levels and duration of thiopentone induced sleep time in CCl₄ treated rats. Coadministration of PN+CL extract combination with CCl₄ significantly prevented the rise in serum enzyme levels and normalize the duration of thiopentone induced sleep time. Combination of PN +CL produced significant reduction and increase in MDA & GST liver levels respectively. Histological section of liver in animals treated with CCl₄ showed centrilobular area of necrosis with derangement in hepatic architecture. PN+CL administration prevented these deleterious changes, histological section of liver in rats treated with PN+CL showed normal hepatic parenchyma. Combination of PN+CL extract showed significant hepatoprotection against CCl₄ induced liver damage.

Keywords: Hepatoprotective, *Phyllanthus niruri* , *Curcuma longa*, carbontetrachloride.

*Corresponding author



INTRODUCTION

Liver diseases are mainly caused by toxic chemicals, excess of alcohol consumption, infections and autoimmune disorders. Hepatic diseases stand as one of the foremost health problem worldwide, with liver cirrhosis and drug induced liver injury accounting for 9th leading cause of death in developing countries [1]. Liver damage caused by drugs and toxins may mimic all forms of acute and chronic liver diseases. The pathogenesis of drug or toxin-induced liver injury usually involves the participation of toxic metabolites that either elicit an immune response or directly affect the biochemistry of the cell [2]. Carbon tetrachloride continues to be one of the most commonly used toxins in the experimental studies of liver diseases. The toxicity of CCl_4 has been attributed to one of several possible mechanisms, viz., covalent metabolite binding, lipid peroxidation, reactive aldehydes, nucleic acid hypomethylation, loss of calcium homeostasis, or inflammatory cytokines, consensus has emerged that CCl_4 toxicity is a multifactorial process to which any of the above quoted mechanisms contribute [3].

In spite of tremendous advances made in allopathic medicine, there are very few synthetic drugs available to treat liver disorders. These drugs are non specific and are often limited in efficacy to treat liver disorders. In addition these drugs have their own serious adverse effects too. So there is a need to follow systematic research methodology and to evaluate the scientific basis for herbal drugs used in liver disorders and also to develop new formula that works on scientific basis, hence a combination of different herbs or active constituents claimed to possess hepatoprotective activity may give better results.

Phyllanthus niruri (family Euphorbiaceae) is a plant possessing several pharmacological properties. This herb is used since ancient times for the treatment of jaundice and other liver related disorder. It is shown to possess hepatoprotective actions against alcohol [4], carbon tetrachloride [5] and thioacetamide [6] induced toxicity.

Curcuma longa, is a perennial herb and member of the Zingiberaceae (ginger) family. Studies done earlier have demonstrated its hepatoprotective activity against carbon tetrachloride [7], acetaminophen (paracetamol) [8] and aspergillus aflatoxin [9].

To our knowledge, no study has so far reported the hepatoprotective activity using combination of phytoconstituents of *Phyllanthus niruri*(PN) & *Curcuma longa*(CL) extract, hence this study was undertaken and its effects compared with Liv.52.

MATERIALS AND METHODS

Preparation of combination of *Phyllanthus niruri* and *curcuma longa* extract

Dry extract of combination of *Phyllanthus niruri* and *Curcuma longa* was gifted by Arjuna Natural Extracts Limited, Kerala. The Extract mixture contained *Phyllanthus niruri* and *Curcuma longa* in 1:1 ratio. This mixture contained the active phytoconstituents namely phyllanthin,

hypophyllanthin, flavanoids of *Phyllanthus niruri* and Curcumin, Demethoxy curcumin, Bisdemethoxy curcumin and essential oils of *Curcuma longa*. Dimethyl sulfoxide(DMSO) was used as solvent.

Animals

Male Adult albino rats of Wistar strain weighing 150-200 g were used for the study. They were maintained in clean polypropylene cages under standard environmental conditions. The animals were provided with standard rat feed and water ad libitum. The study was approved by Institutional Animal Ethics Committee, KMC No.IAEC/KMC/78/2010-2011.

Materials

Kits for estimation of AST, ALT, ALP and TB were purchased from Agappe Diagnostics Limited, Ernakulam, Kerala. CCl_4 obtained from Ranbaxy fine Chemicals limited, New Delhi. DMSO was obtained from Merck (India) Limited, Mumbai. Buffers and other reagents used were of analytical grade.

EXPERIMENTAL PROCEDURE

Animals were randomly divided into 4 groups. Each group consisted of 6 animals .Group 1(control) received DMSO 3ml/day, orally. Group II, III, IV received CCl_4 (0.5 ml/kg i.p) [10]. Group III & IV was treated with *PN+CL*(400mg/kg , orally) [11,12] and *Liv.52*(100mg/kg, orally) [13] respectively along with CCl_4 . All animals were treated for 7 days. At the end of treatment i.e on 8th day, animals in all groups were given thiopentone sodium (40mg/kg, i.p) [14] and time taken for onset of sleep and total duration of sleep were recorded. Once animals recovered from thiopentone induced sleep, blood was obtained from the rats through the orbital vessels using capillary tubes to estimate serum enzyme levels. Then the animals were sacrificed with ether anaesthesia and liver was dissected out. Liver samples were used for histopathological studies and liver homogenates were prepared for biochemical estimation.

Parameter assess for the hepatic functions

Serum enzyme assays

Blood samples were withdrawn, by retro-orbital route from all the animals. The samples were centrifuged at 3000 rpm for 10 minutes in a centrifuge. The serum obtained was used for the estimation of aspartate aminotransferase (AST), alanine aminotransferase (ALT), alkaline phosphatase (ALP), and total bilirubin (TB).

Liver antioxidants assay

Animals were sacrificed under ether anesthesia on the day of blood withdrawal. Liver was removed and washed with saline. The liver tissue was stored in 10% formalin solution, later liver was homogenized (1:20w/v) in potassium phosphate buffer (0.1molar, pH 7.4, containing 0.25M sucrose). The homogenate was centrifuged at 1500 rpm for 10 minutes in the high speed refrigerated centrifuge and the supernatant is used for assay of Glutathione-S-Transferase (GST) and Malondialdehyde (MDA).

Thiopentone induced sleeping time

On the day of blood withdrawal, before collecting the blood all animals were given thiopentone sodium (40mg/kg) intraperitoneally. Time taken for onset of sleep and duration of sleep were recorded.

Histopathological studies

The paraffin sections were prepared using liver tissue and cut into 5 μ thick sections. The sections were then stained with hematoxylin and eosin (H&E) dye and studied using light microscope for histopathological changes and photographs were taken.

Statistical analysis

The results were analysed using one-way analysis of variance (ANOVA) followed by post hoc analysis done using Tukey method. p value < 0.05 was considered as statistically significant. The analysis was carried out using SPSS version 14 for windows.

RESULTS

Serum enzyme levels

There was a significant ($p < 0.05$) increase in serum enzymes-ALT, AST, ALP and TB levels in CCl₄ treated rats compared to control animals. Coadministration of PN+CL extracts combination with CCl₄ significantly ($P < 0.05$) prevented the rise in ALT, AST, ALP & TB levels. The effect of combination of PN+CL on serum enzymes was comparable to Liv.52. (Table No. 1)

Liver antioxidants assay:

To probe into the mechanism of action of PN+CL extract, GST and MDA estimation was done. Administration of CCl₄ in rats significantly ($p < 0.05$) reduced GST and increased MDA levels in liver when compared to normal control rats indicating reduction in enzyme antioxidant levels and increase in the process of lipid peroxidation respectively. This was significantly prevented by combination of PN+CL. (Fig1 & Fig 2)

Thiopentone induced sleeping time

There was a significant ($p < 0.05$) decrease in the time taken for onset of sleep and also significant ($p < 0.05$) increase in the total duration of sleep in CCl_4 treated group when compared to normal control group of rats. Coadministration of *PN+CL* extracts along with CCl_4 significantly prevented the alterations in the sleep. This effect was comparable to Liv.52. (Table No. 1)

Table 1: Effect of combination of *PN+CL* extracts on serum enzyme levels

Groups	ALT(U/L)	AST(U/L)	ALP(U/L)	TB(mg/dl)
Group I	7.2717±0.35	16.9050 ±0.93	62.5667±0.62	1.0967±0.13
Group II	28.0133±1.14 ^a	58.8667±2.33 ^a	77.9950±1.85 ^a	2.0807±0.08 ^a
Group II	12.5750±0.93 ^{ab}	29.3717±1.81 ^{ab}	60.6267±1.37 ^b	1.1820±0.07 ^b
Group IV	7.26±0.44 ^b	28.40±1.28 ^{ab}	59.89±1.60 ^b	1.16±0.11 ^b

Values expressed as Mean±SEM (n=6). a= $p < 0.05$ vs group I ,b= $p < 0.05$ vs group II. ANOVA followed by Tukey post hoc test.

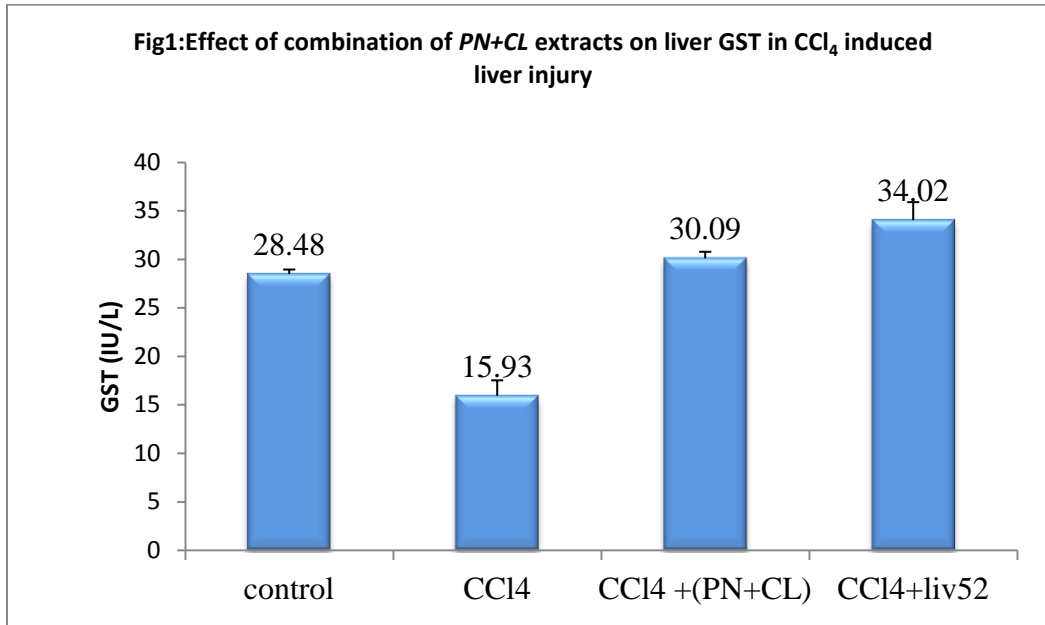
Table 2: Effect of combination of *PN+CL* extract on thiopentone induced sleeping time

Groups	Onset (in seconds)	Duration (in minutes)
Group I	170.33± 1.52	41.33±1.08
Group II	107.00±1.96 ^a	178.16±3.48 ^a
Group III	157.33±2.0 ^{ab}	70.83±1.86 ^{ab}
Group IV	163±2.22 ^b	59.33±1.54 ^{ab}

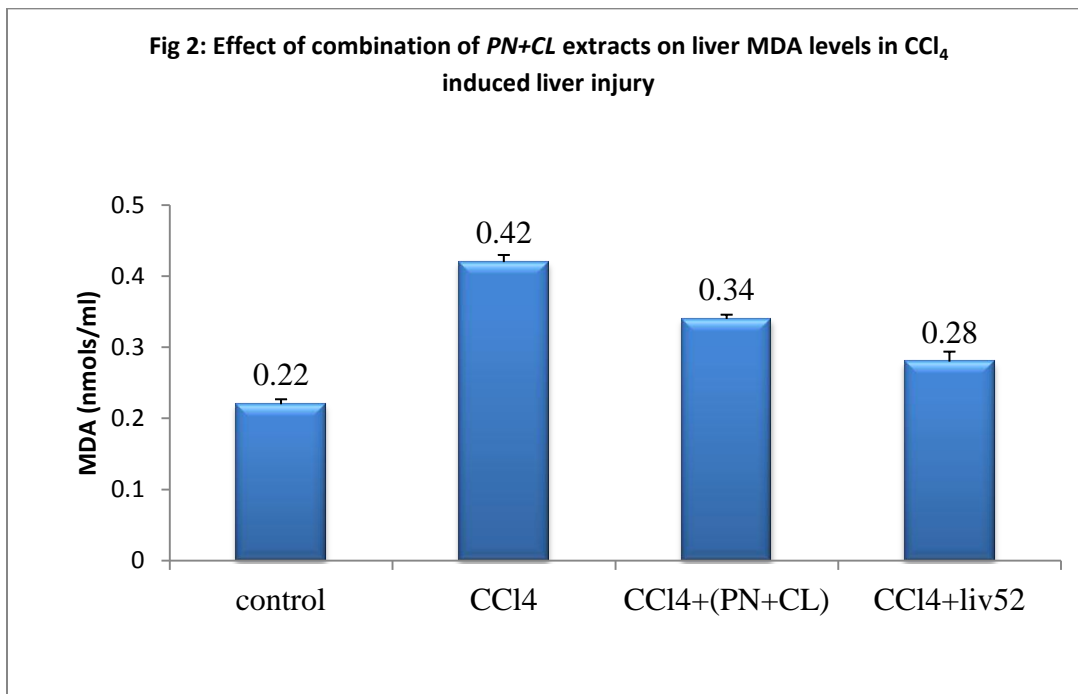
Values expressed as Mean±SEM (n=6). a= $p < 0.05$ vs group I, b= $p < 0.05$ vs group II. ANOVA followed by Tukey post hoc test.

Histopathological studies

Control animals showed normal hepatic architecture (fig 3). Histological section of liver from group II animals (fig4) showed centrilobular area of necrosis with loss of cell borders, lymphocytic infiltration and derangement in hepatic architecture. *PN+CL* treated group III (fig5) & Liv.52 treated group IV(fig6) animals liver section displayed almost normal appearing hepatic parenchyma, with no evidence of any parenchymal injury.



Values expressed as Mean±SEM (n=6), a=p<0.05 vs group I ,b= p<0.05 vs group II



Values expressed as Mean±SEM (n=6), a=p<0.05 vs group I ,b= p<0.05 vs group II

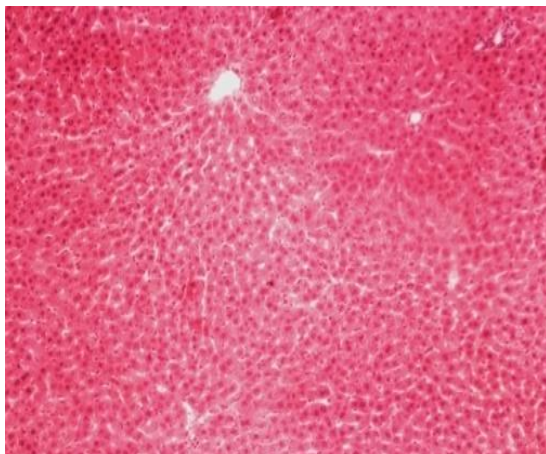
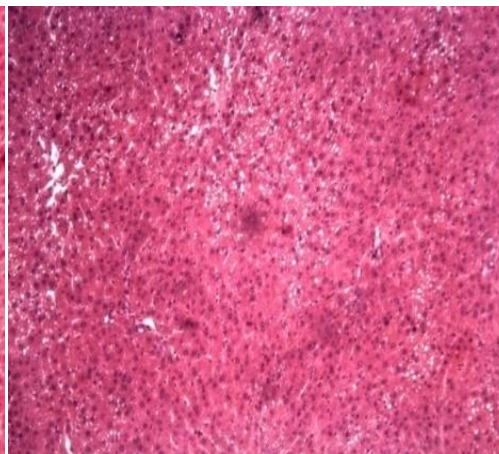
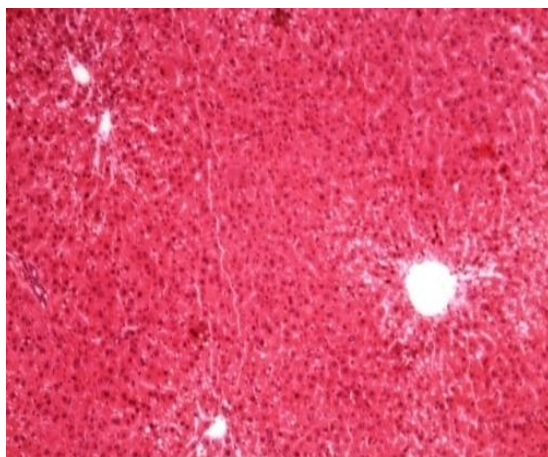
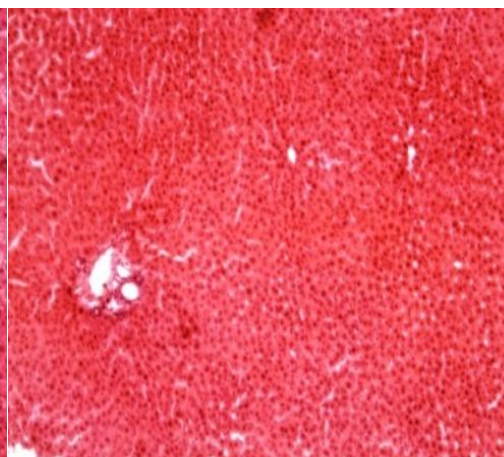


Fig3: Group 1(control)


 Fig4: Group 2(CCl₄)

 Fig5: Coadministration of CCl₄+(PN+CL)

 Fig6: Coadministration of CCl₄+Liv.52

DISCUSSION

In our study, CCl₄ used caused significant increase in serum AST, ALT, ALP & TB levels when compared to control group, which is a clear indication of enzymes leakage due to loss of functional integrity of liver cell membrane. Administration of combination of *PN+CL* at a dose of 400 mg/kg along with CCl₄ significantly prevented the elevation in AST, ALT, ALP and TB levels, showing hepatoprotective activity offered by the extracts combination. Free radicals generated during metabolism of CCl₄ initiates lipid peroxidation in cell membranes. Peroxidation of polyunsaturated fatty acids in cell membrane produces Malondialdehyde(MDA). The production of MDA is used as a marker to measure the level of oxidative damage in tissues. Liver MDA level was assessed as an indicator of lipid peroxidation. In our study, CCl₄ administration significantly increased MDA levels in liver when compared to control group. Coadministration of *PN+CL* with CCl₄ significantly reduced liver MDA levels when compared to solely CCl₄ treated group, which indicates that *PN+CL* has prevented the lipid peroxidation process. This decrease in liver MDA levels may be attributed to the antioxidant activities of both *PN* and *CL*. This observation was similar to findings of previous

studies done individually on *PN* [15] or *CL* [7]. CCl_4 administration significantly reduced the GST levels in liver when compared to control group, facilitating a prooxidative state. *PN+CL* increased the levels of GST in liver indicating an increased antioxidant resource which might contribute to its hepatoprotective activity.

In our study, CCl_4 administration significantly increased the duration of thiopentone induced sleep time compared to normal control group. Derangement in drug metabolizing enzymes in liver caused by CCl_4 can lead to delay in the clearance of thiopentone, resulting in a longer duration of a hypnotic effect. This was supported by earlier studies [16]. Treatment with *PN+CL* significantly decreased duration of thiopentone induced sleep time compared to CCl_4 treated group. This is an indirect evidence of their hepatoprotective activity.

Histopathological findings in liver correlate with biochemical estimations. CCl_4 administered group depicted centrilobular area of necrosis with lymphocytic infiltration further confirming hepatocellular damage. Developments of these deleterious changes were prevented by *PN+CL*. Histopathological studies showed almost normal features with no evidence of any parenchymal injury.

Mechanisms by which active constituents like phyllanthin, hypoohyllanthin of *PN* & curcumin demethoxy curcumin of *CL* show hepatoprotective activity may be different and hence when used in combination they may act synergistically to each other.

In view of its hepatoprotective activity, combination of *PN+CL* may offer vast possibilities in the treatment of various liver disorders. However these suggestions need well designed clinical evaluation.

CONCLUSION

Combination of *PN+CL* extract showed significant hepatoprotection against CCl_4 induced liver damage. Hepatoprotective activity may be attributed to antioxidant principles present in the extract. Combination of *PN+CL* may offer vast possibilities in the treatment of various liver disorders. However these suggestions need well designed clinical evaluation

REFERENCES

- [1] Saleem TSM, Chetty CM, Ramkanth S, Rajan VST, Kumar KM, Gauthaman K. Int J Res Pharm Sci 2010; 1(1): 1-5.
- [2] Kaplowitz N. Clin Infect Dis 2004; 38 suppl 2: S44–48.
- [3] Weber LW, Boll M, Stampfl A. Crit Rev Toxicol 2003; 33(2): 105-136
- [4] Baskaran M, Periyasamy L, Rajagopalan R. Int J Pharm Pharm Sci 2010; 2(4): 58-62.
- [5] Rajesh B, Parames CS. Food Chem Toxicol 2007; 45: 817-826.
- [6] Mrinal KS, Parames CS. Pathophysiol 2007; 14: 113-120.



- [7] Lee HS, Li L, Kim HK, Bilehal D, LI W, Lee DS. J Microbiol Biotechnol 2010; 20(9): 1331-1338.
- [8] Donatus IA, Sardjoko, Vermeulen NP. Biochem Pharmacol 1990; 39: 1869-1875.
- [9] Soni KB, Rajan A, Kuttan R. Cancer Lett 1992; 66: 115-121.
- [10] Shenoy KA, Somayaji SN, Bairy KL. Indian J Pharmacol 2001; 33: 260-266.
- [11] Iqbal MJ, Dewan FZ, Chowdhury AR, Mamun MIR, Moshiuzzaman M, Begum M. Bangladesh J Pharmacol 2007; 2: 43-48.
- [12] Chaudhary GD, Kamboj P, Singh I, Kalia AN. Indian J Nat Prod Resour 2010; 1(4): 397-408
- [13] Singh S, Mehta A, Mehta P. Int J Pharm Pharm Sci 2011; 3 Suppl 2: S146-147
- [14] Parmar MY, Shah P, Thakkar V, Gandhi TR. Int J Green Pharm 2009; 3: 250-254
- [15] Manjrekar AP, Jisha V, Bag PP, Adhikary B, Pai M M, Hegde A, et al. Indian J Exp Biol 2008; 46: 514-520.
- [16] Wakchaure D, Jain D, Singhai AK, Somani R. J Ayurveda Integr Med 2011; 2: 137-143