

# Research Journal of Pharmaceutical, Biological and Chemical Science

## A Case of Unusual Giant Complex Odontoma with Impacted Teeth and Dentigerous Cyst.

Masthan KMK<sup>1\*</sup>, Vidya Rani<sup>1</sup>, Aravindha Babu N<sup>1</sup>, Leena Sankari S<sup>1</sup>, and Senthil Kumar P<sup>2</sup>.

<sup>1</sup>Department of Oral Pathology and Microbiology, Sree Balaji Dental College & Hospital, Chennai, Tamil Nadu, India.

<sup>2</sup>Maxillo Facial Surgeon, Government Medical College, Theni

### ABSTRACT

Odontomas are the most common benign odontogenic tumors of the jaws. They are slow growing and nonaggressive, but sometimes can cause pain, swelling, expansion of bone and interfere with the eruption of the associated tooth. Cases of simultaneous pathologies with odontoma are rare. In this paper a case of unusual giant complex odontoma associated with impacted teeth and dentigerous cyst has been reported.

**Keywords:** Dentigerous cyst, Hamartomas, odontoma, swelling

*\*Corresponding author*

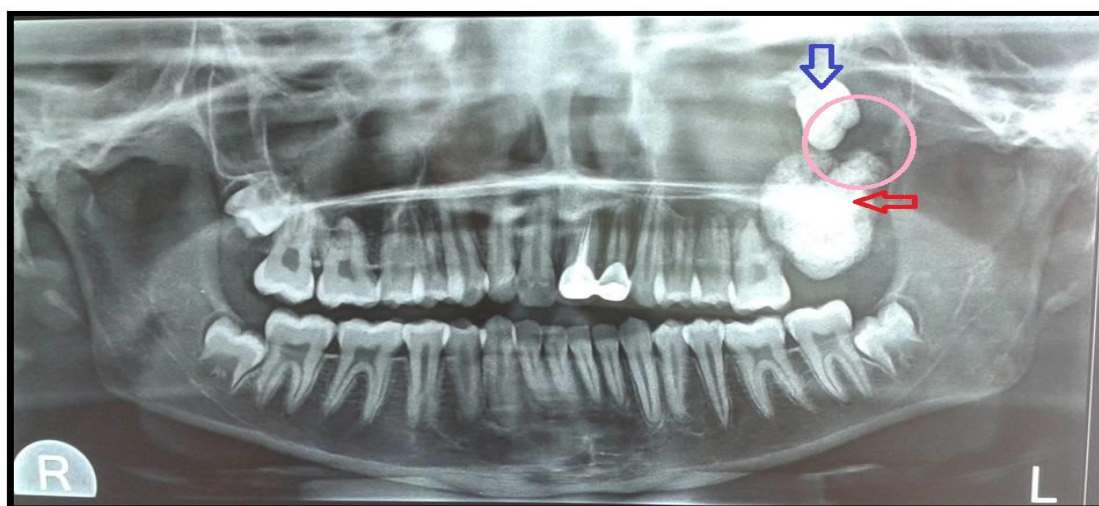## INTRODUCTION

Odontomas are considered as most common odontogenic tumors of jaw [1]. They are slow growing, non aggressive and composed of enamel, dentin, cementum and occasionally pulp tissue. Broca in 1867 first coined the term "Odontoma"[2] Based upon various features odontomas are classified as compound odontoma and complex odontoma. Complex odontomas are less frequent compared to compound odontomas. Most of the odontomas appear as asymptomatic mass with minimal growth potential. Rarely do they exceed the size of a tooth, but when large they can cause expansion of cortical bone, swelling, pain and other related symptoms. Dentigerous cysts are developmental odontogenic cysts that are always associated with an unerupted or developing tooth bud [3]. Here we have presented a case of giant odontome with impacted teeth and dentigerous cyst exhibiting expansion of cortical plate with sinus opening and other related symptoms.

### Case presentation

A 15-year-old male patient was referred to us with a complaint of pain and swelling on left side of upper jaw for past one month. History revealed that the pain was lancinating and used to aggravate during eating. Medical and family histories were non contributory. Clinical examination revealed no gross extra oral facial asymmetry. Intraoral examination revealed a diffuse, bony hard swelling distal to left permanent first molar. Pus draining, sinus tract was present on left maxillary tuberosity area.

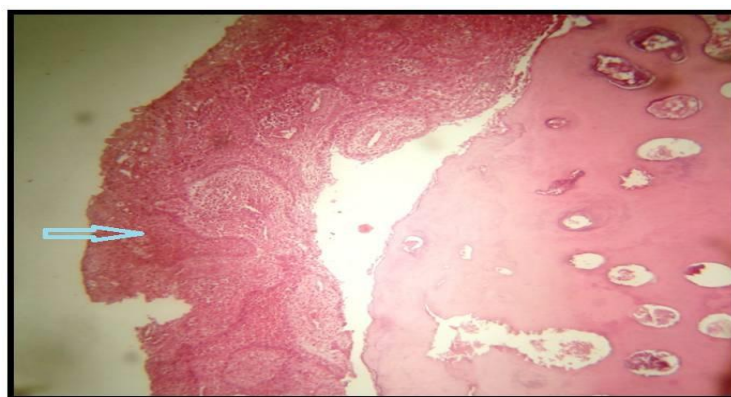
Orthopantomography revealed the presence of a radiopaque mass distal to the maxillary left first molar extending up to maxillary tuberosity region, measuring about 2x4cm. An impacted third molar tooth was noted in inferior border of the orbit. Small radiolucent area was noticed in association with the crown of the impacted teeth and apical area of the radiopaque mass. On the basis of clinical and radiological findings, a provisional diagnosis of complex odontoma was established.



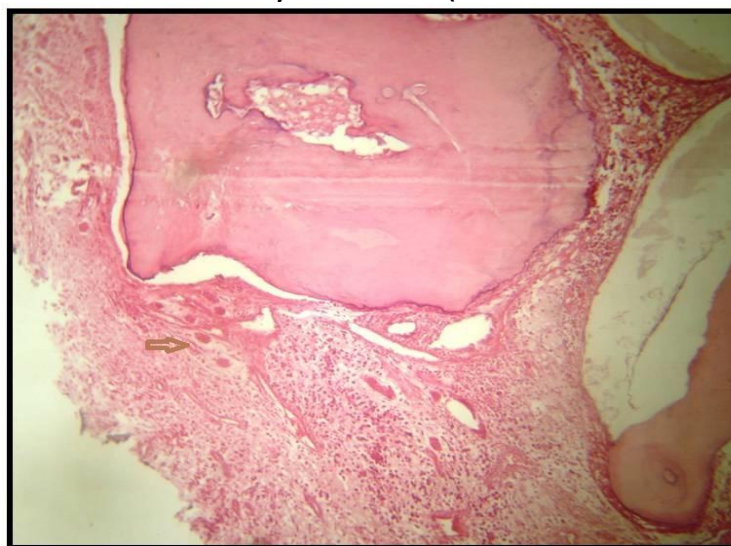
Radiographic Picture (OPG) showing large odontome (Red arrow) impacted third molar (Blue arrow) and associate radiolucency (Pink circle)

The radiopaque mass was surgically excised. The decalcified sections of the excision biopsy showed revealed disorderly arranged mature tubular dentin, cementum like material, enamel spaces and minimum area mimicking the dental pulp.

The surface of the odontome revealed cystic lining and multiple odontogenic islands in the associated connective tissue. The lining was non keratinised stratified squamous type with well formed rete ridges. Looking at the radiograph, nature of the epithelium, associated connective tissue, extensive odontogenic islands and associated inflammation the diagnosis of inflamed dentigerous cyst was considered. The final diagnosis of complex odontome was given. The inflamed dentigerous cyst probably in association with the impacted molar was given. Surgical removal of the impacted tooth followed by histopathological examination was suggested.



**Photomicrograph showing complex odontoma and associated cystic lining. The connective tissue shows dense chronic inflammatory cell infiltrate. (Decalcified section H& E 40X)**



**Photomicrograph showing multiple odontogenic islands in the inflamed connective tissue associated with the odontome. (Decalcified section H& E 40X)**

## DISCUSSION

Odontomas are considered as developmental anomalies originating from differentiated epithelial and mesenchymal cells precursors that give rise to ameloblasts and odontoblasts [4]. Though it is considered as a hamartoma, the World Health Organization

classifies this as a benign odontogenic tumor composed of odontogenic epithelium and odontogenic ectomesenchyme with dental hard tissue formation. It is classified into Compound and complex odontoma. It is common during first two decades of life. 9-37% of the odontogenic malformation is Compound odontomas, whereas the frequency of complex odontomas varies between 5% and 30%. Compound odontomas are more prevalent in maxillary anterior region whereas posterior mandibular region and anterior maxilla is the most frequent sites for complex odontome [4].

The radio-opaque structures surrounded by a radiolucent halo are diagnostic picture of odontomas. The radiolucent halo represents an enlarged dental follicle. In radiograph compound odontomas appear as multiple teeth like structures of varying size and shape whereas irregular radio dense masses represent complex odontomas. Depending upon the degree of calcification, radiographically three different development stages can be identified [4-6] In the preliminary stage due to the lack of calcification odontomas appear as radiolucent, intermediate stage is characterized by partial calcification; whereas at the end stage odontomas appear as radio-opaque structures surrounded by a radiolucent halo.

The histopathological examination of odontomas is mandatory to establish a definitive diagnosis. Histopathologically Compound odontomas resemble tooth. On the other hand, Complex odontomas represents conglomerates of dentin, enamel matrix, cementum and areas of pulp tissue without proper orientation. Odontogenic epithelium, odontoblasts and mesenchymal pulp tissue may be present in few cases. The connective tissue capsule present in odontoma is similar to that of dental follicle. Along with spherical dystrophic calcification ghost cells are often seen [5,6].

Due to its odontogenic nature, odontomas can develop dentigerous cyst due to epithelial and mesenchymal tissue. This cyst commonly results from the cystic degeneration of enamel organ after partial or total development of the crown. Cystic transformation of the follicle associated with the unerupted tooth may also occur when its eruption is hindered by the odontoma [3,7].

In our patient, correlating the radiographic and histological findings the origin of the dentigerous cyst was from the impacted tooth was suggested. Odontomas are treated by conservative surgical excision. Along with removal of odontoma, surgical excision of surrounding soft tissue is recommended to eliminate the possibility of its cystic degeneration. The lesion does not show any recurrence.

### CONCLUSION

Early diagnosis and surgical enucleation of odontoma followed by curettage is recommended to prevent various craniofacial complications such as bone expansion, delayed eruption of permanent teeth, tooth loss as well as cystic changes.

### REFERENCES

- [1] Santosh Patil, Farzan Rahman, Shoaib R Tipu, Sumeeta Kaswan. Oral Maxill Pathol J 2012;3(1).



- [2] Dua Nisha , Kapila Rishabh , Trivedi Ashwarya , Mahajan Sukriti , SD Gupta. J Dental Sci Res 2011;2(2):59-61.
- [3] Aydin Gulses, Umit Karacayli, Ramazan Koymen. OHDMBSC 2009;VIII(1):38-41.
- [4] Branca Heloísa de Oliveira, Vera Campos , Sonia Marçal. American Acad Pediatr Dent 2001;23(2):151- 157.
- [5] Neville, Damm, Allen, Bouquot, Oral and Maxillofacial Pathology,3<sup>rd</sup> Edition,Saunders Elsevier Inc.
- [6] Shafer, Hine, Levy, Shafer's Textbook of Oral Pathology,7<sup>th</sup> Edition, Saunders Elsevier Inc.
- [7] Anjan Shah,Madhumati Singh,Shouvik Chowdhury. Int J Clinl Dental Sci 2010;1(1):89-92.