

# Research Journal of Pharmaceutical, Biological and Chemical Sciences

## Easy, Fast and Accessible Dissecting Approach to Coracoid Process of Human Scapula.

Manal Fathi<sup>1</sup>, Paisal Hussin<sup>2</sup>, Nasir M Nizlan<sup>2\*</sup>, Cheah Pike See<sup>1,3</sup>, Umar Ahmad<sup>1,4</sup>,  
Aye Aye San<sup>1</sup>, Ezamin A Rahim<sup>5</sup>, and Fauziah Othman<sup>1,3</sup>.

<sup>1</sup>Department of Human Anatomy, Faculty of Medicine and Health Sciences, University Putra Malaysia, 43400 Serdang, Selangor, Malaysia.

<sup>2</sup>Department of Orthopedics, Faculty of Medicine and Health Sciences, University Putra Malaysia, 43400, Serdang, Selangor, Malaysia.

<sup>3</sup>Genetic Medicine Research Center, Faculty of Medicine and Health Sciences, University Putra Malaysia, 43400, Serdang, Selangor, Malaysia.

<sup>4</sup>Research Laboratory of Anatomy and Histology, Faculty of Medicine and Health Sciences, University Putra Malaysia, 43400, Serdang, Selangor, Malaysia.

<sup>5</sup>Department of Imaging, Faculty of Medicine and Health Sciences, University Putra Malaysia, 43600, Serdang, Selangor, Malaysia.

### ABSTRACT

Coracoid process of the scapula is an essential component of shoulder biomechanics, providing musculotendinous and ligamentous attachments around the scapula. Anatomically, it is one of the most important landmarks for identification of vital structures around the shoulder, and in approaching main blood vessels of the upper limb for research and clinical studies. Open shoulder surgery has become increasingly popular nowadays due to increase the incidence of shoulder injury. Knowledge on how to dissect and approach the coracoid process not only has a great clinical implication but also of significant importance to surgeons and researchers. This short study describes an easily accessible way to dissect the coracoid process of the scapula, without violating the pectoral region, of which can be of help or a guide for students, anatomists and researchers in dissecting the human coracoid process, while preserving other structures for future studies.

**Keywords:** accessible; human; coracoid process; scapula; dissection

*\*Corresponding author*

## INTRODUCTION

Coracoid process known in Greek as “G. korak-od’es” meaning, like a crow’s beak[1], also known as the "Surgeon's Lighthouse" serves as a vital anatomical landmark to avoid vascular damage[2]. Recently, scientists and researchers have demonstrated a lot of interest in studying the anatomy of the coracoid process [3,4] as it is the most prominent structure of acromioclavicular joint helping its stability, balance and use in bone transfer in the treatment of shoulder instability by clinicians [5] . Different approach have been used in most of the research institutes, clinics and surgical room in dissecting the coracoid process of the scapula during shoulder surgery and /or treatment of the affected deep brachial vessels.

It is hard to find a standard literature which described the dissection method to access the coracoid process which can allow researchers, scientists and anatomists to approach this important anatomical structure with minimal injuries to the adjacent structures.

Most dissection procedures that are frequently in used to expose the coracoid process of the scapula normally follows the surgical approach to operate the coracoid process, deltopectoral approach [6] . These procedures do not allow unobstructed visualization of the whole coracoid process. In addition, the detail method to approach the coracoid process of the scapula typically not described in anatomical dissection books. It is rather integrated as part of pectoral region dissection which involved reflecting pectoralis major muscles from their sternocostal and clavicular attachments followed by the pectoralis minor to its insertion until when the coracoid process is finally exposed [7]. Tank (2008) described a similar procedure for dissecting the pectoral region in other to approach the coracoid process of the scapula in human body. All of these procedures described above allow access to coracoid process at the expense of the integrity the pectoral region. Consequently, dissection of the anterior chest wall typically renders the pectoral regions unfit for continued study.

This study will therefore explored an alternative method to dissect the coracoid process of the scapula with the sole aim of achieving or making it so simple, more efficient, maintain the integrity of the pectoral region and thus successfully present this anatomical landmark for proper utilization of the procedure in area of researches with cadavers, anatomical studies. The description of these procedures are a bit modification of the deltopectoral approach which is the currently used in open shoulder surgeries[8].We described a simple processes to access the coracoid process of the scapula in human cadaver which is: (1) helping to maintain the integrity of the pectoral region, and (2) provide wide exposure of this anatomical structure to the level that a research can access it for further study.

## METHODOLOGY

### Ethical clearance

Ethical consent was sought and approved by the University Ethics Committee of the University Putra Malaysia (UPM) under the code: UPM/TNCPI/1.4.18.1 (JKEUPM) F2.

### Samples

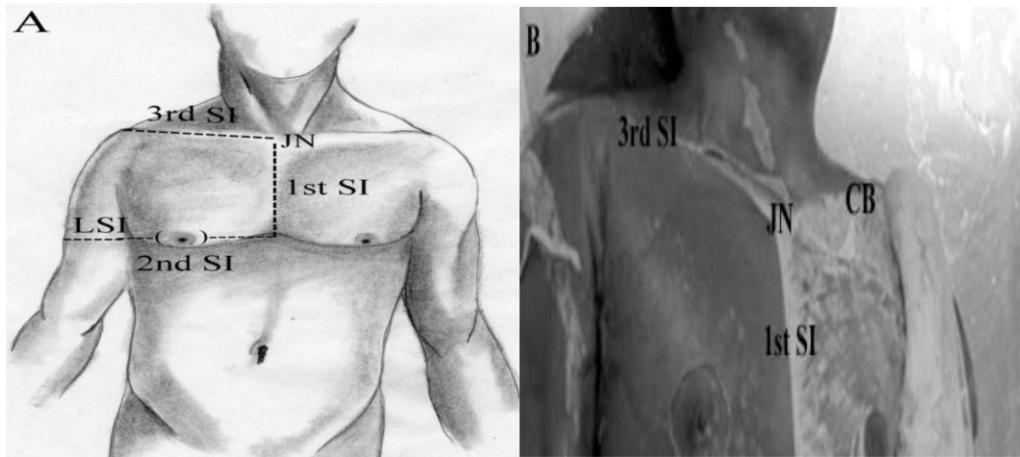
We have dissected 50 shoulders from 25 embalmed human cadavers available in the Anatomy dissection hall of the Human Anatomy Department of University Putra Malaysia to study the morphology of the coracoid process of the scapula among some ethnic groups available in the cadaver dissection hall.

### Simple Techniques to Follow

The cadavers were placed in supine position and both arms were abducted at an angle of ninety degree, 90°. Then, first skin incision was made along the midline of the sternum from the jugular notch to the level of fourth costal cartilages, along the fourth costal cartilage and fourth rib to a point at approximately the level of the mid axillary line. The second incision was made passing around the nipple and the third incision was made along the clavicle from the jugular notch to the acromioclavicular joint and from there the incision is then extended across the shoulder to the upper part of the arm.

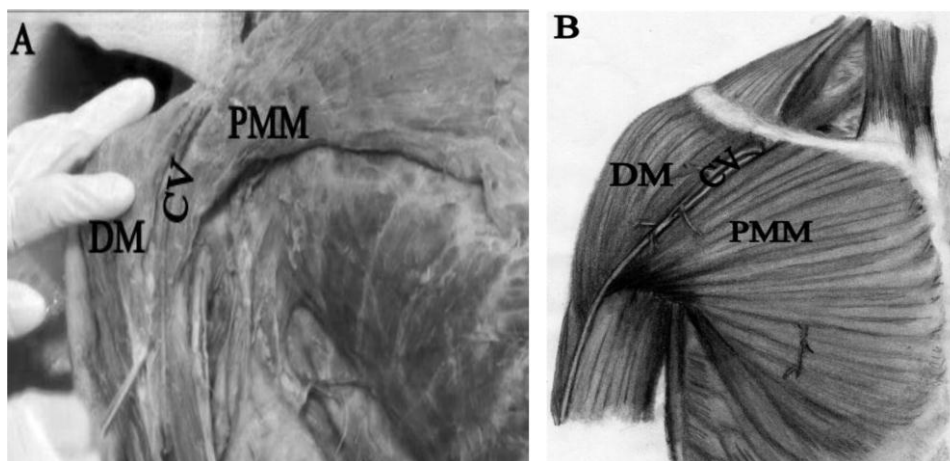
Lastly, the skin incision was made around the circumference of the upper arm to enable accessibility of the coracoid process of the scapula with minimal injuries to the adjacent vessels.

The skin was separated from the subcutaneous tissues, then reflected laterally and inferiorly. The skin flap at the upper arm was reflected laterally and superiorly. The fat and fascia surrounding the pectoralis major muscle and deltoid muscle was removed (Fig 1A and 1B)



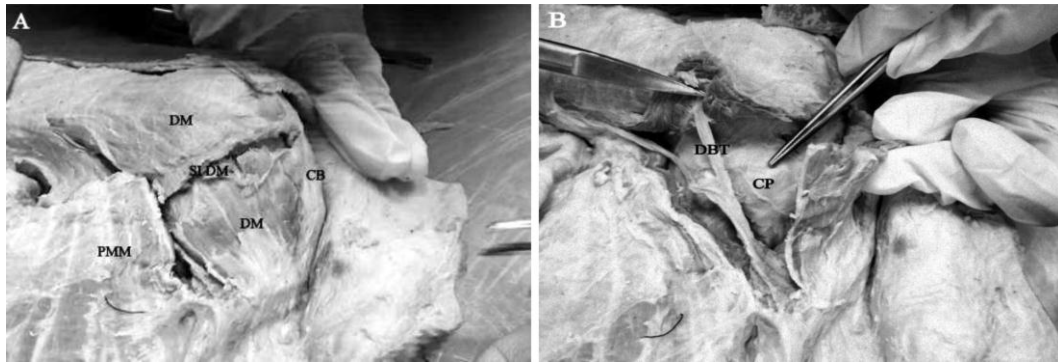
**Figure 1A:** The figure is showing the skin incisions with reflection of the skin and fascia prior to accessing the coracoid process. JN, Jugular notch; CB, Clavicle bone; 1<sup>st</sup> SI, 1st skin incision; 3<sup>rd</sup> SI, 3rd skin incision. **B:** A simplified diagram showing incisional lines to access coracoid. JN, Jugular notch; 1st SI, 1st skin incision; 2<sup>nd</sup> SI, 2<sup>nd</sup> skin incision; 3<sup>rd</sup> SI, 3<sup>rd</sup> skin incision; LSI; last skin incision.

Cephalic vein was identified following the medial border of the deltoid muscle, as it courses the deltopectoral groove that borders the deltoid and the pectoralis major muscle. However, in some cadavers the cephalic vein were difficult to locate, because it lies deep within these two parallel muscle fibers structures (Fig 2A and 2B).

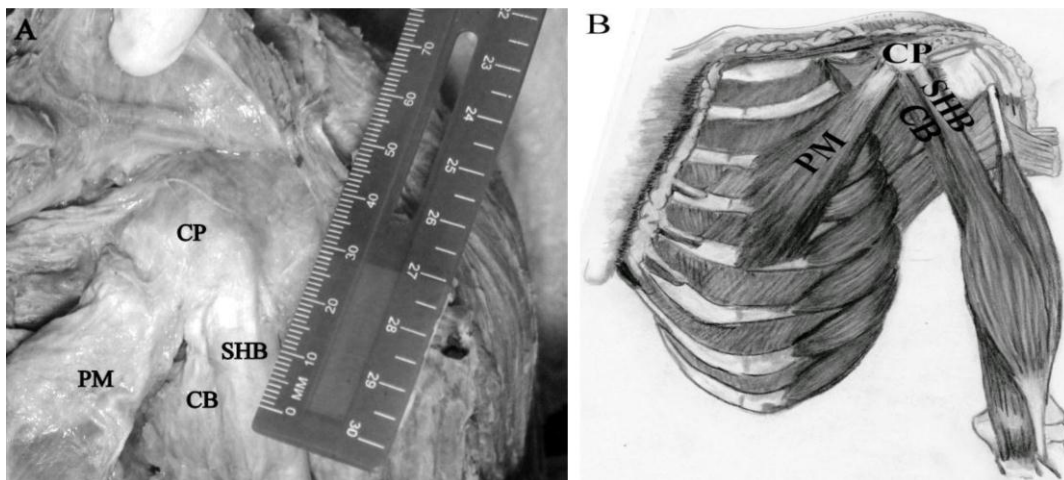


**Figure 2A:** The figure is showing the course of cephalic vein between pectorals major muscle and deltoid muscle. DM, Deltoid muscle; CV, Cephalic Vein; PMM, Pectoralis major muscle. **B:** An Atlas of the pectoral region showing the course of cephalic vein. DM, Deltoid muscle; CV, Cephalic Vein; PMM, Pectoralis major muscle

The deltoid muscle was in a relaxed position when the arm in 90° abducted position. A small incision was made in the middle of deltoid muscle and near to clavicular origin. The muscle was reflected upwards and laterally. The deltoid branch from the thoracoacromial artery that supplies the deltoid muscle can be seen during reflection of the deltoid muscle. Once this vessel was cut, (Fig 3A and 3B) the coracoid process was exposed as well as the muscles and ligaments attached to coracoid process as shown in the figure (Fig. 4A and 4B).




**Figure 3A:** The figure is showing the deltoid muscle with small incision. DM, Deltoid muscle; CB, clavical ; PMM , pectoralis major muscle; SIDM, the small incision in deltoid muscle B: The figure is showing the detoid branch of thoracoacromial artery. CP, coracoid process; DBT, detoid branch of thoracoacromial artery.



**Figure 4A:** The figure is showing the muscular attachment of coracoid process. CP, coracoid process; PM, pectoralis minor; SHB, short head of biceps; CB, coracobrachialis B: An Atlas is showing the muscular attachment of coracoid process. CP, coracoid process; PM, pectoralis minor; SHB, short head of biceps; CB, coracobrachialis

The pectoralis minor was inserted to the anterior border of coracoid process, lateral to the origin of the coracobrachialis and short head of biceps brachii muscle. All these muscles and ligaments are dissected at their attachment area to the coracoid process (Fig. 5) which allow the coracoid process to be exposed and ready to be measured for further study.



**Figure 5.** The figure is showing the coracoid process CP, coracoid process.



## DISCUSSION

This short communication report describes a simple method to approach the dissection of the coracoid process in the human cadaver. It gives wide exposure of coracoid process for the study of anatomical structures of the region, bones density as well as given clue to properly access this bone for researches relates to anthropometric studies.

In this short modified method, the skin was reflected laterally and the fat, fascia removed, the pectoralis major and deltoid muscles are clearly defined, which correlated with some previous published reports on dissection procedures of pectoral region [7,9], unlike the previously published techniques, where the pectoralis major and pectoralis minor muscles were dissected to expose the coracoid process [7,9].

Our alternative approach seems to be consistent with the deltopectoral approach used in shoulder surgery with which the coracoid process can easily be approach once the deltopectoral groove with cephalic vein was identified, and the pectoralis major and the deltoid was retracted upward and as well as laterally to access the coracoid process [8]. In contrast, this new approach method to the coracoid process can easily be undertaken and the clavicular origin of the deltoid muscle could be dissected with minor injuries to enable the identification of the coracoid process.

Although the dissection method presented here differs from other methods to approach the coracoid process, it can be utilize by students of anatomy while taking dissection and by some researchers who might want to access coracoid process easily and rapidly for their onward researches.

## CONCLUSION

This new technique allows researchers, scientists, anatomists and/or students to approach the coracoid process while maintaining the integrity of pectoral region for other researchers or anatomists with musculoskeletal focus. Performing the technique presented above, doesn't require long time dissection but rather provide more easier and accessible way to approach the coracoid process with minor injury.

## ACKNOWLEDGMENTS

The authors are grateful to the donors of the cadavers used in this study and their families. The authors thank Dr. Ismail Abuzid for drawings and Dr. Nadia Khermani for technical support and kind advice. The authors also express special thanks to members of the Anatomy dissection hall, Human Anatomy Department, University Putra Malaysia, for their kind support.

## REFERENCES

- [1] Moore KL, Dalley AF, Agur AM: Clinically oriented anatomy. Lippincott Williams & Wilkins; 2013.
- [2] Gallino M, Santamaria E, Doro T. J Shoulder Elbow Surg 1998;7:284-291.
- [3] Bhatia DN, de Beer JF, du Toit DF. Clin Anat 2007;20:774-784.
- [4] Rios CG, Arciero RA, Mazzocca AD. The American J Sports Medi 2007;35:811-817.
- [5] Higgins MA, Tambe A. Shoulder Elbow 2012;4:117-118.
- [6] Freehill MT, Srikumaran U, Archer KR, McFarland EG, Petersen SA. J Shoulder Elbow Surg 2013; 22:695-700.
- [7] Romanes G: - Romanes GJ. (1986). Cunningham's Manual of Practical Anatomy. Vol. 1: Upper and Lower Limbs. 15th Ed. New York: Oxford University Press. 1986.
- [8] Webb M, Funk L. Tech Shoulder Elbow Surg 2006;7:77-81.
- [9] Tank P: Grant's Dissector. 14th Ed. Baltimore, MD: Lippincott Wiliams & Wilkins. 43,45 p.; 2008.