

# Research Journal of Pharmaceutical, Biological and Chemical Sciences

## Pancreatic Divisum: A Rare Case Report.

Sankara Narayanan B\*, and Amkumar B.

Sree Balaji Medical College and Hospitals, Bharath University, Chrompet, Chennai-44, Tamil Nadu, India.

### ABSTRACT

Pancreatic divisum is a congenital ductal anomaly of the pancreas where the major secretions of the pancreas drain by the dorsal duct. This occurs due to non-fusion of dorsal and ventral duct during the development of pancreas. The majority of the secretions have to drain via the small opening of the minor papillae causing obstruction and recurrent pancreatitis. This is a case of a 12-year-old male with recurrent pancreatitis diagnosed as pancreatic divisum.

**Keywords:** pancreatic divisum, pancreatitis, calculi

*\*Corresponding author*

**INTRODUCTION**

Pancreatic divisum is an rare congenital anomaly caused by the failure of the fusion of the dorsal and ventral bud of pancreas around the 8<sup>th</sup> week of intrauterine life [1]. It is the most common congenital variant of pancreas. Incidence is 10% worldwide and 1-2% among Asian population [2]. Most of the time, pancreatic divisum is found out incidentally. In more than 90% of individuals, the proximal one third of the dorsal pancreatic duct regresses as it fuses with the ventral duct, forming the main pancreatic duct.

**Case Report**

12 year male child came to the casualty with the complaints of abdominal pain over the epigastrium and left hypochondrium on and off for 6months duration, loss of appetite for 6 months and vomiting for 1week duration. No H/o of Type I DM/ allergy. No H/o any congenital anomaly among family members. No relavent surgical history in the past. On examination child was found to be thin built, afebrile, anemic, not jaundiced, no significant regional lymphadenopathy. Vitals were found to be normal for his age. Cardiovascular, respiratory system were normal. Abdomen were soft, tenderness present over the epigastrium and the umblical region, no guardity, rigidity and no mass felt in the abdomen.

Investigation revealed Hb 8.6gm, elevated WBC count, elevated serum amylase and lipase level. Ultrasonography of the abdomen revealed acute pancreatitis. Further investigation like upper gastro endoscopy was normal and MRI Abdomen revealed mildly dilated pancreatic duct, calculi in the pancreatic duct inferior division suggestive of chronic pancreatitis and Pancreatic Divisum is also noted. Hepato biliary scintigraphy revealed severe dysfunction of the gall bladder. Patient was put on nil per oral, broad spectrum antibiotics, and surgery was advice for the pancreatic divisum. As the patient improved clinically and the parents was not willing for surgery, patient was advice for regular follow up.

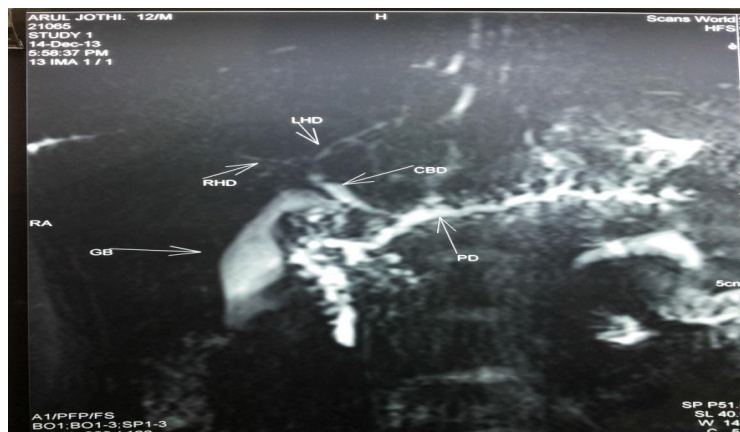


Figure 1: MRI showing pancreatic divisum.

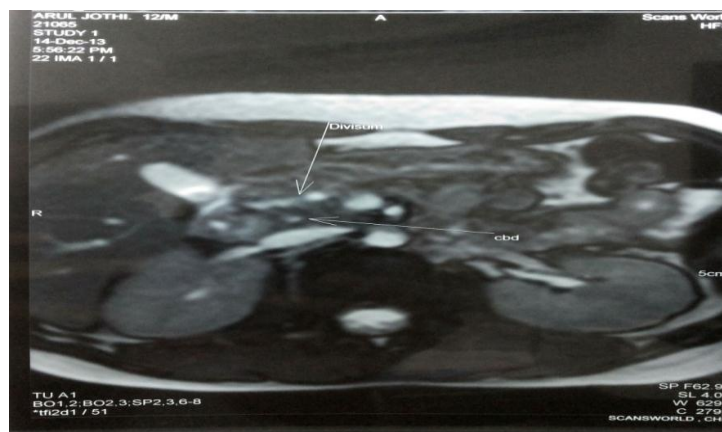

Figure 2: Section of MRI abdomen showing divisum.

## DISCUSSION

Pancreatic divisum is a congenital anomaly. Due to pancreatic divisum, most of the secretion drains through the minor papilla (dorsal duct) and the remaining secretion drains through the major papilla (ventral duct) [3]. Small caliber of the minor papilla and the large amount of secretion leads to outflow obstruction leading to pancreatic calculi and chronic pancreatitis [4]. Increased flow of pancreatic juice caused by fatty diet in combination with papillary stenosis may lead to ductal pressure which also leads to development of pancreatitis [5]

There are three types of pancreatic divisum. Type I (classic and complete) showing no communication between dorsal and ventral duct (70%). Type II (absent ventral duct) showing dorsal duct drains the entire pancreas (20-25%). Type III (functional and incomplete) showing inadequate connection between dorsal and ventral ducts (5-10%). Patients with pancreatic divisum may have a genetic component, including mutations or variants of the cystic fibrosis transmembrane conductance regulator gene (IVS8-5T variant) [6]. There are reports of familial PD but the exact relation between genetic markers and pancreatic divisum is noted. In this case, there is no connection between the dorsal and ventral duct thereby this belongs to Type I and complete pancreatic divisum [7].

## CONCLUSION

Pancreatic divisum leads to chronic and recurrent pancreatitis, pancreatic calculi, hepato-biliary dysfunction, pancreatic tumours. CT scan, MRI can be used to diagnose pancreatic divisum, but MRCP is the diagnostic tool of choice because of its non-invasiveness and high resolution [8]. Pancreatic divisum as a possible cause for pancreatitis should always be kept in mind. This is especially important in young adults since most of them are misdiagnosed as alcoholic, hypertriglycemic, or idiopathic [8]. As accurate diagnosis of pancreatic divisum is important in allowing clinicians to consider more aggressive approach such as sphincterotomy for pancreatic divisum patients with repeated pancreatitis and persistent pain.

## REFERENCES

- [1] Borak G, Alsolaimon M, Holt E, et al. *Gastrointest Endosc* 2005; 61: 149A.
- [2] Delhaye M, Cremer M. *Acta Gastroenterol Belg* 1992;55:306-13.
- [3] Fogel EL, Toch TG, Lehman GA, Dilmagno MJ. *Pancreas* 2007; 34:21-45.
- [4] Suga T, Nagakawa T, Miyakawa H. *Dign Endosc* 1994;. 6: 80-6.
- [5] *Radiol* 1996; 199: 99-103.
- [6] *Gut* 1980;21: 105-14.
- [7] Warshaw AL, Simeone JF, Schapiro RH, Flavin-Warshaw B. *American J Surg* 1990;159: 59-64.
- [8] Zeman RK, McVay LV, Silverman PM, et al. *Radiol* 1988;. 169: 395-8.