

Research Journal of Pharmaceutical, Biological and Chemical Sciences

Rare Presentation of Pseudomembranous Colitis: A Case Report.

Aishwarya S*, Hemalatha Ganapathy, and Parijatham BO.

¹Department of Pathology, Sree Balaji Medical College, Chennai, Tamil Nadu, India.

ABSTRACT

Pseudomembranous colitis usually presents with fever, diarrhoea in hospitalized patients who are treated with a course of antibiotic. A 50 year old female patient presented to the outpatient department with symptoms of acute intestinal obstruction. Laparotomy was done, which showed a concealed perforation in the hepatic flexure with dense omental adhesions. Right hemicolectomy was done and specimen sent for histopathology. Gross examination showed mucosa of colon with multiple, irregular ulcers covered by necrotic, yellowish material with edematous regions. Microscopy showed ulceration of colonic mucosa and replacement by fibrinous exudate composed of dense inflammatory cell aggregates. Multiple ulcers showed eruptive volcano like mucosal exudates. Hence, dignosed as a case of pseudomembranous colitis. This case is reported for the rare presentation and complication of psedomembranous colitis.

Keywords: Antibiotic therapy, diarrhea, pseudomembrane, *Clostridium difficile*

**Corresponding author*

INTRODUCTION

Clostridium difficile associated disease is a unique colon infection acquired in association with antimicrobial use and consequent disruption of normal colonic flora causing diarrhoea and pseudomembranous colitis (PMC). Clindamycin, lincomycin and third generation cephalosporins are associated in a substantial number of cases. The cardinal clinical symptom of PMC is watery diarrhoea. Other associated symptoms are fever, abdominal cramps and at times, nausea and vomiting. Here we report a rare case of PMC, with no episodes of diarrhoea and presented as acute surgical abdomen.

CASE REPORT

A 50 yr old female patient presented with severe abdominal cramps, vomiting, bloated abdomen for 3 days. Previous history of open cholecystectomy- 2 months back for which post operatively, cefotaxim and amikacin were used. Known case of diabetic on oral hypoglycemic drugs.local examination revealed a diffuse tender abdomen. Leucocyte count was 18,470 cells/cubic mm, platelet count was 6.45 lakhs/cubic mm and ESR was 32 mm. ultrasonogram of the abdomen showed dilated bowel loops with adhesive colitis. On laparotomy, there was a concealed perforation in the hepatic flexure with dense omental adhesions. Hence, proceeded with right hemicolectomy and the specimen was sent for histopathological examination.

Histopathology

Gross

Figure 1 shows ileum – 10 cm, appendix – 5 cm and colon – 30 cm. Figure 2 shows mucosa of the colon with multiple irregular ulcers covered by yellowish necrotic material. Serosa was irregular throughout the colon with perforations and adhesion at the distal end.

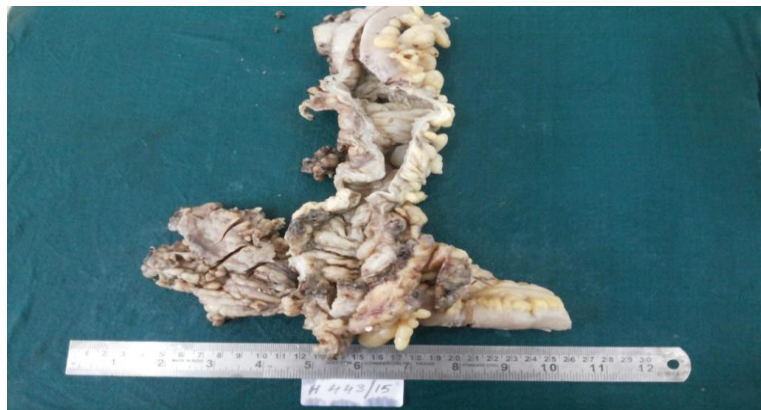

Figure 1 showing right hemicolectomy specimen with: ileum – 10 cm, appendix – 5 cm and colon – 30 cm

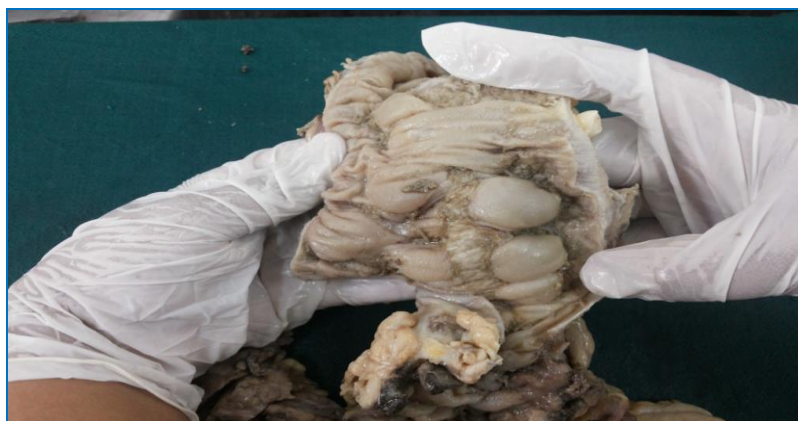

Figure 2 shows colonic mucosa with plaque-like lesions and edema

Microscopy

Figure 3- 40 X view shows ulcer in colonic mucosa distended by eruptive, volcano-like exudate .Figure 4- 40 X view shows pseudomembrane made of fibrin, mucus and inflammatory cell aggregate overlying colonic mucosa.

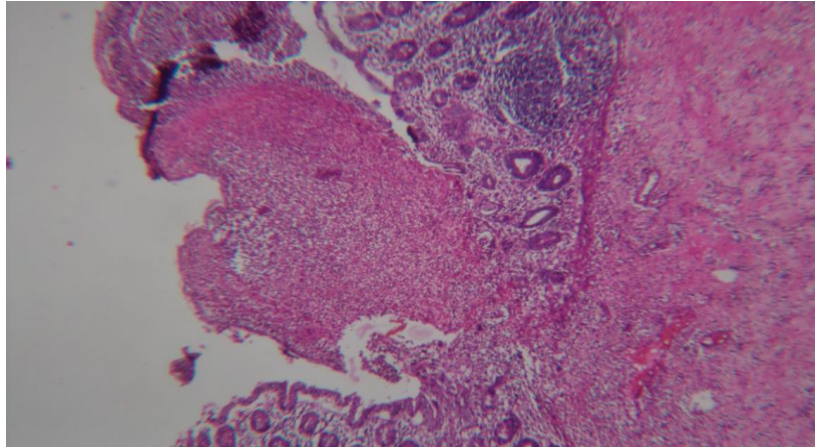


Figure 3 40 X view showing ulcer in the colonic mucosa distended by eruptive volcano – like / mushroom mass – like exudate.

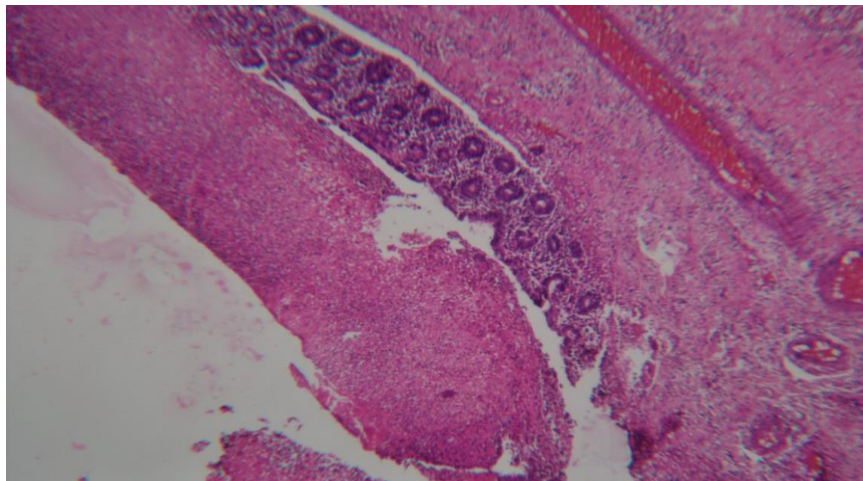


Figure 4 40 X view showing pseudomembrane made of fibrin, mucus and inflammatory cell aggregate overlying colonic mucosa.

DISCUSSION

SYNONYM: Antibiotic associated colitis or antibiotic associated diarrhoea.

It is characterized by formation of a plaque-like adherent layer of inflammatory cells and necrotic debris overlying sites of mucosal injury in the colon.

Does not have a true epithelial lining & hence called a pseudomembrane. Generally occurs either during or 5 – 10 days after a course of antibiotic therapy. Infrequently, symptoms present as late as 10 weeks after cessation of therapy [1].

Watery diarrhea of is the cardinal clinical symptom of *C. difficile* infection. Watery diarrhea upto 10 or 15 times daily with lower abdominal pain and cramping, low grade fever, and leukocytosis are the clinical manifestations [2].

Rarely, it presents as fulminant colitis with severe lower quadrant or diffuse abdominal pain, diarrhea, abdominal distention, fever, hypovolemia, lactic acidosis, hypoalbuminemia, and marked leukocytosis (up to 40,000 white blood cells/microL or higher) [2-5]. Diarrhea may be less prominent in patients with prolonged ileus due to pooling of secretions in the dilated, atonic colon. Other potential complications of fulminant colitis include toxic megacolon and bowel perforation [6,7].

Bowel perforation presents with abdominal rigidity, involuntary guarding, diminished bowel sounds, rebound tenderness, and severe localized tenderness in the left or right lower quadrants. Abdominal radiographs may demonstrate free abdominal air.

CONCLUSION

Pseudomembranous colitis can cause a spectrum of manifestations ranging from the asymptomatic carrier state to severe fulminant disease with toxic megacolon and bowel perforation (5,6) due to various unknown host and pathogen factors. Hence, aggressive diagnostic and therapeutic interventions are warranted in the setting of fulminant *C. difficile* infection though the patient does not present with the cardinal symptom of watery diarrhea as in this case study.

REFERENCES

- [1] Tedesco FJ. Med Clin North Am 1982; 66:655.
- [2] Wanahita A, Goldsmith EA, Musher DM. Clin Infect Dis 2002; 34:1585.
- [3] Wanahita A, Goldsmith EA, Marino BJ, Musher DM. Am J Med 2003; 115:543.
- [4] Bulusu M, Narayan S, Shetler K, Triadafilopoulos G. Am J Gastroenterol 2000; 95:3137.
- [5] Rubin MS, Bodenstein LE, Kent KC. Dis Colon Rectum 1995; 38:350.
- [6] Kelly CP, LaMont JT. N Engl J Med 2008; 359:1932.
- [7] Bagdasarian N, Rao K, Malani PN. JAMA 2015; 313:398.