

Research Journal of Pharmaceutical, Biological and Chemical Sciences

The Protective Effect of Hesperidin Against Gentamicin Induced Acute Tubular Necrosis in Mice.

Mohammed Abdul Muttalib Abdul Bari*.

Department of therapeutics, Baghdad collage of pharmacy, Iraq.

ABSTRACT

Flavonoids are the most frequent and generally distributed group of plant phenolic compounds, They are a major coloring component of flowering plants. Flavonoids have a significant portion of human and animal diet. Many foods source containing different classes of flavonoids. Hesperidin is a glycoside composed of the flavanone hesperedin (aglycone) and the disaccharide rutinose. it has a protective role against fungal and other microbial infections in plants. The main advantages are correlated to its antioxidant and anti-inflammatory properties. On the other hand Many antibiotics may affects the renal system in one way or other, Gentamicin is an aminoglycoside antibiotic. Its accumulation in proximal renal tubules could lead to nephrotoxicity due to brush border network damage. it was documented that Gentamicin nephrotoxicity is related to renal free radical production and acute tubular necrosis and glomerular congestion. In the present study, mice treated with gentamicin 80mg /kg/day for 15 days and an evaluation between normal, positive and positive treated group has been done. A significant reduction on kidney function parameter has been observed between gentamicin treated and (gentamicin plus Hesperidin) treated group. Hesperidin treated group shown a significant halted effect on gentamicin induced acute tubular necrosis in mice

Keywords: Flavonoids, Hesperidin, gentamicin, nephrotoxicity.

**Corresponding author*

INTRODUCTION

Flavonoids are one of the most widespread and commonly distributed group of plant phenolic compounds, distributed almost in all plant parts, largely the photosynthesising plant cells. They are a major coloring component of flowering plants and an vital part of human and animal diet. A lot of food sources found to have a different classes of flavonoids .As a phytochemicals, humans and animals cannot be synthesized flavonoids. [1]

In foods they are normally responsible for color, taste, prevention of fat oxidation, and protection of enzymes and vitamins. [2] It available in the maximum amounts in the human diet include the soy isoflavones, flavones and the flavonols. And the levels is differ from 4.5 to 610mg/kg. [3]

Newly there has been an raise of interest in the therapeutic possible of medicinal plants which might be as a result of their phenolic compounds, specifically to flavonoids. [4, 5]

The antioxidant activity of flavonoids participate a major role in their biological properties that support human health and help reduce the hazard of diseases. LDL cholesterol Oxidation was found to play a main role in atherosclerosis. The isoflavanglabridin, a main polyphenolic compound available in Glycyrrhizaglabra (Fabaceae), inhibits LDL oxidation through a mechanism relating to scavenging of free radicals. [6]

The antioxidant effects of flavonoids related to the arrangement of functional groups around the nuclear structure. Numbers of hydroxyl groups and its Configuration, substitution significantly affect several mechanisms of antioxidant activity such as radical scavenging and metal ion chelation ability. [7, 8]

The antioxidant action is mainly be composed of suppression of Reactive oxygen species (ROS) creation either by inhibition of enzymes or by chelating trace elements occupied in free radical generation; scavenging ROS; and protection of antioxidant defenses.[9]

The therapeutic interest of Bioflavonoids has been shown to improved eyesight, enhanced cardiovascular health, increased capillary strength, enhanced structure of connective tissues and appearance of skin, and a stronger immune system.[10]

Bioflavonoids also participate in the health-promoting effect of lowering the hazard of some diseases, such as atherosclerosis, arthritis, cancer and gastrointestinal disorders. 11]

One of the Bioflavonoids is Hesperidin, which is obtained from the word “hesperidium” that refers to fruit produced by citrus trees – lemons, limes, oranges, tangerines, the main source of hesperidin. [12]

Its maximum concentrations are found in citrus fruit peels , for example, peels from tangerines contain hesperidin the equivalent of 5-10 % of their dry mass.[13]

Hesperidin acting as a protective role against fungal and other microbial infections in plants. owing to its physiological antimicrobial activity, decades of research discovered its many therapeutic applications in prevention and treatment of many human disorders. The majority of these advantages are related to its antioxidant and anti-inflammatory properties. [14]

On the other hand drugs that induced kidney disease form an significant cause of acute renal failure and chronic kidney disease in present day clinical practice. many classes of drugs, by asset of immunological mechanisms or direct toxicity make a certain stereotyped renal responses. risk factors for most patients affected by drug induced nephropathy include: old age, pre-existing renal dysfunction , volume -depleted state and coexisting use of other nephrotoxins.[15]

Buildup of gentamicin in proximal renal tubules may cause nephrotoxicity which cause a brush border network damage . The nephrotoxicity involves renal free radical production and accumulation , glomerular congestion , consumption of antioxidant defense mechanisms , and acute tubular necrosis [16]. The Aim of

our study was to show the nephroprotective effect of hesperidin against gentamycin induce acute tubular necrosis in mice.

MATERIAL AND METHODS

This study was done at the biotechnology research center of Al-Nahrin university . Eighteen male albino mice 6–8 week old, weighing 20– 25 gm each were procured from the same center .

They were reserved under controlled temperature (23–25 °C), humidity (60%), light and dark cycles of 12 hours each and allowable to acclimatize for seven days. The animals were fed on standard mice diet and water *ad libitum* and were weighed at the beginning of the experiment.

The animals were then separated into three groups, divided by six mice for each.

Group A was the negative control and were set 1 ml distilled water per day by mouth.

Group B served as a positive control, 80 mg/Kg/day of dissolved in 1 ml of distilled water gentamicin was given intraperitoneally for 15 days.

Group C given bioflavinoid (hesperidin) 10 mg/Kg/day for 8 days before and along with gentamicin for fifteen days

Group D given bioflavinoid (hesperidin) 20 mg/Kg/day for 8 days before and along with gentamicin for fifteen days

The body weight of each animal was given twice weekly and also at the end of the experimental period when each animal was taken out of cage and euthanized under chloroform before 2 ml of blood was taken in 5 ml disposable syringe by cardiac puncture.

Serum was separated and stored at -20 C for measuring urea and creatinine. Each animal was then sacrificed, kidneys removed and examined for gross changes, 2 mm³ pieces were taken for routine histology and fixed in 10% formalin. Sections were cut at five micron on a motorized microtome and stained with H and E.

The plasma creatinine and urea were measured by using an AutoAnalyzer (Olympus AU 600, Tokyo, Japan).

To evaluate tissue damages and measured the possible protective effects of hesperidin, histopathological evaluation was done, all the slides stained with H & E were examined by an pathologist using light microscope. Bowman's space size and glomerular diameter were measured using light microscope and scaled ocular lens. Tissue damages were classify according to glomerular atrophy, tubular necrosis and fibrosis, perivascular edema and vascular congestion

To classify tissue damages , the decrease in glomerular diameter in the group with the most severe changes, in comparison to the positive group, was evaluated as the 100% damage and in other groups the changes were scored accordingly. The Other cell damages were measured as the percentage of the total area observed under the microscope.

Damage scoring was as follows:

no damage was evaluated as zero,

1-20 % damage was evaluated as as grade 1.

21-40 % damage was evaluated as as grade 2 .

41- 60 % damage was evaluated as as grade 3 .

61-80 % damage was evaluated as as grade 4 .

81-100 % damage was evaluated as as grade 5.

Finally, the total histopathologic score was calculated which was equal to the sum of all different degrees of damages.

The data was analysed using SPSS version 22 . Mean±SE is given for quantitative variables. One way ANOVA was used to compare the groups and Tukey post hoc test was used for detail analysis. Fisher Exact Test was applied to observe association between qualitative variables. Differences between groups were considered to be statistically significant, if $p < 0.05$. [17]

RESULTS

Negative control group (group A) showed blood urea concentration 27.0 ± 0.894 mg/dl this concentration has been increased significantly to 55.20 ± 4.20 mg/dl (group B) which was treated with 80 mg/Kg/day of gentamicin intraperitoneally for fifteen days. On the other hand blood Creatinine level in negative control group (group A) was 0.51 ± 0.03 mg/dl while the positive control group Creatinine level was 0.96 ± 0.18 mg/dl .

On comparing to (hesperidin) 10 mg/Kg/day treated group it was shown that blood urea was 38.3 ± 3.14 mg/dl (-30.06% in compare to positive control group) ($p < 0.01$) and the Creatinine level was 0.73 ± 0.051 mg/dl (-23% in compare to positive group) ($p < 0.01$) on increasing the dose of hesperidin to 20 mg/Kg/day the urea concentration become 32 ± 2.1 mg/dl (-42% in compare to positive group) ($p < 0.05$) and the Creatinine level was 0.56 ± 0.051 mg/dl (-41% in compare to positive control group) ($p < 0.05$) . (figure 1, 2)

The histopathological assessment of the experiment showed a clear healing and protective effect of the hesperidin treated group in compare to positive control group . the positive control group show a gentamicin caused a marked increase in glomerular atrophy, tubular necrosis and fibrosis, perivascular edema and vascular congestion (table 2) Pretreatment with hesperidin could alleviate this damages in such a way that the total histopathologic score which had significantly increased by gentamicin ($P < 0.05$), was markedly decreased by hesperidin near to its level in negative group

Table 1: Blood urea nitrogen , ceratinine concentration in treated, negative and positive control group * significant differences in compare to negative control($p < 0.05$) ** highly significant differences in compare to negative control($p < 0.01$) . ^x significant differences in compare to positive control ($p < 0.05$) . ^{xx} highly significant differences in compare to negative control($p < 0.01$) .

	negative control (group A)	positive control (group B)	Treated group (100 mg/Kg/day (group C)	% of changes in compare to group B	Treated group (200 mg/Kg/day (group D)	% of changes in compare to group B
Blood urea	27.0 ± 0.894 mg/dl	55.20 ± 4.20 mg/dl	$38.3 \pm 3.14^{**xx}$ mg/dl	-30.06%	$32 \pm 2.1^{*x}$ mg/dl	-42%
Creatinine	0.51 ± 0.03 mg/dl	0.96 ± 0.18 mg/dl	$0.73 \pm 0.051^{**xx}$ mg/dl	-23%	$0.56 \pm 0.051^{*xx}$ mg/dl	-41%

Table 2: Effects of hesperidin administration on renal histopathologic scores induced by gentamicin (* $P < 0.05$, as compared to Positive control group)

	Negative control group	Positive control group	(hesperidin) 10 mg/Kg/day	(hesperidin) 20 mg/Kg/day
glomerular atrophy	0	5	2	1.5
tubular necrosis	0	2.5	1.5	1.0
Fibrosis	0.1	1.5	0.75	0.75
perivascular edema	0	3.5	2.25	1.75
vascular congestion	0	2.75	1.5	1
Total histopathologic score	0.1	15.25	8*	6*

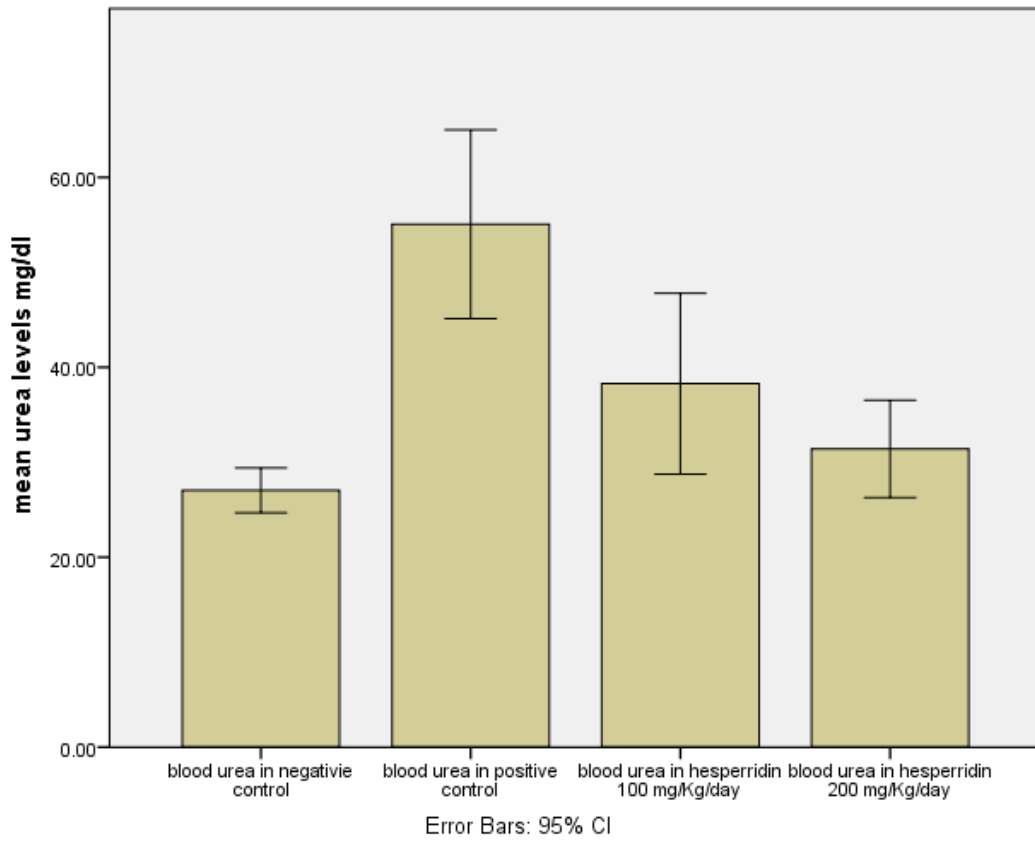


Fig 1: Blood urea concentration in both treated group , negative and positive control group after 15 day of induction.

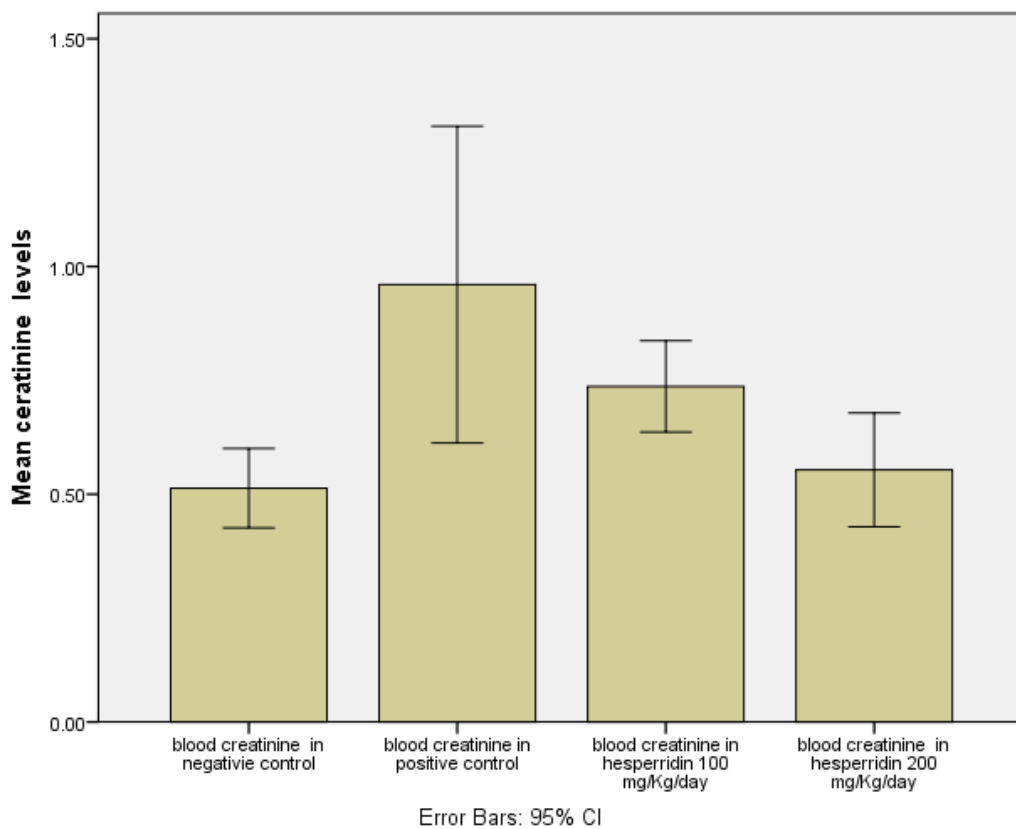


Fig 2: Creatinine nitrogen concentration in both treated group , negative and positive control group after 15 day of induction.

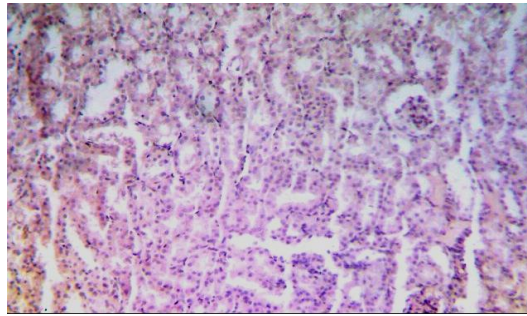


Figure 3: Section of kidney from group A, showing glomerulus , parietal layer , and visceral layer, proximal convoluted tubule lined with cuboidal epithelium and intact basement membrane.

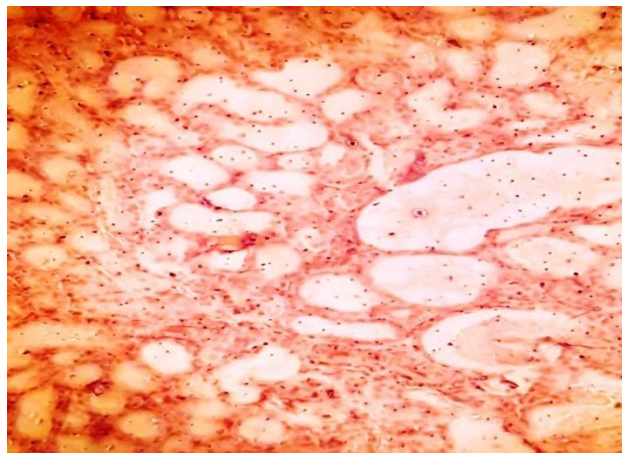


Figure 4: A section of kidney from group B, showing damaged and dilated tubule with desquamating epithelium having cytoplasmic vacuolations.



Figure 5: Photomicrograph of histological section of kidney from group C, most tubules have smudged appearance, showing glomerulus , cytoplasmic vacuolations intact basement membrane.

DISCUSSION

The capability to scavenge free radicals is necessary and beneficial for human health, since excess of free radicals leads to oxidative stress that adversely affects cell structure and function. Oxidative stress triggers inflammation, which further potentiates oxidative stress in a vicious cycle, triggering various life threatening diseases ranging from cardiovascular and neurodegenerative disorders to diabetes and cancer.[18]

Hesperidin not only scavenges free radicals but can also stimulate the endogenous antioxidant defense mechanisms. These mechanisms improved activity and production of cellular antioxidant enzymes for

instance superoxide dismutase (SOD), heme-oxygenase-1 (HO-1), catalase and elevation of the predominant cellular antioxidant called glutathione.[19]

The antioxidant hesperidin, a main flavonoid in sweet orange and lemon, was examined using chemical and biological systems. Biological experiments were made using the eukaryotic cells of superoxide-dismutase proficient and deficient strains of *Saccharomyces cerevisiae* treat with hesperidin and the stressing agents hydrogen peroxide or paraquat. [20]

A research done by Ahmad .S. et.al . found that The hypolipidemic , anti-inflammatory , and the antioxidant actions of the natural compounds , particularly hesperidin showed to have a quite effectiveness against rheumatoid arthritis and atherosclerosis. Thus, their utilization may be supportive in prevention or at least delaying the onset of these diseases in individuals at risk .[21]

Other protection effect of hesperidin was examined by (Rezaeyan A et al 2016) how found that oral administration of hesperidin offer a protection against γ -irradiation- induced pulmonary damage and oxidative stress in rats, probably by its protective effect against inflammatory disorders via its free radical scavenging and membrane stabilizing ability.[22]

In the present study, mice treated with gentamicin 80mg /kg/day for 15 days showed reduction in GFR which was substantiated by an increase in serum creatinine and BUN levels. In addition, gentamicin induced increase in serum creatinine and BUN levels were significantly halted , hesperidin bringing about marked recovery in kidneys. Similar findings were also observed in other studies.

ACKNOWLEDGEMENTS

Praise is to our almighty Allah gracious for enabling me finish what I started and for helping me to present this work. I would like to express my sincere gratitude, great appreciation to my family .

REFERENCES

- [1] R.Koes,W.Verweij, andF.Quattrocchio, "Flavonoids: a colorful model for the regulation and evolution of biochemical pathways," *Trends in Plant Sciences*, vol. 10, no. 5, pp. 236–242, 2005.
- [2] L. H. Yao, Y. M. Jiang, J. Shi et al., "Flavonoids in food and their health benefits," *Plant Foods for Human Nutrition*, vol. 59, no. 3, pp. 113–122, 2004.
- [3] I. C. W. Arts, V. B. Putte, and P. C. H. Hollman, "Catechin contents of foods commonly consumed in the Netherlands 1. Fruits, vegetables, staple foods and processed foods," *Journal of Agricultural and Food Chemistry*, vol. 48, no. 5, pp. 1746–1751, 2000.
- [4] F. Pourmorad, S. J.HosseiniMehr, andN. Shahabimajd, "Antioxidant activity, phenol and flavonoid contents of some selected Iranian medicinal plants,"*The African Journal of Biotechnology*, vol. 5, no. 11, pp. 1142–1145, 2006.
- [5] S. Kumar and A. K. Pandey, "Antioxidant, lipo-protective and antibacterial activities of phytoconstituents present in *Solanum xanthocarpum* root," *International Review of Biophysical Chemistry*, vol. 3, no. 3, pp. 42–47, 2012.
- [6] B. Fuhrman, S. Buch, and J.Vaya, "Licorice extract and itsmajor polyphenol glabridin protect low-density lipoprotein against lipid peroxidation: in vitro and ex vivo studies in humans and in atherosclerotic apolipoprotein E-deficient mice," *The American Journal of Clinical Nutrition*, vol. 66, no. 2, pp. 267–275, 1997.
- [7] E. H. Kelly, R. T. Anthony, and J. B.Dennis, "Flavonoid antioxidants: chemistry, metabolism and structure-activity relationships," *Journal of Nutritional Biochemistry*, vol. 13, no. 10, pp. 572–584, 2002.
- [8] A. K. Pandey, A. K. Mishra, and A. Mishra, "Antifungal and antioxidative potential of oil and extracts derived from leaves of Indian spice plant *Cinnamomum tamala*," *Cellular andMolecular Biology*, vol. 58, pp. 142–147, 2012.
- [9] B.Halliwell and J. M. C.Gutteridge, *Free Radicals in Biology and Medicine*, Oxford University Press, Oxford, UK, 1998.
- [10] Dzoyem JP1,2, Melong R3,4, Tsamo AT3 et al "Cytotoxicity, antimicrobial and antioxidant activity of eight compounds isolated from *Entada abyssinica* (Fabaceae)." 2017 Mar 6;10(1):118
- [11] Carballo-Villalobos AI1et al "Pro-inflammatory cytokines involvement in the hesperidin antihyperalgesic effects at peripheral and central levels in a neuropathic pain model" *Inflammopharmacology*. 2017 Mar

- [12] Hyun-Ja Jeong et al. C-Kit Binding Properties of Hesperidin (a Major Component of KMP6) as a Potential Anti-Allergic Agent Plos 2011
- [13] Jung UJ et al. The hypoglycemic effects of hesperidin and naringin are partly mediated by hepatic glucose-regulating enzymes in C57BL/KsJ-db/db mice. J Nutr. 2004
- [14] Kalpana KB et al. Evaluation of antioxidant activity of hesperidin and its protective effect on H₂O₂ induced oxidative damage on pBR322 DNA and RBC cellular membrane. Mol Cell Biochem. 2009
- [15] Gilbert DN. Once-daily aminoglycoside therapy. Antimicrob Agents Chemother 1991;35:399-405.
- [16] Gilbert DN. Once-daily aminoglycoside therapy. Antimicrob Agents Chemother 1991;35:399-405.
- [17] Sternberg SS. Diagnostic Surgical Pathology. 3rd ed. Philadelphia: Lippincott: Williams & Wilkins; 1996. pp. 1701–1785.
- [18] Anu Rahal, Amit Kumar, Vivek Singh, Brijesh Yadav, Ruchi Tiwari, Sandip Chakraborty, and Kuldeep Dhama “Oxidative Stress, Prooxidants, and Antioxidants: The Interplay” BioMed Research International Volume 2014 (2014)
- [19] ying chen, phd, gaurav mehta, mvs, and vasilis vasilou,” Antioxidant Defenses in the Ocular Surface” Ocul Surf. 2009 Oct; 7(4): 176–185.
- [20] 20-Wilmsen PK1, Spada DS, Salvador M.” Antioxidant activity of the flavonoid hesperidin in chemical and biological systems.” J Agric Food Chem. 2005 Jun 15;53(12):4757-61.
- [21] Ahmad S , Alam K , Hossain MM, Fatima M, Firdaus F, Zafeer MF, Arif Z, Ahmed M, Nafees KA. “Anti-arthritis and cardioprotective action of hesperidin and daidzein in collagen-induced rheumatoid arthritis”. Mol Cell Biochem. 2016 Dec;423(1-2):115-127. Epub 2016 Oct 4.
- [22] Rezaeyan A, Fardid R, Haddadi GH, Takhshid MA, Hosseinzadeh M, Najafi M, Salajegheh A. Evaluating Radioprotective Effect of Hesperidin on Acute Radiation Damage in the Lung Tissue of Rats. J Biomed Phys Eng. 2016 Sep 1;6(3):165-174. eCollection 2016 Sep.