

# Research Journal of Pharmaceutical, Biological and Chemical Sciences

## Morphological Variations In Sternocleidomastoid Muscle: A Cadaveric Study From North Indian Population.

Anshu Mishra<sup>1\*</sup>, Parmatma Parsad Mishra<sup>2</sup>, Mohammad Javed Ali Khan<sup>3</sup>,  
Indra Kumar Patel<sup>4</sup>, and Alka Singh<sup>5</sup>.

<sup>1</sup>Associate Professor, Department of Anatomy, Rajarshi Dashrath Autonomous State Medical College, Ayodhya, Uttar Pradesh, India.

<sup>2</sup>Associate Professor, Department of Anatomy, Maharaja Suhel Dev Autonomous State Medical College, Bahraich, Uttar Pradesh, India.

<sup>3</sup>Tutor, Department of Anatomy, Rajarshi Dashrath Autonomous State Medical College, Ayodhya, Uttar Pradesh, India.

<sup>4</sup>Professor and Head, Department of Anatomy, Maharaja Suhel Dev Autonomous State Medical College, Bahraich, Uttar Pradesh, India.

<sup>5</sup>Department of Anatomy, Rajarshi Dashrath Autonomous State Medical College, Ayodhya, Uttar Pradesh, India.

### ABSTRACT

Sternocleidomastoid muscle is an important muscle in neck region which is important for various neck movements, respiratory movements and act as a landmark muscle in the neck. Aim of study present to find out incidence in variation of sternocleidomastoid muscle. The current study was performed during routine undergraduate teaching from 2014 to 2021 at department of anatomy at Integral Institute of Medical Sciences & Research, Lucknow, Rajarshi Dashrath Autonomous State Medical College, Ayodhya and Maharaja Suhel Dev Autonomous State Medical College, Bahraich, on 26 cadavers. While doing the routine cadaveric dissection for undergraduate teaching the sternocleidomastoid muscle was carefully dissected both the sides and any anomalous feature was noted and described in this study. Out of a total of 26 cadavers (52 sides) the variation in the morphology of muscle was found in 3 sides. The variations of sternocleidomastoid muscle were found in 3.8% muscle which is quite significant and needs further studies also.

**Keywords:** Sternocleidomastoid muscle, neck region, additional head, anatomical variations

<https://doi.org/10.33887/rjpbcs/2022.13.4.13>

*\*Corresponding author*

## INTRODUCTION

The sternocleidomastoid is a paired muscle of the neck which acts as key landmark for identifying important structures in neck. This muscle lies obliquely across the side of the neck and divides the side of the neck into anterior and posterior triangles. It originates as two heads, the medial or the sternal head which is tendinous and rounded; and the lateral or the clavicular head [1]. The sternal head originates from the upper part of the anterior surface of the manubrium sternii. The lateral head originates from the superior surface of the medial end of the clavicle. The triangular interval between the two heads of origin forms a surface depression, the lesser supraclavicular fossa [2]. Both head blend in the side of neck and it get inserted on mastoid process and lateral part of superior nuchal line. Its main action is to flex and rotate the head. It is also an accessory muscle of inspiration. The muscle is important for surgical interventions, invasive procedures for blood vessels in neck, preparation of myocutaneous flaps and physiotherapy exercises [3].

Variation of Morphology of SCM is reported by many authors in form of case reports. It is said that SCM shows a wide range of variations especially at its clavicular head of origin and in the layered arrangement of its fibers<sup>1</sup>. The variations at its insertion are very rare [4]. In a review article by T. Hassan eight different types of variations of morphology of SCM were described based on different case reports [5]. Although SCM variations are often encountered during routine neck dissections and surgeries, less literature about them is available. The present study was undertaken during routine dissection to find out the incidence of variation in morphology in SCM.

## MATERIAL AND METHODS

The present study was performed during routine cadaveric dissection for undergraduate teaching at Department of Anatomy Integral Institute of Medical Sciences & Research, Lucknow, Rajarshi Dashrath Autonomous State Medical College, Ayodhya and Maharaja Suhel Dev Autonomous State Medical College, Bahraich, on a total of 26 cadavers (52 sides) from year 2014 to 2021.

While doing the dissection for head and neck region the SCM muscle was carefully exposed bilaterally in its whole extent to observe any associated variation. A cut plate of X-ray film was kept underneath the muscle belly and photograph were taken.

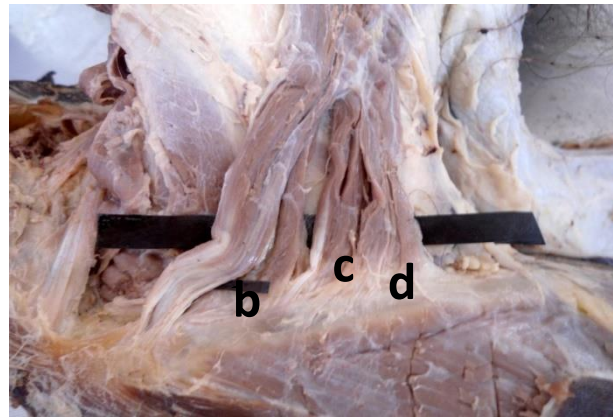
## OBSERVATION AND RESULTS

Out of 52 SCM muscle dissected and studies we found variation in 3.84% (2 n) muscle in their clavicular head of origin. In the first cadaver we found 2 additional bellies for clavicular head which were placed slightly in the deeper plane. The additional bellies were well formed in the lower part of neck but at their clavicular attachment it seemed like a broad aponeurotic origin extending up to the half of clavicle with any clear cut demarcation between the bellies compared that from in lower part of neck. The length of attachment measured was 8.2 cm. Because of this broad clavicular attachment the supraclavicular fossa was found absent figure 1.

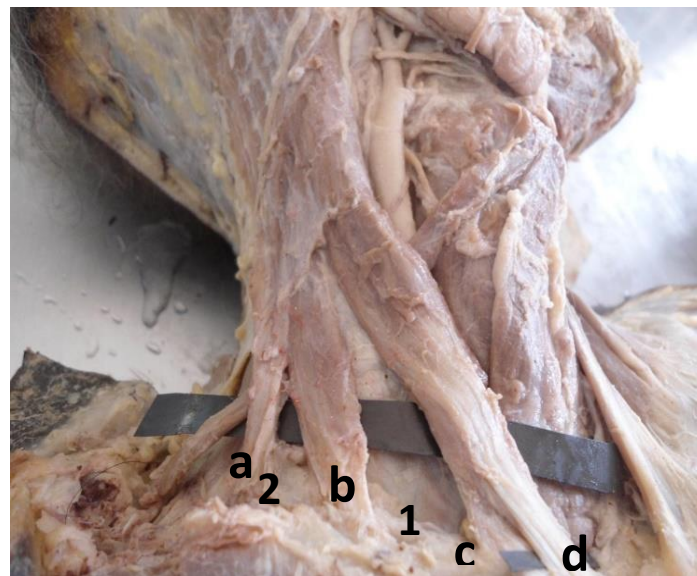
In another cadaver we found 2 additional bellies of clavicular head out of which one belly is present on a deeper plane with sternal head and the other one was separated from clavicular head in form of complete additional belly. Hence in this cadaver there was an additional supraclavicular fossa which was labeled as lesser supraclavicular fossa. The main supraclavicular fossa was 5.5 cm wide and the lesser supraclavicular was 2.4 cm wide. In this case the main supraclavicular fossa was unusually large as the bellies coming from manubrium sternii and clavicle were fused to form single belly quite higher than normal (figure 2). The distance from clavicle to the point of fusion of both clavicular and sternal belly was 7.3 cm. All the additional bellies were supplied by spinal accessory nerve. The findings were tabulated in table 1.

**Table 1: showing type of variation found with their incidence**

No of total SCM muscle studied (52n)	No of SCM muscles with variation (2n) = 3.84%	Muscle with 2 additional bellies with absent supraclavicular fossa	1.92% (1n)
		Muscle with 2 additional bellies with lesser supraclavicular fossa	1.92% (1n)



**Figure 1: A = sternal head of SCM, b, c, d = clavicular head of SCM, Supraclavicular fossa absent**



**Figure 2: a, b, c = clavicular head of SCM, d = sternal head of SCM, 1 = Supraclavicular fossa, 2 = lesser supraclavicular fossa**

**DISCUSSION**

In the present study we found variation in origin of SCM muscle and in but the pattern was very different. In one cadaver there was a broad clavicular belly divided into many slips without gap. Similar cases were previously reported where there was broad clavicular head splitting into multiple small muscular slips [6,2,3]. Coskun et al 2002 reported a case, in which they found sternocleidomastoid and sternomastoid muscle in superficial layer and cleidomastoid muscle in deep layer [6]. Sarikcioglu et al. 2001 observed an unusual muscle deep to sternocleidomastoid and termed it cleido-occipital muscle. As mentioned in the previous literature the clavicular origin could be as broad as 7.5 cm and when it is broad

in origin it could be subdivided into several slips, separated by narrow intervals [7]. In present case we found the clavicular attachment was 8.4 cm wide.

In another cadaver we found two extra clavicular bellies. Similar case with unilateral additional clavicular belly was reported by Rani et al. 2011 [8]. In another case Ramesh et al. 2007 reported bilateral presence of additional clavicular belly [9]. Addition belly of SCM muscle was also reported by Rr et al. 2015, Kaur et al. 2017 and Hernandez et al. 2018 [10-12]. These additional heads can cause significant stenosis of the lesser supraclavicular fossa, imposing complications for anesthesiologists during the anterior central venous catheterization approach. This difficulty during cannulation can accidentally puncture the neighboring neurovascular structures thereby leading to haematoma formation or resulting in neural deficits [13, 14]. Moreover these additional bellies can be utilized as myocutaneous flaps during reconstructive surgeries. Conley et al in 1980 highlighted the importance of the SCM muscle in the reconstruction of the mandible and mandibular defects, as well as in the reconstruction of the oral floor as a myocutaneous flap. Hence it is useful and essential for the surgeons to be aware of possible variations during routine head and neck surgeries and during MR imaging observations of the neck region [15].

In a similar study by Saha et al 2014 they reported morphological variations of SCM in 27.8 % of cadavers [16]. If their results are analyzed in terms of individual muscle (as we analyzed) it comes about 19.4%. This is quite higher than results of present study. In a review article by Silawal et al in 2022, he studies the available case reports in standard journals regarding variation in morphology of SCM, he found out of the total reported subjects, 86.2% presented with a muscular variation in the clavicular side of the SCM proximal head whereas 27.6% in the sternal side. Similar to his results we also found all variations in clavicular head of origin [17].

Variations in anatomical structures are a common finding during cadaveric dissection, surgeries and radiological examination. Variations of SCM muscle are also frequently found and reported in literatures. Embryological development can give a clue about these variations. The sternocleidomastoid and trapezius develop from a common pre-muscle mass from last two occipital and upper cervical myotomes. Later this mass split to develop in different structures. A segment of this mass grows with upper limb bud and develop in sternocleidomastoid muscle. The additional muscle slips indicate abnormal mesodermal splitting at this stage of development [18-20].

### CONCLUSION

We conclude that in our study we found morphological variation in about 3.8 % of total SCM muscle studied. There are many case reports regarding this but organized studies are few. Hence further studies are needed to verify this data. The incidence of these variations is a must know and very useful for surgeons, anesthetists and intervention radiologists while dealing with this area.

### Abbreviations:

SCM = Sternocleidomastoid muscle

### REFERENCES

- [1] Bergman R, Thompson SA, Afifi AK, Saadeh FA (1988). Compendium of human anatomical variation. Baltimore, Urban & Schwarzenberg 32-33, 40-41.
- [2] Boaro SN, Frago, Neto RA. Int J Morphol 2003; 21: 261-264
- [3] Cherian SJ, Nayak S. Int J Morphol 2008;26(1):99-101
- [4] Sabastian P, Cherian T, Ahmed M I, Jayakumar K L, Shivramkrishnan P. Arch Otolaryngol Head Neck Surg 1994;120(6):629-632.
- [5] T Hasan. The Internet Journal of Human Anatomy 2011;1(1).
- [6] Nayak SR, Krishnamurthy A, S, J, MK, Pai MM, Prabhu LV, Jetti R. Morphologie 2006;90:203-204
- [7] Schafer ES, Symington J, Bryce TH. Quain's Elements of Anatomy. 11th Ed., New York, Longman's Green and Co. 1923; 67-70.
- [8] Ramesh RT, Mvishnumaya G, Prakashchandra SK, Suresh R. Int J Morphol 2007; 25:621-623
- [9] Rani A, Srivastava A K, Rani A, Chopra J. Int J Anat Var 2011; 4: 204-206.
- [10] Rr, F, Reddy A, Sch J Med Case Rep 2015. 3(9B): p. 865-867.



- [11] Hernandez LVT, Rodriguez IAT, Arquez HF. International Journal of Pharmaceutical Research 2018;11(1)1136-1139.
- [12] Kaur A, A Sharma, and M Sharma. North States J Anat 2017;2(2):25-28.
- [13] Mehta V, Arora J, Kumar A, Nayar AK, Ioh HK, Gupta V et al. Anat Cell Biol 2012;45: 66-9.
- [14] Pushpa MS, Nandhini V. International Journal of Recent Scientific Research 2014; 5(1): 5-7.
- [15] Conley J, Gullane PJ. Head Neck Surgery 1980;2:308-11.
- [16] Saha A, Mandal S, Chakraborty S, and Bandyopadhyay M. Singapore Med J 2014; 55(1), 45-47. <https://doi.org/10.11622/smedj.2013215>
- [17] Silawal S, Schulze-Tanzil G. Folia Morphologica 2022.
- [18] Sarikcioglu L, Donmez BO, Ozkan O. Folia Morphol (Warsz) 2001;60: 347-349.
- [19] Karandikar PM, Tayade MC, Kunkolol R. Pravara Medical Review 2020;12(1):40-44.
- [20] Coskun N, Yildirim FB, Ozkan O. Folia Morphol (Warsz) 2002; 61: 317-319.