

Research Journal of Pharmaceutical, Biological and Chemical Sciences

A Cross Sectional Study On Functional And Radiological Outcome Of Tibiotalocalcaneal Nailing In Ankle Arthrodesis.

S Eswarapandi^{1*}, G Balasubramanian², and S Pandi Prakasah³.

^{1,2}Assistant Professor, Department Of Orthopedics, Government Tirunelveli Medical College, Tirunelveli, Tamil Nadu, India.

³Assistant Surgeon, Department Of Orthopedics, Government Head Quarters Hospital, Kovil Patti, Tamil Nadu, India.

ABSTRACT

Tibiotalocalcaneal arthrodesis or hindfoot fusion is a salvage surgical option used to treat symptomatic or severe deformity as a result of Charcot's arthropathy. It is an internal fixation that utilizes nails to stabilize the hindfoot after surgical correction of the deformity. Functional and Radiological outcomes of Tibiotalocalcaneal Nailing in ankle arthrodesis" in cases admitted and followed up in the Department of Orthopedics, Tirunelveli Medical College Hospital, over period of 2 years. The demographic characteristics and past medical history of the patients were collected and analyzed to identify the cause of the pathology. The degree of OA and deformity were quantified based on foot and ankle weight-bearing radiography and CT examination. Pre- and post-operative clinical and functional scores (ROM, VAS, AOFAS, FFI, and SF-36) and radiographic parameters (anterior distal tibial angle, tibiotalar angle, coronal tibiotalar angle, and hindfoot alignment angle) were evaluated. All of the patients showed clinical and radiographic fusion at an average of 14 weeks (Range 12–48), with improvement in pain and functional scores, without major surgical complications and/or infections. Despite the limitations of our study, the results with this new plating system showed good results in terms of bone consolidation, post-operative complications, and improvement of pain and quality of life in patients with severe OA and deformities of the ankle and hindfoot.

Keywords: Hindfoot Arthrodesis Nail, Charcot's Arthropathy, Functional Outcome, Orthopedics, Foot And Ankle.

<https://doi.org/10.33887/rjpbcs/2023.14.6.58>

**Corresponding author*

INTRODUCTION

The ankle joint is a hinge variety of joint. It consists of three bones that articulate with each other: the distal tibia, distal fibula, and talus [1]. The lateral talar dome has a wider circumference than the medial talar dome. The anterior dome is larger than the posterior dome. With dorsiflexion of the ankle, the syndesmotric ligaments allow the ankle joint to broaden into a stable, close-packed configuration. During walking, the axis of rotation in the ankle joint changes continuously, although keeping it in a neutral position does not result in any major biomechanical faults in the limb [2]. Tibial plafond, medial malleolus, and lateral malleolus all covers the talus, providing favorable bone surfaces for union in arthrodesis. Arthrodesis is derived from the Latin words "arthron" which means "joint" and "Desis" which means "binding." Ankle Arthrodesis is a surgical treatment that converts an arthritic, painful ankle joint into a painless, immobile, stable bone segment [3]. Ankle Arthrodesis has been proven to be an effective procedure for pain alleviation and maintaining plantigrade foot function for severe ankle arthritis and it represents more than 85 percent of ankle surgeries [4]. Cross screw, external fixation, retrograde intramedullary nailing, and plating are some of the types of ankle arthrodesis fixation procedures. Ankle arthrodesis results in a well-aligned, stable ankle joint with the foot at a 90-degree angle to the leg. A well-placed ankle fusion is beneficial in reducing discomfort, correcting deformity, and restoring function to the limb [5]. The talus and calcaneum forms the subtalar joint, which has a limited range of motion. Subtalar arthritis is caused by post-traumatic and calcaneal fractures, and it makes walking more painful. Both the ankle and the subtalar joints are fused if both affected. All cartilages are denuded while doing intra articular arthrodesis, healing achieved by primary healing between opposed cancellous surfaces [6].

MATERIALS AND METHOD

This Cross-sectional study was done in Department of Orthopaedics, Tirunelveli medical college Hospital with 20 patients of patients with ankle and subtalar arthritis in the year 2021. Lateral Trans fibular osteotomy approach was used. Methods of Fusion is Retrograde intramedullary tibiotalar calcaneal (TTC) nailing. Radiographs of Ankle both Antero-posterior, lateral and Mortise views taken. The American Orthopaedic Foot and Ankle Society (AOFAS) is used for Functional evaluation.

Inclusion Criteria

- Age 15-75 yrs
- Post traumatic Arthritis.
- Osteoarthritis
- Arthritis with chronic instability
- Rheumatoid or autoimmune Inflammatory arthritis
- Gouty arthritis
- Osteonecrosis of Talus.
- Post Infective Sequelae of Ankle and subtalar joint
- Ankle instability from neuromuscular Deformities.
- Failure of total ankle arthroplasty
- Charcot's Arthropathy

Exclusion Criteria

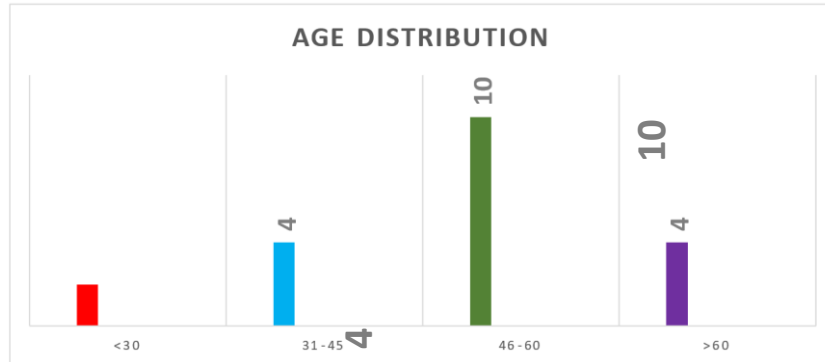
- Age less than 15 and more than 75
- Uncontrolled Diabetes Mellitus.
- Active infection
- Dysvascular limb.
- Patients with mental and neurogenic conditions
- Foreign body sensitivity.

RESULTS

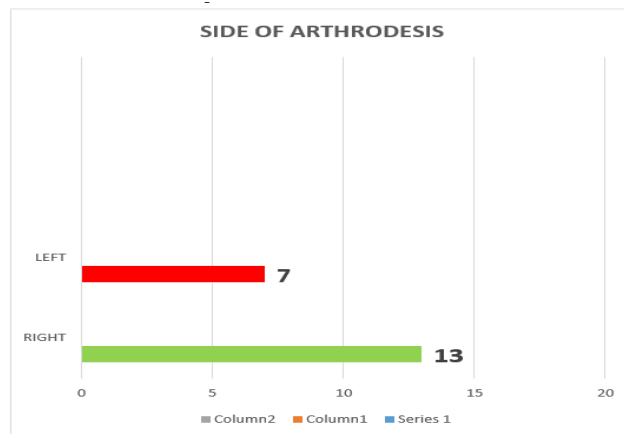
The observations and results from our study as follows. The Common Age Group who presents in this study belong to 46- 60yrs (50%) followed by 31-45yrs (20%). Ankle Arthritis predominant in male (70%) compared to female (30%). Patients in our study have arthritis predominant in right side (65%)

compared to left side (35%). The most common cause in our study was post traumatic arthritis (85%) followed by Charcot's Arthropathy (10%),pseudoarthrosis tibia 5%.Out of 20 patients fusion achieved in 18 patients. Nonunion noted in 2 patients. Time taken for fusion in most patients are 4 months (50%) followed by 6 months (38.88%) followed by 8 months (11.11%). The outcome analysis was based on AOFAS score. AOFAS (American Orthopaedic Foot and Ankle Score)-outcome score shows 3 patient showed excellent result, 8 patient showed good result, 7 showed fair results, 2 poor results. Preoperative mean AOFAS score was 23.85 which was improved to mean score of 76.7 which was considered as good .

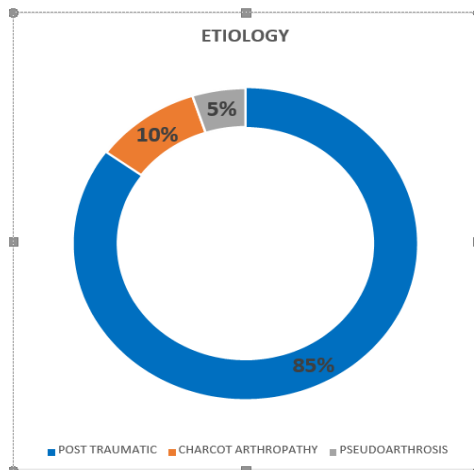
Graph 1: Age Distribution



Graph 2: Side Of Arthrodesis

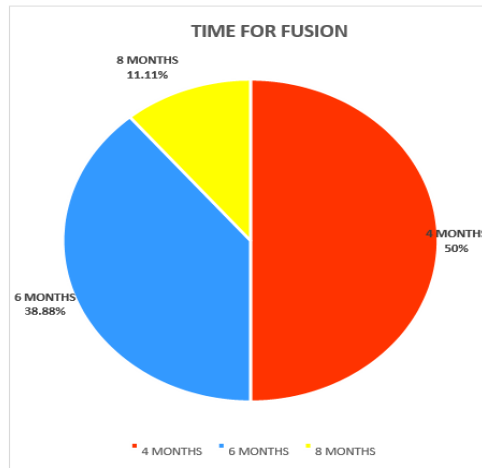


Graph 3: Etiology For Arthritis



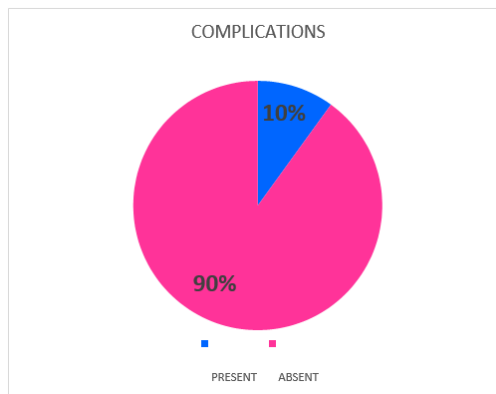
Post traumatic being the most common causes in our study group

Graph 4: Time Taken For Fusion



Most common time period required for fusion - 4 months. Mean time period require for fusion – 4.9 months.

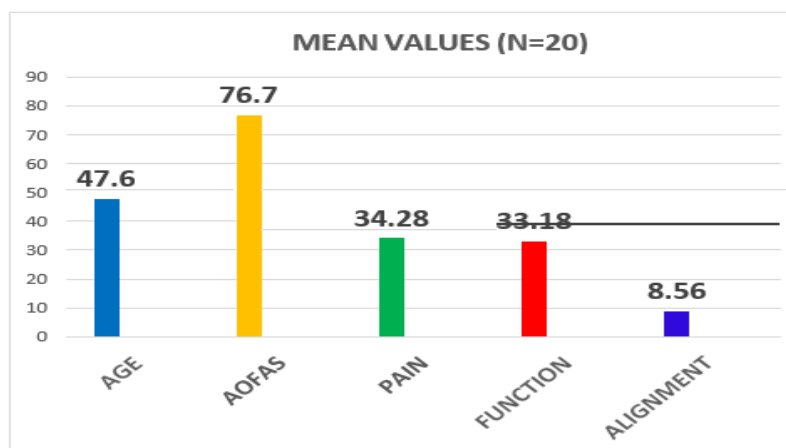
Graph 5: Complications



Only 10 % of our study group had complication

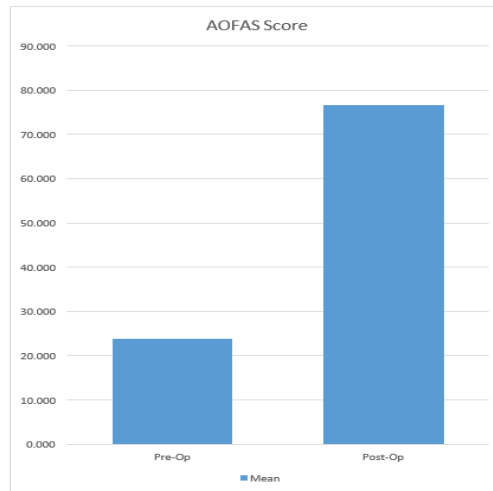
- Infection
- Non union
- Implant loosening.

Graph 6: General Characteristics



AOFAS SCORES: Excellent – 3 people, Good-8 people, Fair- 7 people, Poor- 2 people

Graph 7: Pre OP Vs Post OP AOFAS Scores



Pre op score of 23.85 was increased to 76.7.

DISCUSSION

Tibiotalocalcaneal arthrodesis with retrograde intramedullary nailing has high advantage of both high biomechanical stability and soft tissue preservation. Post-traumatic arthritis was the most prevalent condition for ankle arthrodesis in our sample of 20 individuals. The most prevalent rationale for ankle fusion, according to Lisa M Coester et al's research of long-term outcomes following ankle arthrodesis, is post-traumatic arthritis [7]. The secondary arthritis is caused by compensatory hypermobility at minor joints, according to gait analysis of tibio-talo-calcaneal arthrodesis for concomitant subtalar arthritis and ankle arthrodesis (tibio-talar) [8]. Tibiotalocalcaneal arthrodesis by intramedullary nailing and external fixation in patients with Charcot's arthropathy, concluding that the need for revision surgery was more common in the retrograde intramedullary group; the same results happened in our study, with two patients requiring revision surgery [9]. The biomechanical comparison of intramedullary nail and crossed lag screw fixation for tibiotalocalcaneal arthrodesis, concluding that intramedullary nailing is biomechanically stiffer than crossed lag screws in all bending and torsional forces, and it helps in maintaining hindfoot alignment during union and increases fusion rate through increased internal fixation stability. There is enough data in the literature to show that individuals with Charcot's neuropathy, postinfectious arthrodesis, and smokers have a greater incidence of nonunion [10]. Two of the patients in our research had Charcot's arthropathy, with two requiring revision surgery owing to non-union, implant loosening due to infection and poor bone quality [11]. We noted a trend of small studies reporting better union rates compared to the large studies. When the results were analysed on the basis of joints available at final appointment (641) we found a union rate of 86.7%. However, revision arthrodesis is not required in asymptomatic cases of non-union [12]. In this systematic review, among the 85 cases with non-union only 26% required a revision arthrodesis. The remaining cases were either asymptomatic or the symptoms were not severe enough to require revision arthrodesis. This indicates that the im nail, to some extent, maintains the alignment and provides stability to help with symptoms even without bony union. It has been argued that the anteroposterior direction is better for insertion of distal locking screws. It gives good bony purchase and prevents any movement in the sagittal plane [13]. Intermediate term complications could be defined as those occurring between the first six months to a year after the fusion [14]. During this period the fusion is consolidated into a bony construct, allowing the patients progressively increase their weight bearing status, and thereby letting them to return to their activities [15]. Malunions due to malpositioning and nonunion are the two major complications during this period. Other minor complications during this period include chronic edema, stress fractures and calluses. The ideal position in which the ankle is fused has changed over time [16]. Previously the ankle was fused in a more equinus position to allow patients to wear shoes with heels. This has been discontinued, as gait studies demonstrated a vaulting gait pattern with a recurvatum thrust at the knee [17]. The current accepted position for fusion involves the ankle being held in neutral dorsiflexion / plantar flexion, 50 of

valgus, 50 to 100 of external rotation and slightly posteriorly displaced talus relative to the tibia [18]. Posterior placement of the talus under the tibia has been described to reduce the anterior lever arm of the foot under the arthrodesis. While anterior placement, which can cause difficulties with the foot clearing the ground during swing phase of the gait, should be avoided, the theoretical advantage of posterior placement has not proved to be clinically relevant [19, 20]

CONCLUSION

With the above results it can be seen that, retrograde intramedullary tibiototalcalcaneal nail fixation is the very good method of arthrodesis which provides best result in terms of function and union. It provides high biomechanical stability with soft tissues preservation, which plate fixation lacks. Though cancellous screw fixation also equally effective, it cannot give rigid intramedullary fixation and correct patient selection is needed. The External fixator though used for the patient and requires prolonged time for fusion and it is useful in compound fractures with bone loss. Mean age at arthrodesis was 47.6 years. The mean AOFAS score increased from 23.85 to 76.7. Mean fusion time was 4.97 months. Ankle arthrodesis is a reliable method for post traumatic arthritis that provide good outcome to the patient and painless stable plantigrade foot. In patients with Charcot arthropathy the results were not good and increased rate of infection, nonunion, decreased wound healing and high chances of implant failure. Longer period of follow up is recommended since functional outcomes may improve after years.

REFERENCES

- [1] Adams JC. Arthrodesis of the ankle joint ; experiences with the transfibular approach. J Bone Joint Surg 1948 ; 30-B : 506-511.
- [2] Alvarez RG, Barbour TM, Perkins TD. Tibiocalcaneal arthrodesis for nonbraceable neuropathic ankle deformity. Foot Ankle Int 1994 ; 15 : 354-359.
- [3] Anderson T, Linder L, Rydholm U et al. Tibio- talocalcaneal arthrodesis as a primary procedure using a retrograde intramedullary nail : a retrospective study of 26 patients with rheumatoid arthritis. Acta Orthop 2005 ; 76 : 580-587.
- [4] Berend ME, Glisson RR, Nunley JA. A biomechanical comparison of intramedullary nail and crossed lag screw fixation for tibiototalcalcaneal arthrodesis. Foot Ankle Int 1997 ; 18 : 639-643.
- [5] Bevernage BD, Deleu PA, Maldague P, Leemrijse T. Technique and early experience with posterior arthroscopic tibiototalcalcaneal arthrodesis. Orthop Traumatol Surg Res 2010 ; 96 : 469-475.
- [6] Boer R, Mader K, Pennig D, Verheyen CC. Tibiototalcalcaneal arthrodesis using a reamed retrograde locking nail. Clin Orthop Relat Res 2007 ; 463 : 151-156.
- [7] Budnar VM, Hepple S, Harries WG, Livingstone JA, Winson I. Tibiototalcalcaneal arthrodesis with a curved, interlocking, intramedullary nail. Foot Ankle Int 2010 ; 31 : 1085-1092.
- [8] Caravaggi C, Cimmino M, Caruso S, Dalla Noce S. intramedullary compressive nail fixation for the treatment of severe Charcot deformity of the ankle and rear foot. J Foot Ankle Surg. 2006 ; 45 : 20-24.
- [9] Charnley J. Compression arthrodesis of the ankle and shoulder. J Bone Joint Surg 1951 ; 33-B : 180-191.
- [10] Dalla Paola L, Volpe A, Varotto D et al. Use of a retrograde nail for ankle arthrodesis in Charcot neuroarthropathy : a limb salvage procedure. Foot Ankle Int 2007; 28: 967-970.
- [11] De Smet K, De Brauwier V, Burssens P, Van Oost E, Verdonk R. Tibiocalcaneal Marchetti-Vicenzi nailing in revision arthrodesis for posttraumatic pseudarthrosis of the ankle. Acta Orthop Belg 2003 ; 69 : 42-48.
- [12] Dereymaeker GP, Van Eygen P, Driesen R, De Ferm A. Tibiotalar arthrodesis in the rheumatoid foot. Clin Orthop Relat Res 1998; 349 : 43-47.
- [13] Fazal MA, Garrido E, Williams RL. Tibio-talo-calcaneal arthrodesis by retrograde intramedullary nail and bone grafting Foot Ankle Surgery 2006 ; 12 : 185-190.
- [14] Fleming SS, Moore TJ, Hutton WC. Biomechanical analysis of hindfoot fixation using an intramedullary rod. J South Orthop Assoc 1998 ; 7 : 19-26.
- [15] Fox IM, Shapero C, Kennedy A. Tibiototalcalcaneal arthrodesis with intramedullary interlocking nail fixation. Clinics in Podiatric Medicine and Surgery 2000 ; 17 : 19- 31.
- [16] Fujimori J, Yoshino S, Koiwa M et al. Ankle arthrodesis in rheumatoid arthritis using an intramedullary nail with fins. Foot Ankle Int 1999 ; 20 : 485-490.
- [17] Gavaskar AS, Chowdary N. Tibiototalcalcaneal arthro - desis using a supracondylar femoral nail



- for advanced tuberculous arthritis of the ankle. *J Orthop Surg (Hong Kong)* 2009 ; 17 : 321-324.
- [18] Giza E, Sarcon AK, Kreulen C. Tibiotalar nonunion corrected by hindfoot arthrodesis. *Foot Ankle Spec* 2010 ; 3 : 76-9. Epub 2010 Feb 16.
- [19] Goebel M, Gerdesmeyer L, Mückley T et al. Retrograde intramedullary nailing in tibiototalcalcaneal arthrodesis: a short-term, prospective study. *J Foot Ankle Surg* 2006; 45 : 98-106
- [20] Haaker R, Kohja EY, Wojciechowski M, Gruber G. Tibio-talo-calcaneal arthrodesis by a retrograde intra - medullary nail. *Ortopedia, traumatologia, rehabilitacja* 2010; 12 : 245-249.