

Research Journal of Pharmaceutical, Biological and Chemical Sciences

Anti-hepatotoxic activity of polyherbal formulation in carbon tetrachloride induced toxicity in rats

CS Kandasamy^{1*}, Shimna Thasnim PS¹, Mohammed Basil E¹
P Arul Raj¹, V Gopal², R Venkatnarayanan¹

¹Department of Pharmacognosy, R.V.S College of Pharmaceutical Sciences, Sulur, Coimbatore.

²Department of Pharmacognosy, College of Pharmacy, Mother Theresa Institute of Health Sciences, Pondicherry.

ABSTRACT

A polyherbal formulation is investigated for hepatoprotective activity against carbon tetrachloride induced hepatic damage in female albino Wister rats. The hepatoprotective activity of polyherbal formulation is compared with the standard drug Liv-52. The polyherbal formulation has shown significant hepatoprotective activity by reducing the elevated levels of serum enzymes such as serum glutamate oxaloacetate transaminase (SGOT) to 86.96 IU/L, serum glutamate pyruvate transaminase (SGPT) to 47.62 IU/L, alkaline phosphate (ALP) to 446 IU/L, Bilirubin level to 0.57 mg/dl and significant increase in total protein and albumin 9.5 g/dl and 7.74 g/dl respectively when compared to the standard drug Liv-52 which decreased SGOT to 89.40 IU/L, SGPT to 49.49 IU/L, ALP to 509 IU/L, Bilirubin level to 0.57 mg/dl and increased total protein and albumin levels to 9.5 gm/dl and 7.14 gm/dl respectively against carbon tetrachloride intoxicated rats in comparison to normal control. These biochemical observations were also supplemented by histopathological examinations of the liver sections. The results showed that polyherbal formulation was most active.

Keywords: Hepatoprotective activity, Liv-52, Carbon tetrachloride.

*Corresponding author

E.mail: cskjss_98@yahoo.co.in



INTRODUCTION

Liver is the largest gland in human body, which weighs between 1 and 2.3 kg. It plays an important role in detoxification and excretion of various exogenous and endogenous compounds. Continuous exposure to various xenobiotics, therapeutic agents and environmental pollutants leads to various disorders such as liver cirrhosis, viral hepatitis, hepatoses and drug induced liver damage [1]. General deterioration of health so often encountered in liver disease cannot be explained by the failure of a single hepatic cell function. Associated disease, such as carcinoma or nutritional deficits, such as in chronic alcoholism may be of more importance in the production of the patient's symptoms than is the liver disease itself. Drugs available in modern medicines bring only symptomatic relief in most of the cases, and are associated with risks of relapses and danger of side effects. Thus a concerted effort to explore the plant resources is extremely important in search of new remedies.

Carbon tetrachloride (CCl_4) is used to study hepatotoxic potential because it is life threatening when an entire liver or most of the liver is exposed to carbon tetrachloride; this requires metabolic activation, particularly by liver cytochrome P-450 enzyme, to form reactive toxic metabolites that in turn causes liver injury in experimental humans and animals [2]. Hepatotoxicity by CCl_4 is connected with the severe impairment of cell protection mechanism. The location of liver is defined mainly by the metabolism of CCl_4 which is cytochrome P-450. Free radicals initiates the process of lipid peroxidation which inhibits the enzyme activity [3, 4]. LIV-52 is an indigenous multiherbal hepatotonic that has been widely used as a hepatoprotective in various liver disorders. The present study was conducted to compare the hepatoprotective action of marketed formulation with the formulated polyherbal formulation against carbon tetrachloride induced acute hepatitis in rats.

MATERIALS AND METHODS

Experimental animals

24 inbred adult albino female rats from Wistar strain, initially 120gm-200gm was obtained from R.V.S.College of Pharmaceutical sciences, Animal house, Coimbatore, India. The animal room was well ventilated and the animals had 12 ± 1 hour night schedule, throughout the experimental period. The animals were housed in large spacious hygienic cages and they were given food and water during the course of experiment with temperature between 25-27°C.

Drugs and chemicals

Medicinal plants such as clove, cardomom, ajowan, nutmeg, cumin etc were purchased along with standard drug LIV-52. All other chemicals used in this study were of analytical grade.

Experimental protocol

The animals were randomized and divided into four groups of six animals each.

Group 1 (Control): Normal control which received 10 ml/kg body weight of water as vehicle once a day orally for three days.

Group 2 (Toxicant Control): Hepatotoxicity was induced by single dose of 25% carbon tetrachloride 2 ml/kg and paraffin oil in 1:1 ratio; intraperitoneally.

Group 3 (LIV-52 treated group): Hepatotoxicity induced animals (as in group 2) were treated with LIV-52 1ml/kg for 3 times / day for three days orally.

Group 4 (Test formulation treated group): Hepatotoxicity induced animals (as in group 2) were treated with test formulation 1ml/kg for 3 times / day for three days orally.

Biochemical analysis

At the end of the experimental period, blood samples were collected by sinus orbital puncture using sterilized capillary tube, cardiac puncture and the serum was used for the assay of hepatic master enzymes viz.

1. Serum Glutamate Oxaloacetate transaminase.
2. Serum Glutamate Pyruvate transaminase.
3. Serum Alkaline Phosphate.
4. Total Bilirubin.
5. Total Protein.
6. Albumin.

Histopathological examination

The rats were sacrificed and the liver was removed, washed in saline and fixed in 10% formalin solution [5]. Small pieces of liver were processed and embedded in paraffin wax sections made were about 4 - 6 micrometers in thickness. They were stained with hematoxylin and eosin (H&E) and observed under microscope for histopathological studies and photographed.

Statistical analysis

With the help of PSTAT software, statistical evaluation was carried out using one-way analysis of variance (ANOVA) and F-ratio was computed to detect the significant changes between the groups. The unpaired students 't' test was used to compare group I with Group II, Group III and Group IV to find the significant chances of the individual groups. For comparison with the control group and carbon tetrachloride treated group, $P < 0.001$ was considered as significant value.

RESULTS & DISCUSSION

The results of carbon tetrachloride induced hepatotoxicity are shown in Table. Carbon tetrachloride intoxication in normal rats significantly elevated the serum levels of SGOT, SGPT, ALP, Total Bilirubin (total and direct), whereas there was a significant decrease in level of total proteins and albumins that indicated acute hepatocellular damage and biliary obstruction. In the histopathological examination of liver sections of control group (Figure 1), Centrilobular and architectural intactness without any apparent damage like fatty metamorphosis, necrosis and fatty infiltration. In the carbon tetrachloride intoxicated group (Figure 2), damages to the architectural intactness characterized by the presence of hepatocyte nuclei, fatty metamorphosis, oedema & biliary pigments were observed. In the histopathological profile of Liv-52 treated groups (Figure 3), there was no evidence of fatty metamorphosis, nor any oedema or necrosis. In the groups treated with the polyherbal formulation RVSPHF567 (Figure 4), revealed the restoration of normal structural and architectural intactness, no evidence of necrosis detectable. This formulation was able to control this necrotic change that was comparable to that of Liv-52 treated group. Thus, the biochemical observations correlate well with the histopathology results of the liver samples.

Biochemical analysis and histopathological studies revealed that in animals of group 2, carbon tetrachloride caused prominent centrilobular fatty change with prominent and enlarged central vein. There was a significant periportal inflammation. Necrosis was also observed indicating liver damage and inflammation of hepatocytes. Recoveries of hepatocytes were seen in sections of liver treated with LIV-52 but there was a

TABLE 1: Measurement of biochemical parameters of prepared polyherbal formulation and compared with standard drug

S. No.	TREATMENT	SGOT (IU/L)	SGPT (IU/L)	ALP (IU/L)	BILIRUBIN (IU/L)	TOTAL PROTEIN (g/dl)	ALBUMIN (g/dl)
1	Control (10ml/kg Distilled water)	81.28 ± 3.22	45.36 ± 2.45	424 ± 7.03	0.41 ± 0.05	9.7 ± 0.78	8.34 ± 0.36
2	Carbon Tetrachloride (2ml/kg)	380.06 ± 7.14 a	226.80 ± 2.92 a	975 ± 14.9 a	1.96 ± 0.23 a	5.4 ± 0.52 a	3.24 ± 1.16 a
3	Carbon Tetrachloride (2ml/kg) + LIV 52 (2ml/kg)	89.40 ± 3.33 a	49.89 ± 3.65 a	509 ± 6.15b	0.74 ± 0.20 b	8.3 ± 0.41 b	5.64 ± 0.23 b
4	Carbon Tetrachloride (2ml/kg) + Polyherbal formulation (2ml/kg)	86.96 ± 6.72c	47.62 ± 3.12 c	446 ± 8.92 c	0.57 ± 0.10 c	9.5 ± 0.46 c	7.74 ± 0.51 c
5	ONEWAY ANOVA	F= < 637.25 df = 23 p < 0.01	F= < 20.46 df = 23 p < 0.01	F= < 981.25 df = 23 p < 0.01	F= < 885.84 df = 23 p < 0.01	F= < 17.59 df = 23 p < 0.01	F= < 22.58 df = 23 p < 0.01

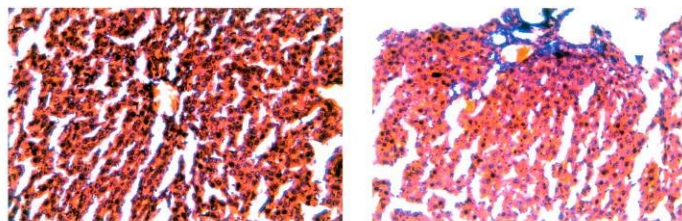
Values are mean ± SEM; n=6

ap < 0.001 in comparison with control

bp < 0.001 in comparison with carbon tetrachloride (2 ml/ kg)

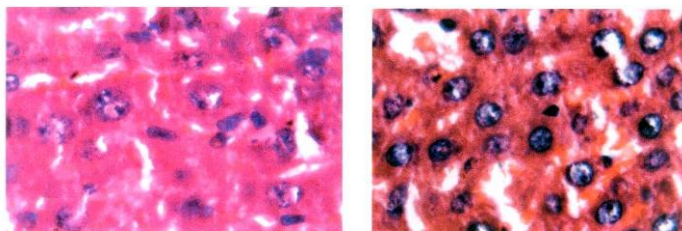
cp < 0.001 in comparison with carbon tetrachloride (2 ml/ kg)

Figure-1



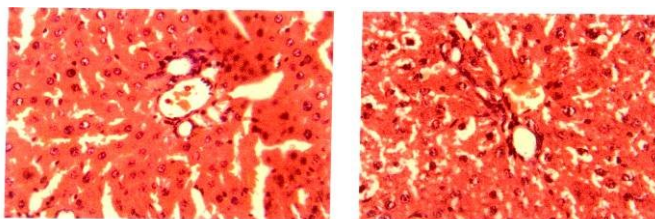
Group:1- Normal control

Figure-2



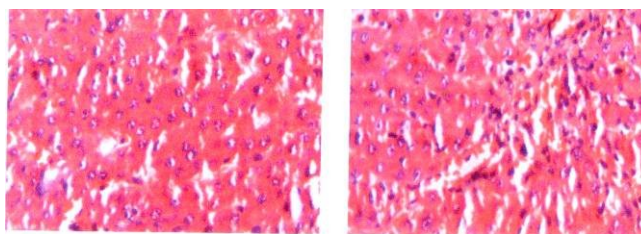
Group:2-Carbon tetra chloride induced group

Figure-3



Group:3-LIV-52 treated group

Figure-4



Group:4-Poly herbal formulation treated

significant recovery shown by the liver sections treated with the Polyherbal formulation. Central vein appeared clearly with disappearance of necrosis there by indicating a potent anti hepatotoxic activity. The histopathological studies also revealed that the rats treated with Polyherbal formulation had almost normal architecture of hepatocytes indicating significant recovery as compared to standard drug LIV-52.

The increase in the level of serum transaminase reflects the liver damage [6] as these enzymes are released in the blood circulation after the administration of hepatotoxin ie carbon tetrachloride [7]. The toxicity is initiated by formation of a reactive metabolite trichlormethyl radical by microsomal fixed function oxidase (MFO). The biotransformation is catalysed by a cytochrome p-450 dependent monooxygenase [8]. The activated trichlormethyl radical binds covalently to the macromolecules and induces peroxidative degradation of membrane lipids resulting in hepatotoxicity and subsequent increase in serum transaminase [9]. On the basis of above results it may be inferred that the Polyherbal formulation exhibited significant anti hepatotoxic activity as compared to standard drug LIV-52.

CONCLUSION

Overall, the results of the present study indicate that Liv-52 and Polyherbal formulation demonstrated a significant hepatoprotective activity against carbon tetrachloride- induced hepatotoxicity in rats. Moreover, Liv-52 and Polyherbal formulation has shown significant comparable hepatoprotective activity.

REFERENCES

- [1] Ravinder K, et al. *Ind J Expt Biol.* 1994; 32: 328-32.
- [2] Kirchain R. William, Montymery A. Pataricia, Drug induced liver disease in; *Pharmacotherapy a Pathophysiologic approach* by Dipiro t. Joseph; Talbert L. Robert; Yee C. Gary; et. al. Aspleton & Lange stamford, connecticut, USA, 1997 4, 628 – 637.
- [3] Gonzalez FJ.. *Pharmacol Rev* 1988; 40: 243 - 88.
- [4] Mac Cay PB, Lai EK, Poyer JL. *J Biol Chem* 1984; 259 : 2135-43
- [5] Luna LG, In *Manual of Histology, Staining methods of Armed Forces Institute of Pathology.* 3rd Edn. Mc Graw-Hill Book Co. New York, 1986, P-146.
- [6] Schmidt E, et al. Liver morphology and enzyme release further studies in the isolated perfused rat liver. In: Keppler, D. (Edn.), *Pathogenesis and Mechanism of liver cell necrosis.* Medical and Technical, Lancaster, 1975; P-47.
- [7] Sallie R, et al. *Drugs and the liver biopharmaceutical drug disposition* 1991; 12: 251-59.
- [8] Dhuley JN, et al. *J Ethnopharmacol* 1997; 56:159-64.
- [9] Cheesmen KH, *Environmental Health Perspect* 1935; 64: 85-101.

ACKNOWLEDGEMENT

The authors are thankful to Micro Labs, Coimbatore, Tamil Nadu, India for carrying out histopathological examinations and providing the concluding remarks.